



**Mark Bernstein, MD, FASER**

Past President, American Society of Emergency Radiology  
Professor of Radiology, Boston University School of Medicine  
Trauma & Emergency Radiology  
Boston Medical Center

***Easily Missed***

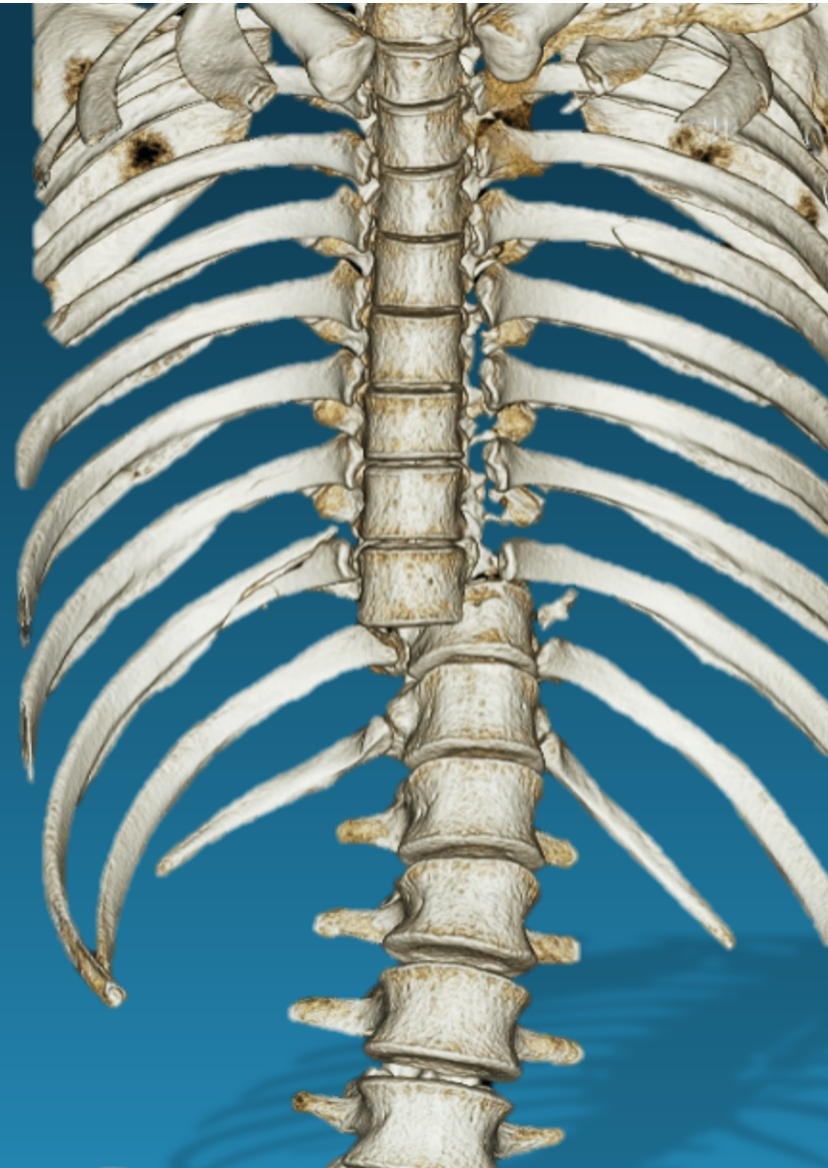
***Thoracolumbar Spine Injuries***



# TL-SPINE TRAUMA

## Outline

- Anatomy
- Stability concepts
- Imaging
- Injury Patterns



# T/L SPINE ANATOMY



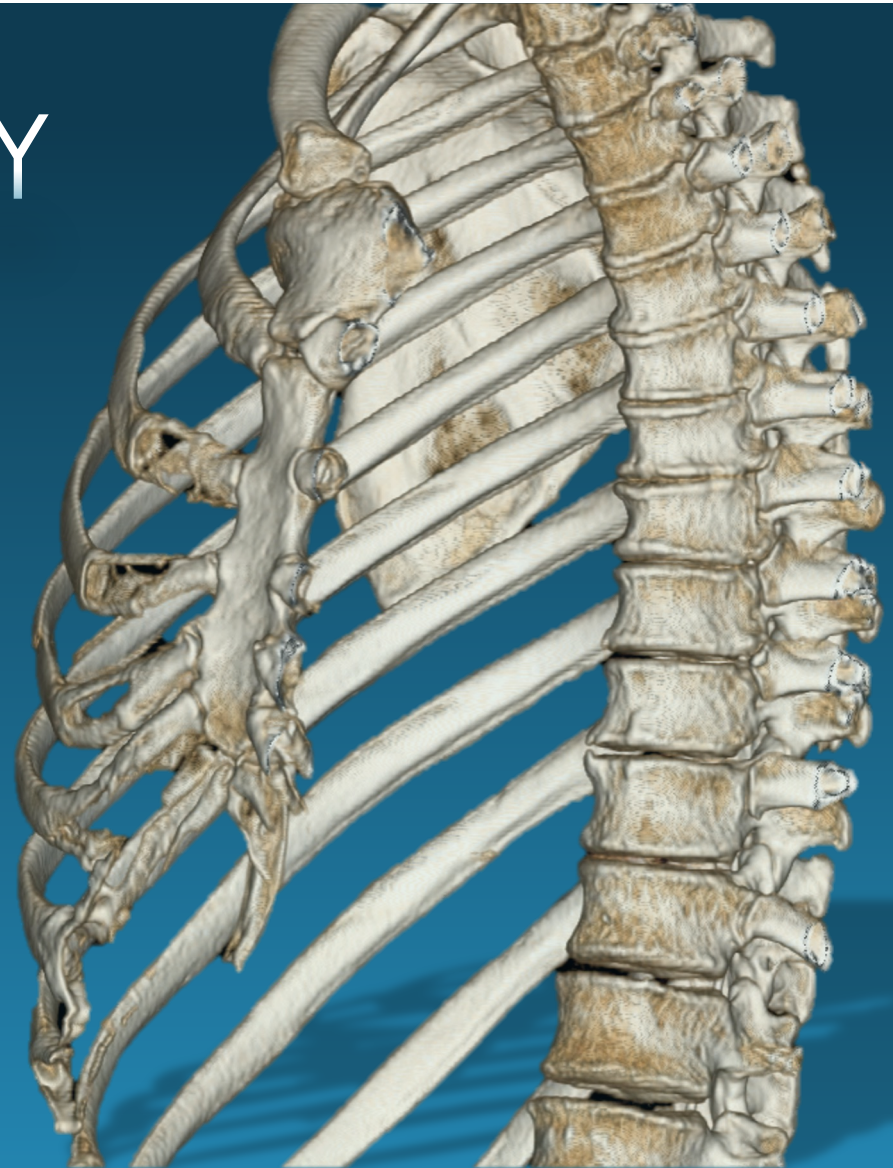
# T-SPINE ANATOMY

## Thoracic Spine

- 12 vertebrae, all with rib articulations

## Thoracic Segment

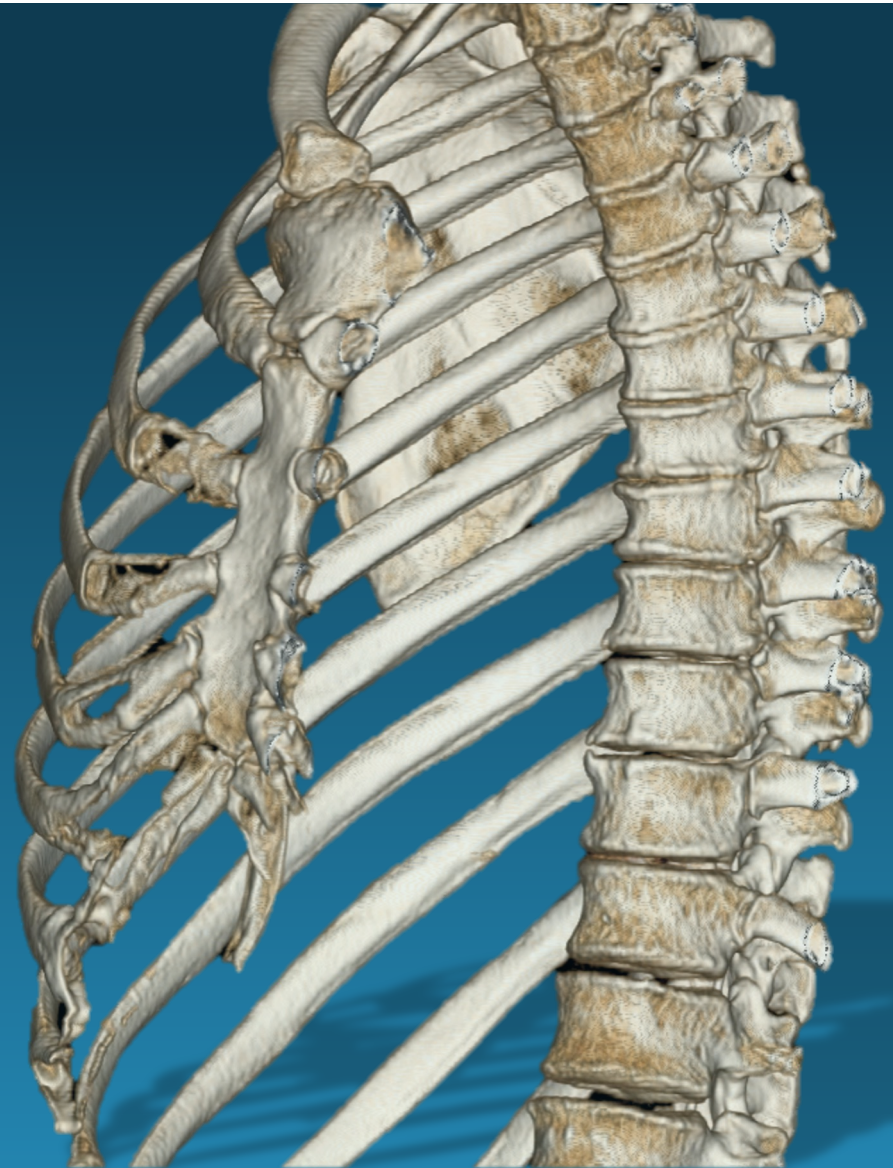
- T<sub>1</sub> - T<sub>10</sub>
- articulate to sternum & manubrium
  - ↑ stiffness
  - ↑ axial load capacity 4x



# T-SPINE TRAUMA

## Fractures

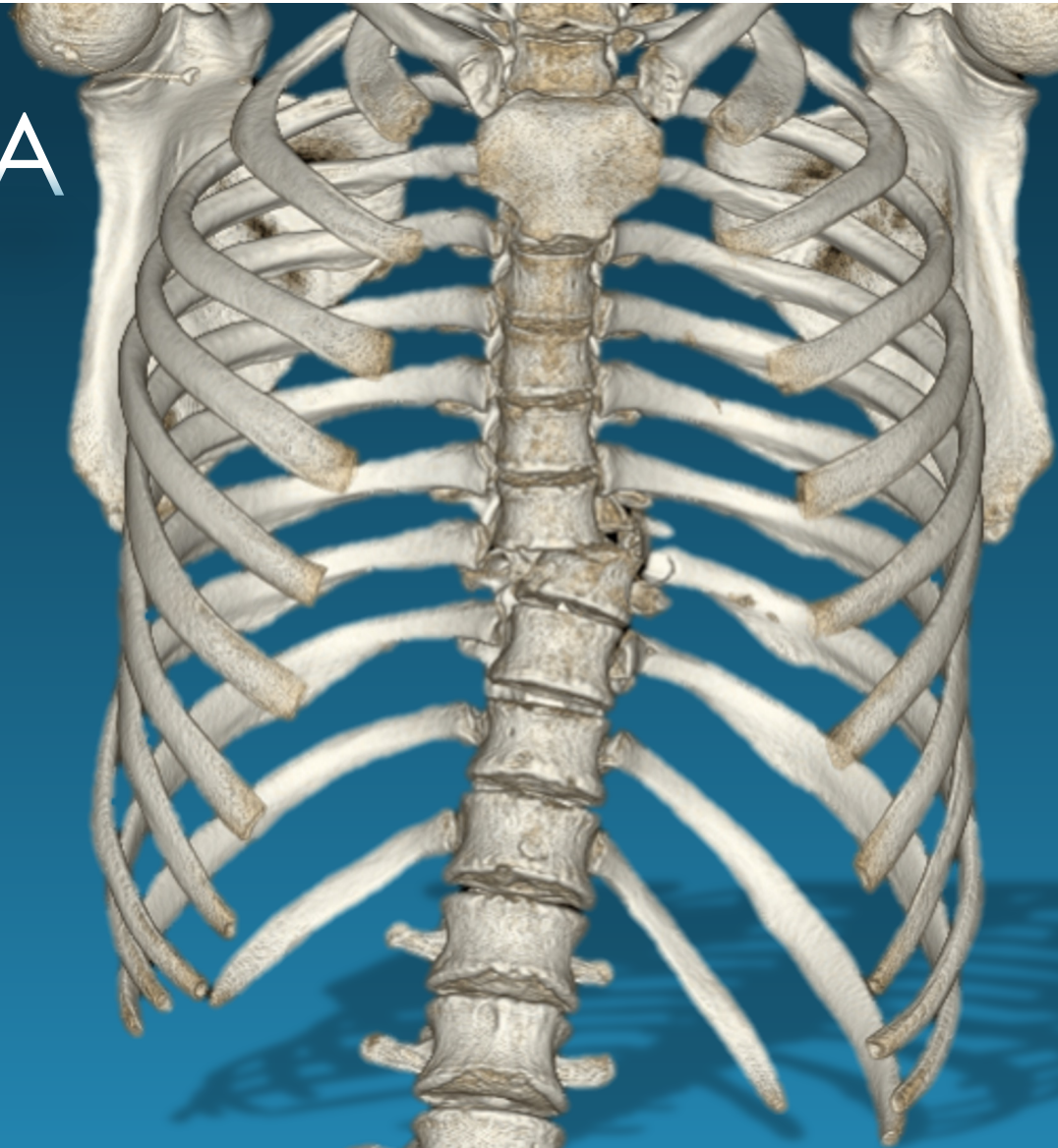
- High energy required to fracture
- narrowest canal → 50% neuro deficit
- Up to 25% noncontiguous fractures
  - *Image entire spine*



# T-SPINE TRAUMA

## Mechanism

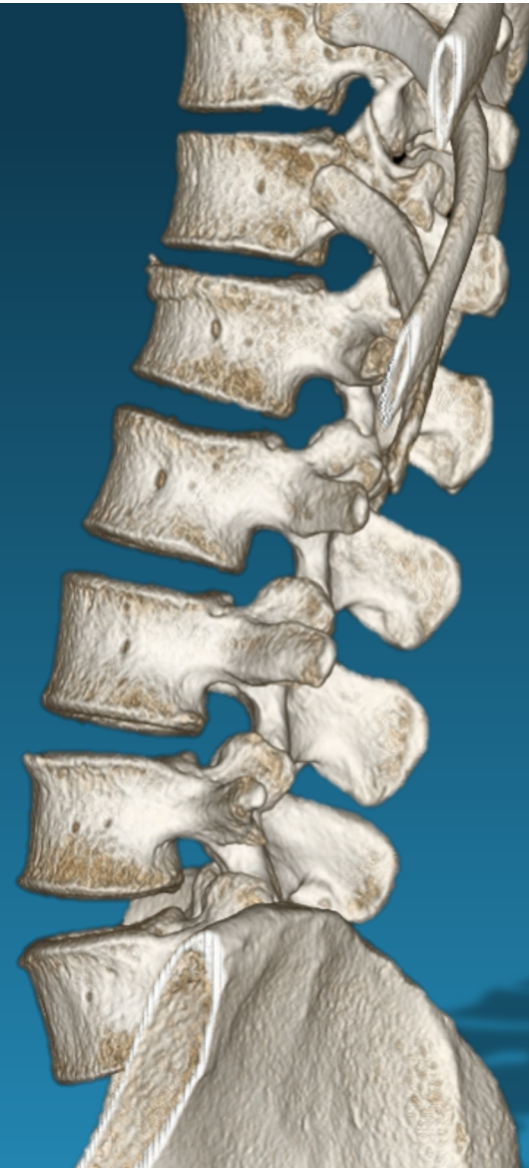
- Flexion & axial loading predominate
- Minimal rotation,  $2^{\circ}$  to ribs
- **Fracture-dislocations** > compression, burst



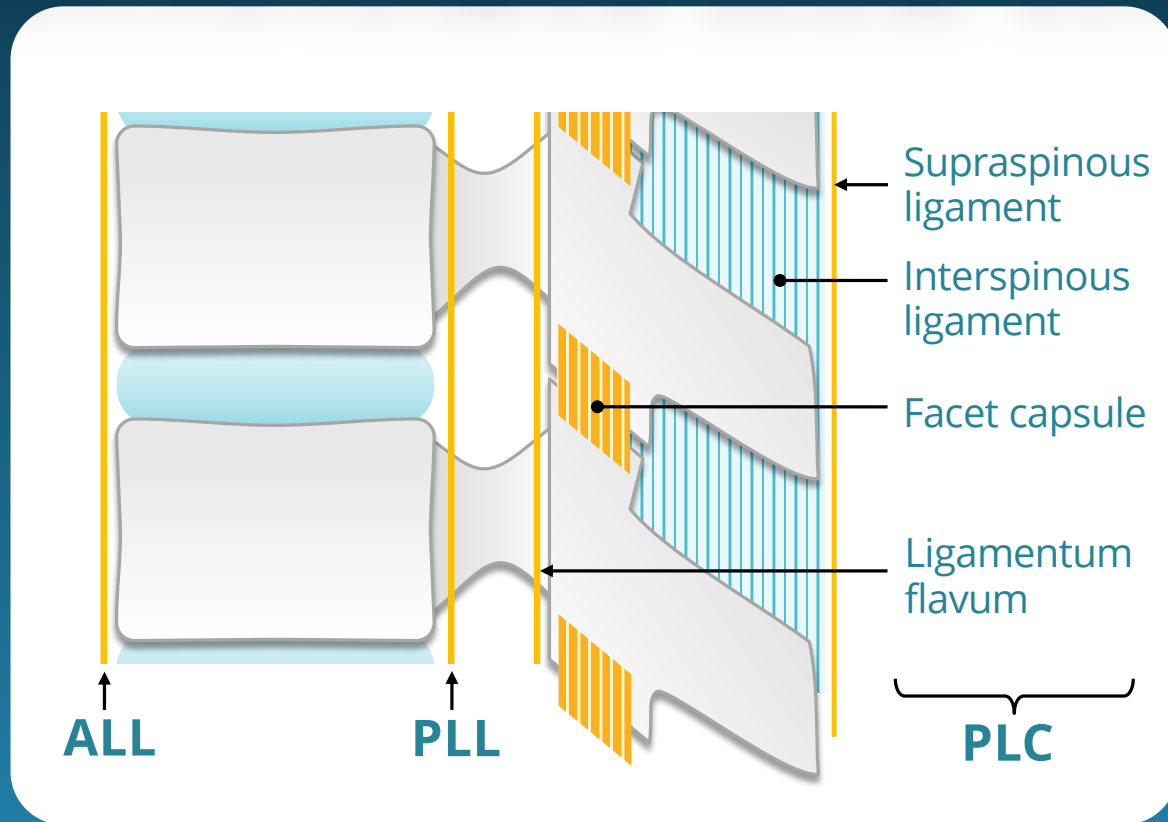
# L-SPINE ANATOMY

## Lumbar Spine

- Typically 5 lumbar type vertebrae
- 3 articulations: disk & paired facets
- ↑ mobility



# THORACOLUMBAR SPINE ANATOMY

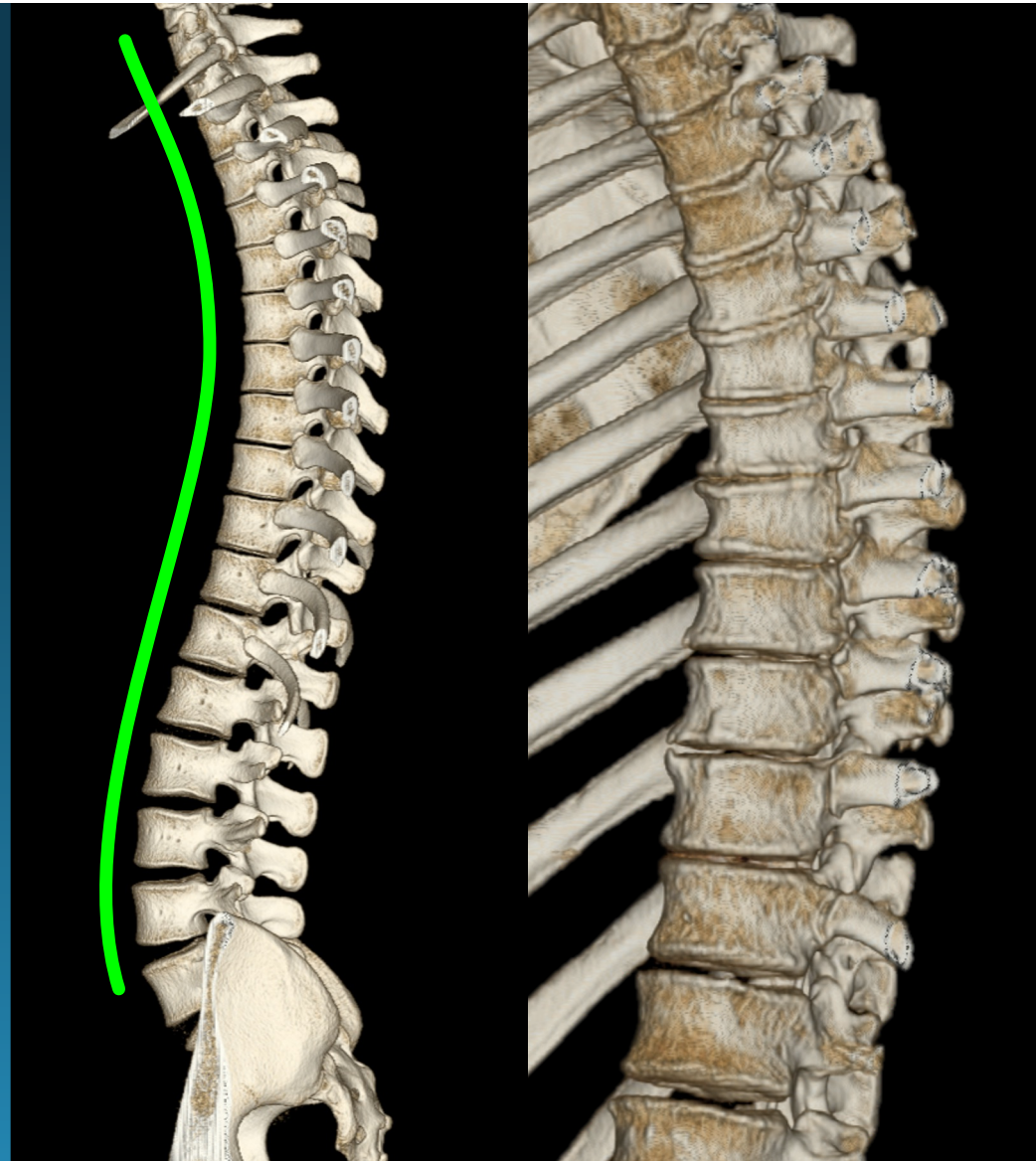




# T/L ANATOMY

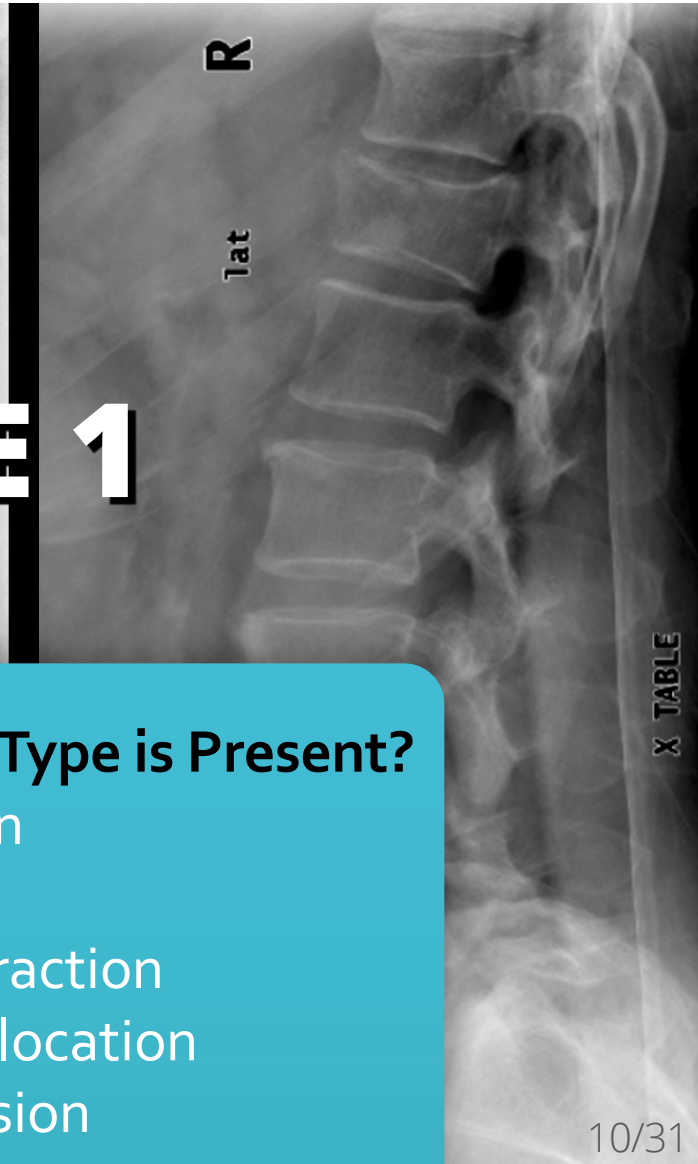
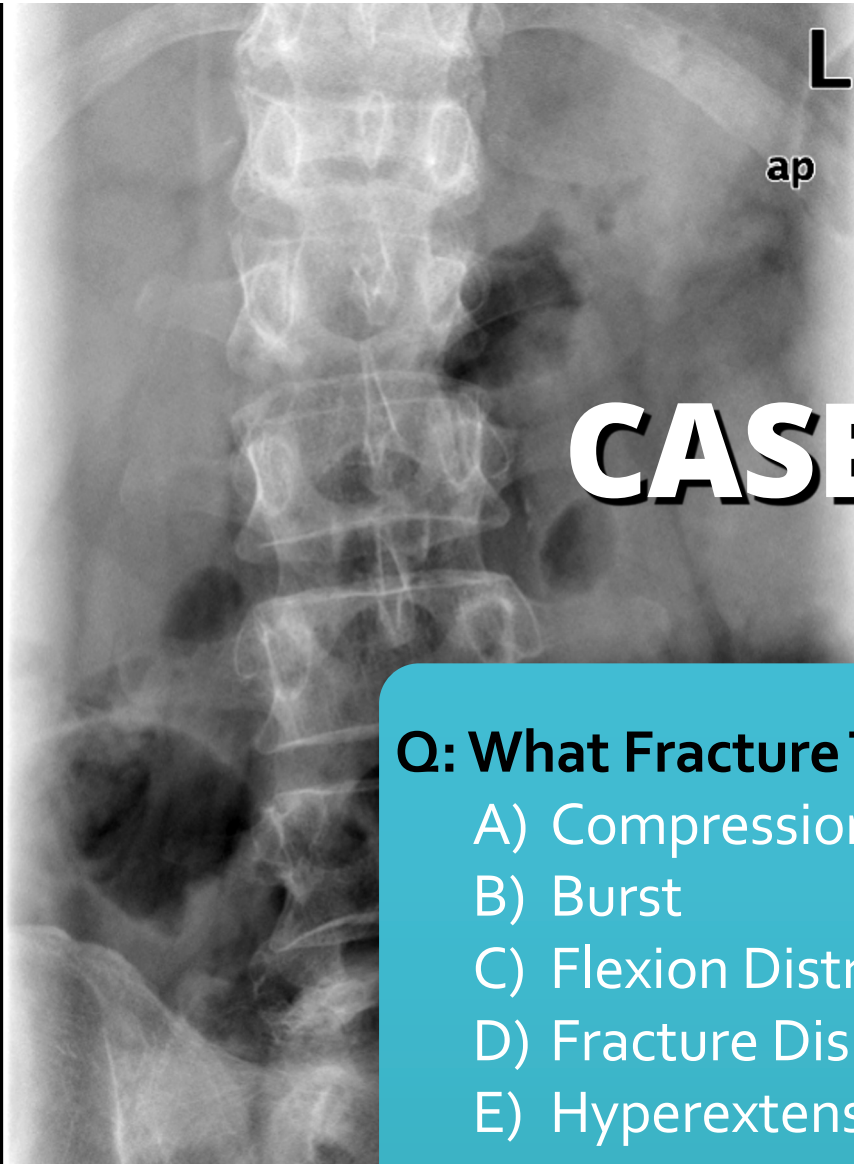
## Thoracolumbar Junction

- 40% of TL-spine fractures
- **Prone to injury:**
  - $\Delta$  rigid  $\rightarrow$  mobile
  - $\Delta$  kyphotic  $\rightarrow$  lordotic
  - $\Delta$  facets: cor  $\rightarrow$  sag



# T/L SPINE STABILITY

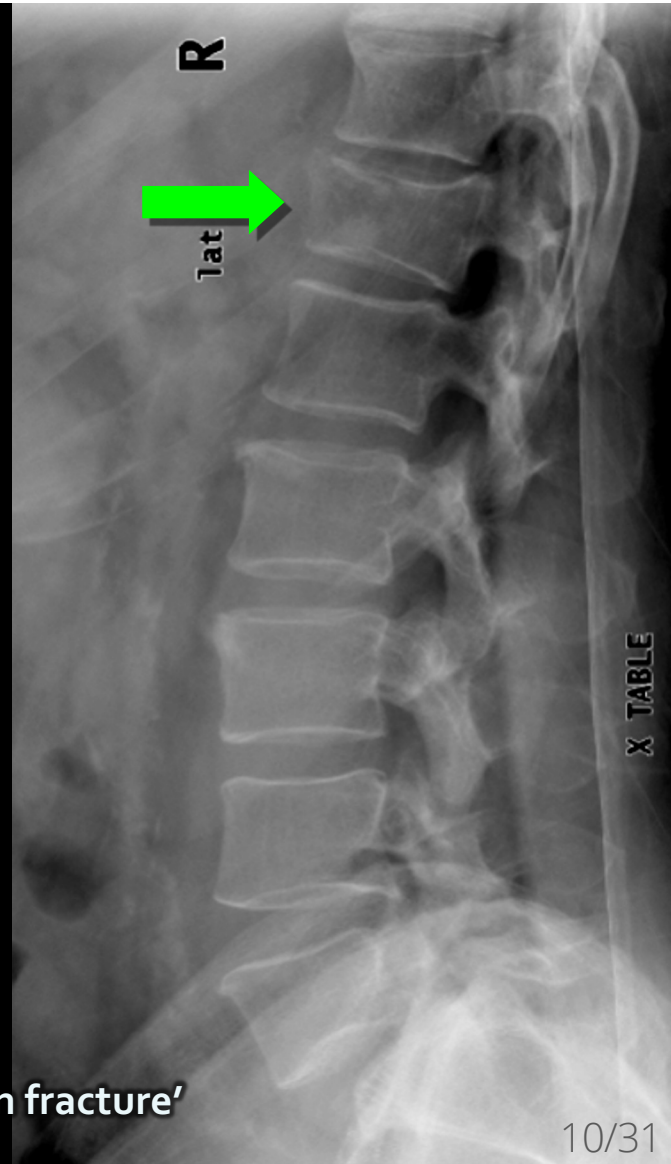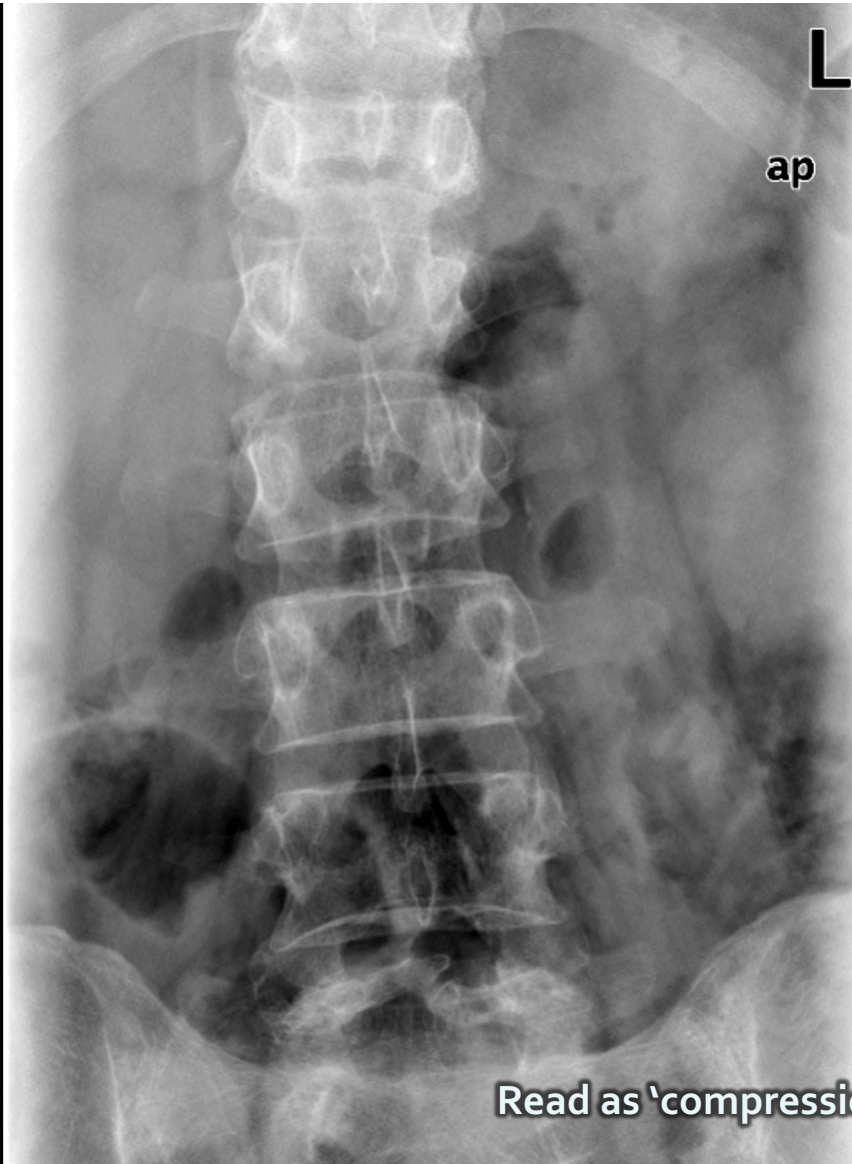




# CASE 1

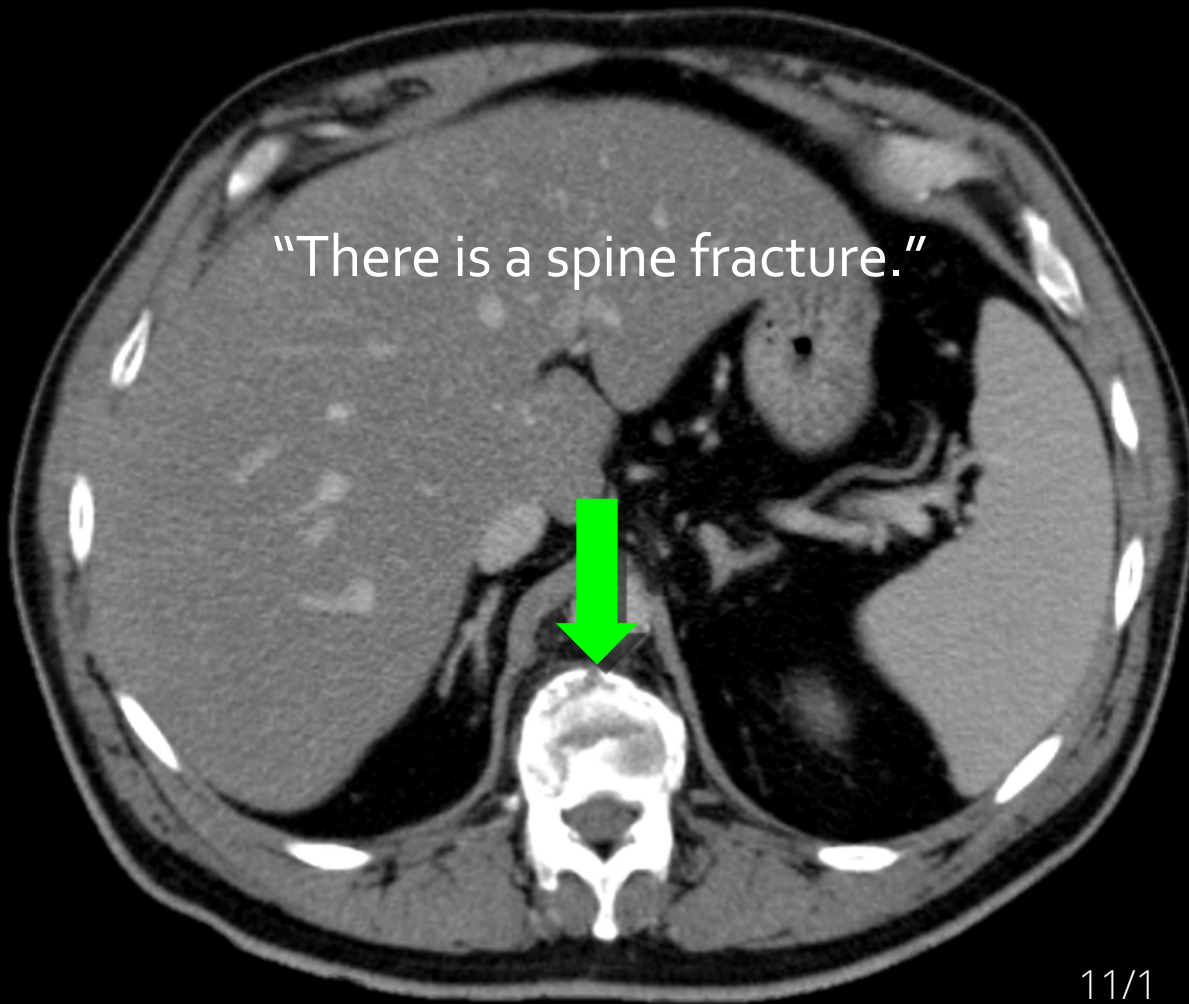
**Q: What Fracture Type is Present?**

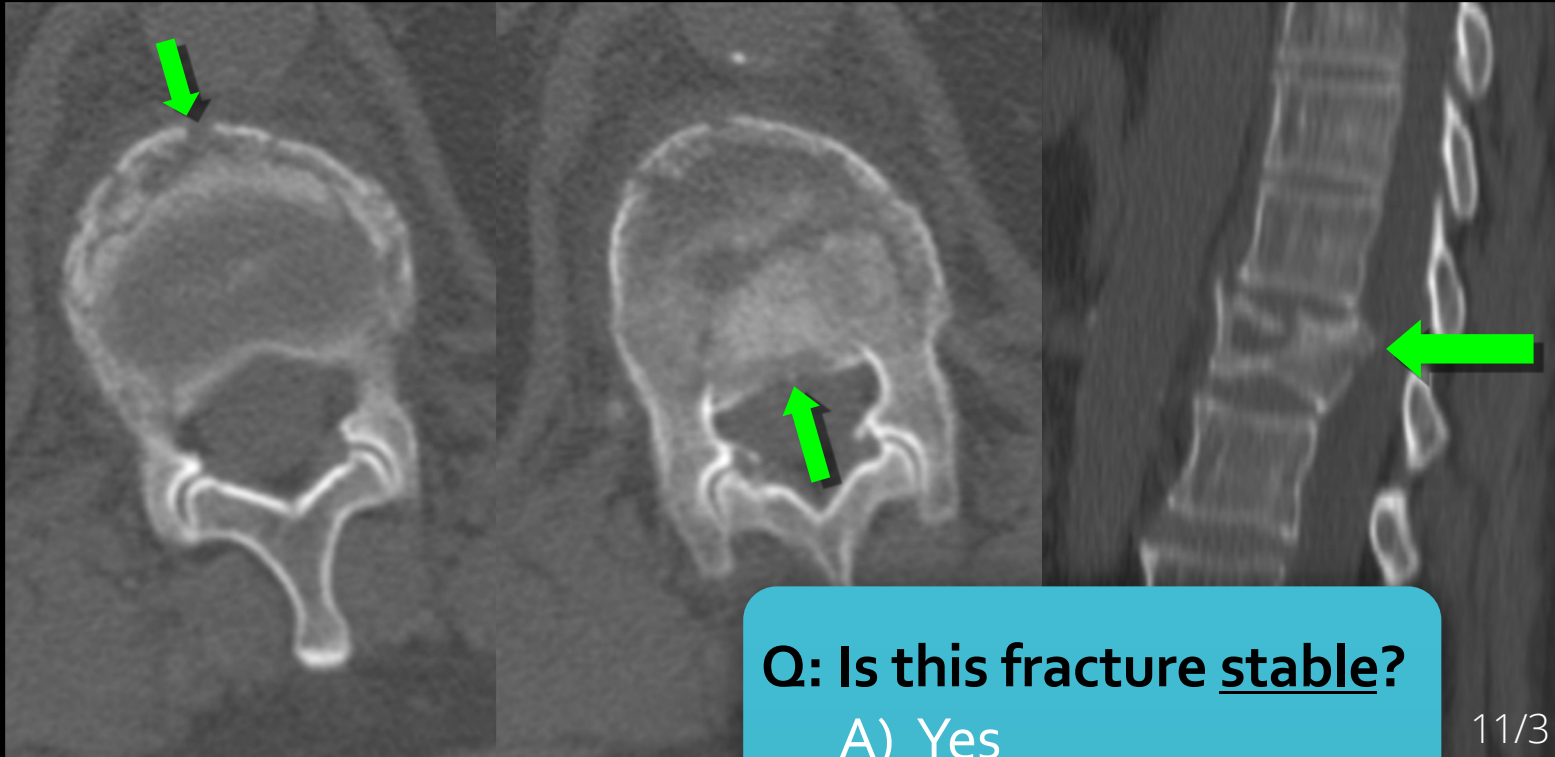
- A) Compression
- B) Burst
- C) Flexion Distraction
- D) Fracture Dislocation
- E) Hyperextension



Read as 'compression fracture'

"There is a spine fracture."





CT Dx: burst fracture

Q: Is this fracture stable?

- A) Yes
- B) No

11/3

# T/L SPINE TRAUMA

## Stability

- What does it mean?
- What does it mean for radiologists?

- We talk about it, but *what is it?*

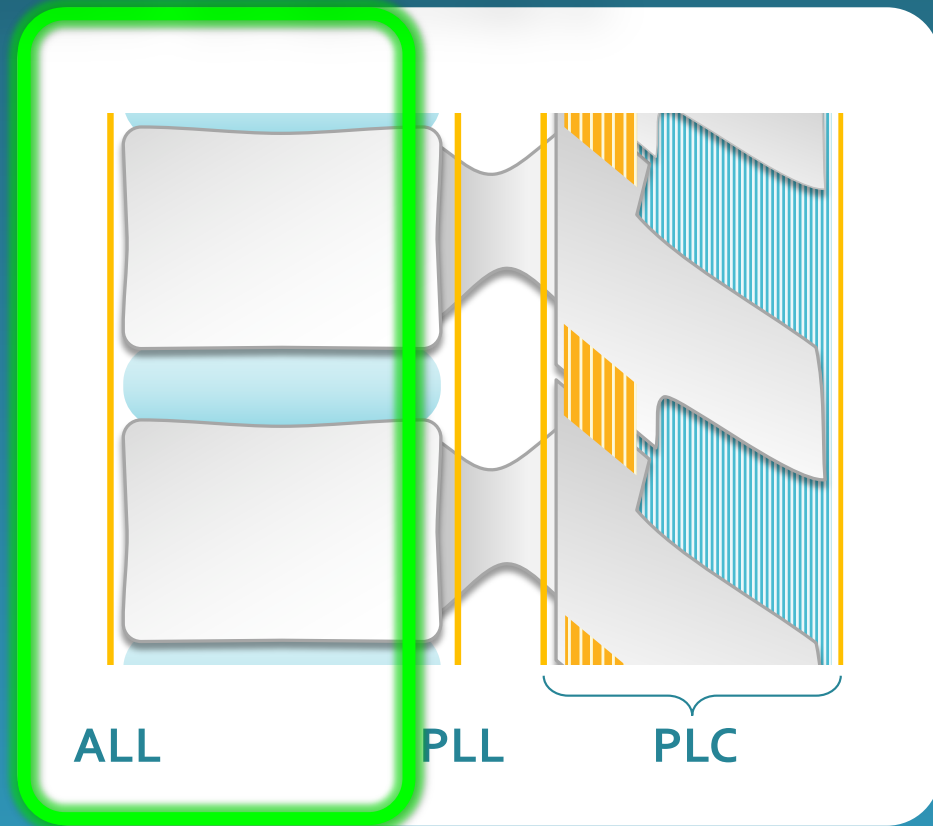
- **Useful Definition:**

- An injury is **STABLE** if putting the spinal column through normal ROM does not increase **neurological** or **mechanical** deficits

# THREE COLUMN THEORY

## Anterior Column

- Anterior longitudinal ligament (ALL)
- Anterior vertebral body & disc

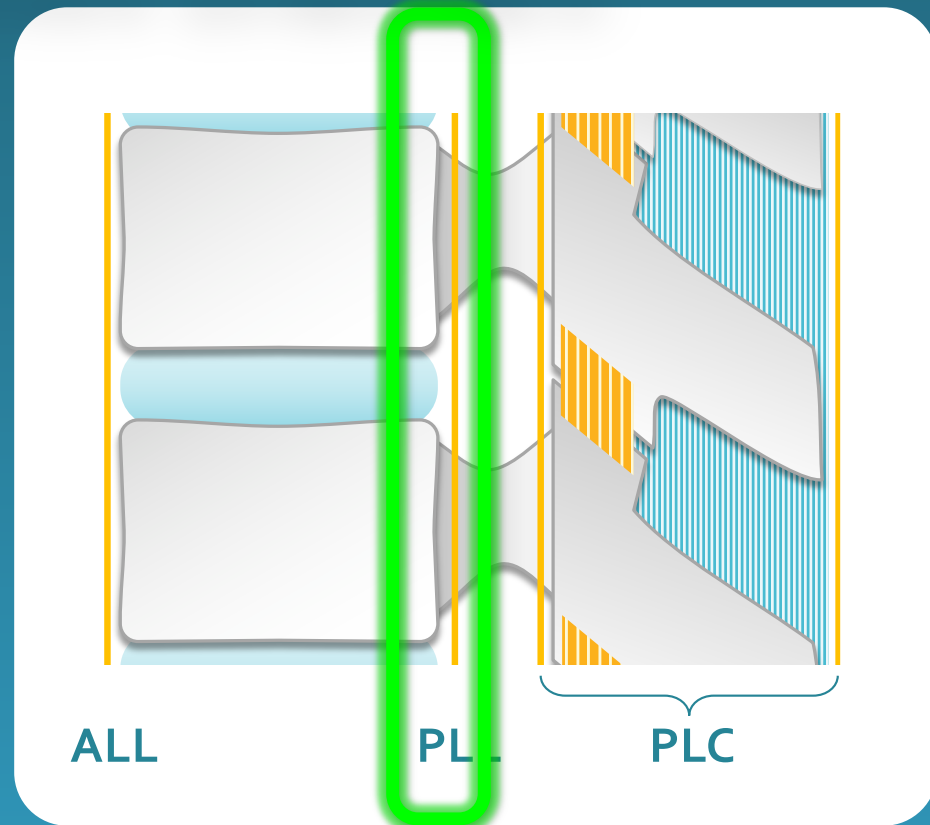



# THREE COLUMN THEORY

## Middle Column

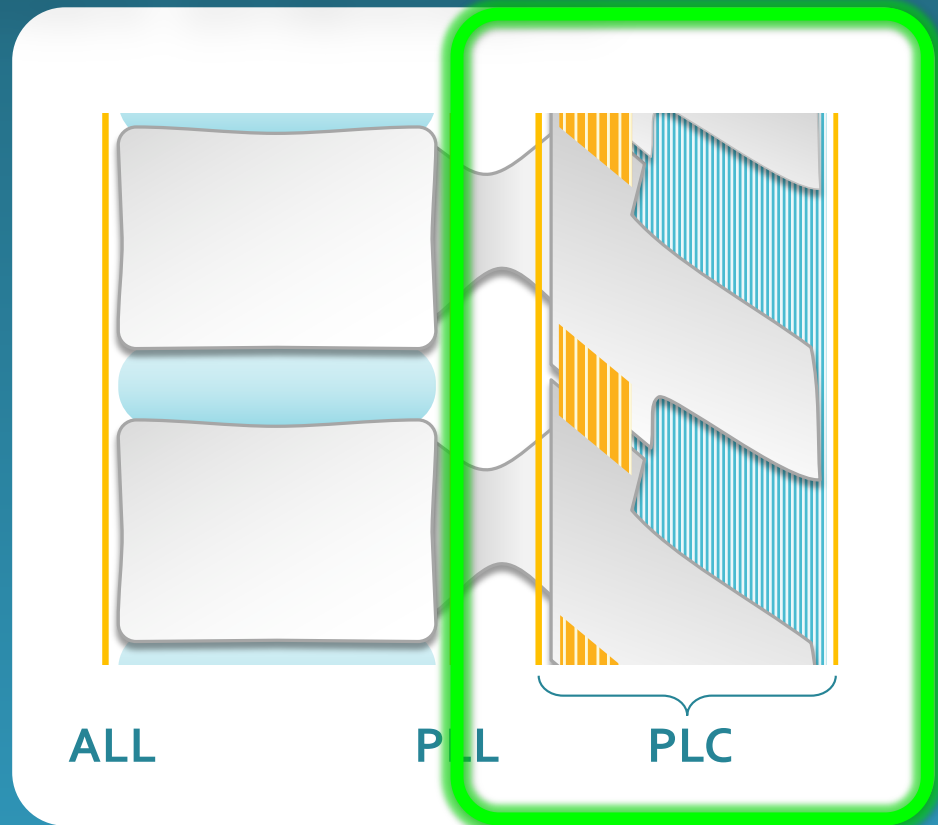
- Posterior longitudinal ligament (PLL)
- Posterior vertebral cortex & disc annulus



# THREE COLUMN THEORY

## Posterior Column

- Posterior bony arch
- Posterior ligament complex (PLC)



# T/L SPINE TRAUMA

## Stability

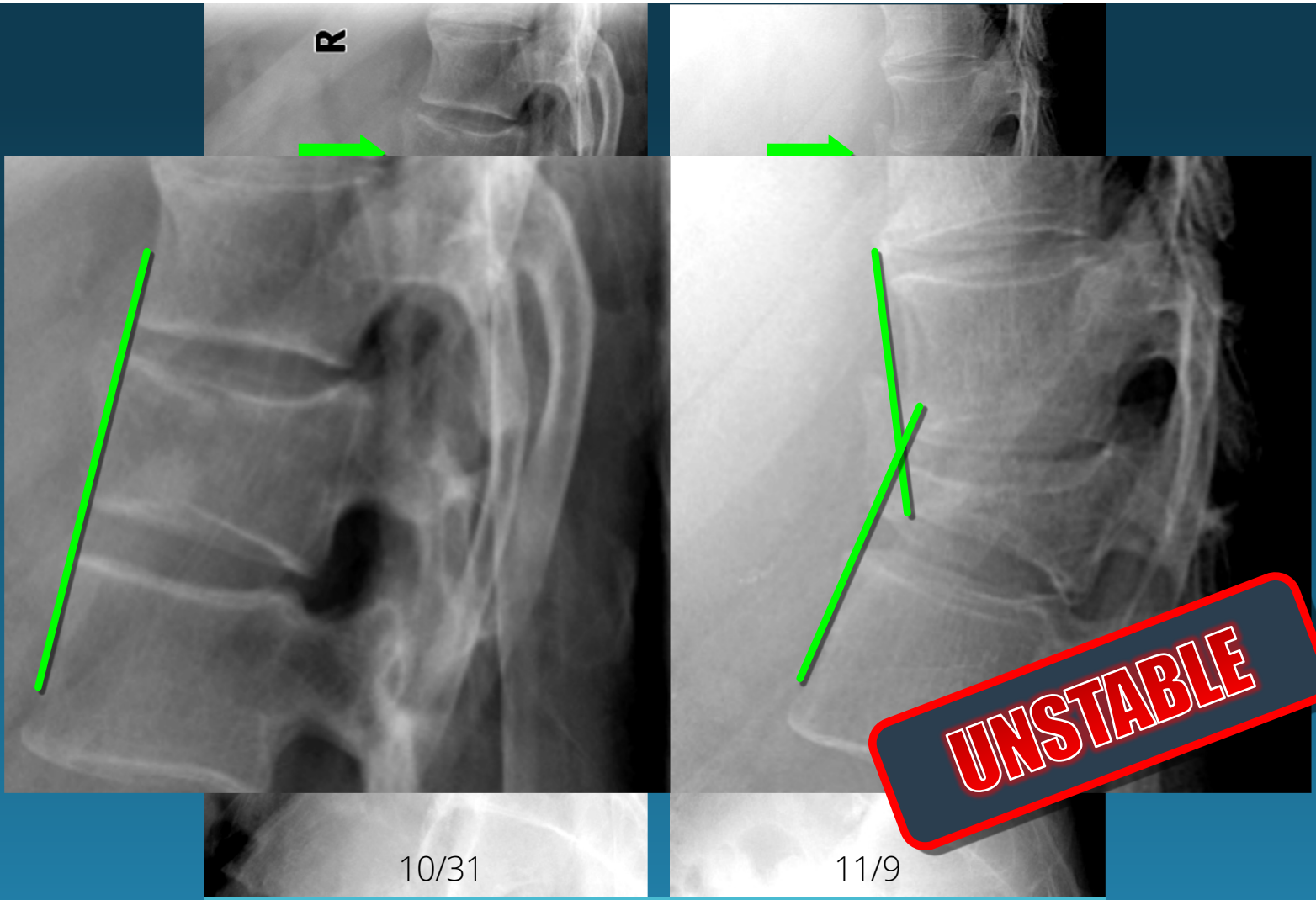
- What does it mean?
- What does it mean for *radiologists*?

## Useful Definition:

- An injury is **STABLE** if putting the spinal column through normal ROM does not increase **neurological** or **mechanical** deficits

## Does it work?

- if 2 or 3 columns injured = **UNSTABLE**
- middle column is key



R

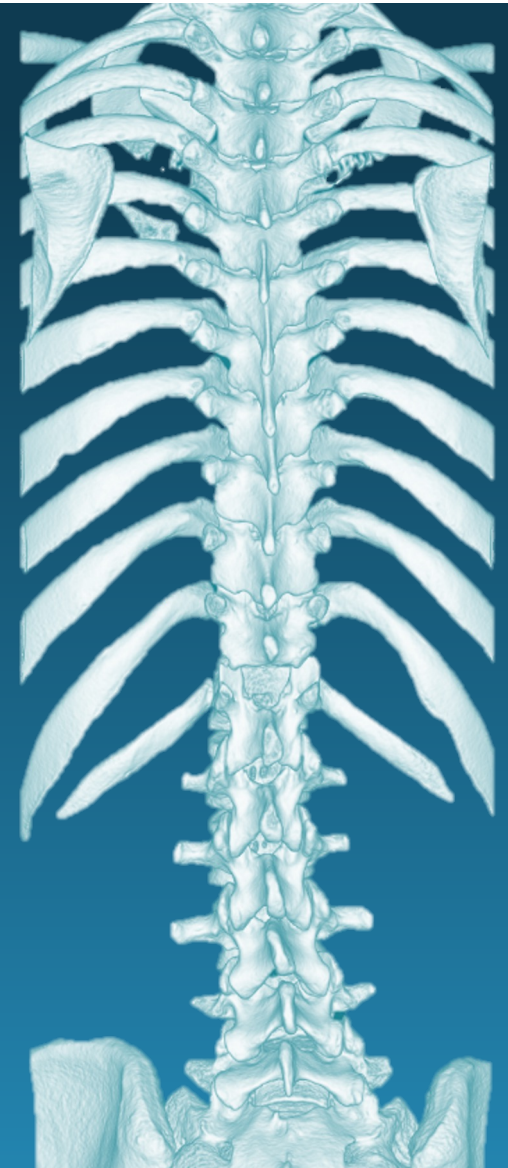
10/31

11/9

**UNSTABLE**

CASE 1...

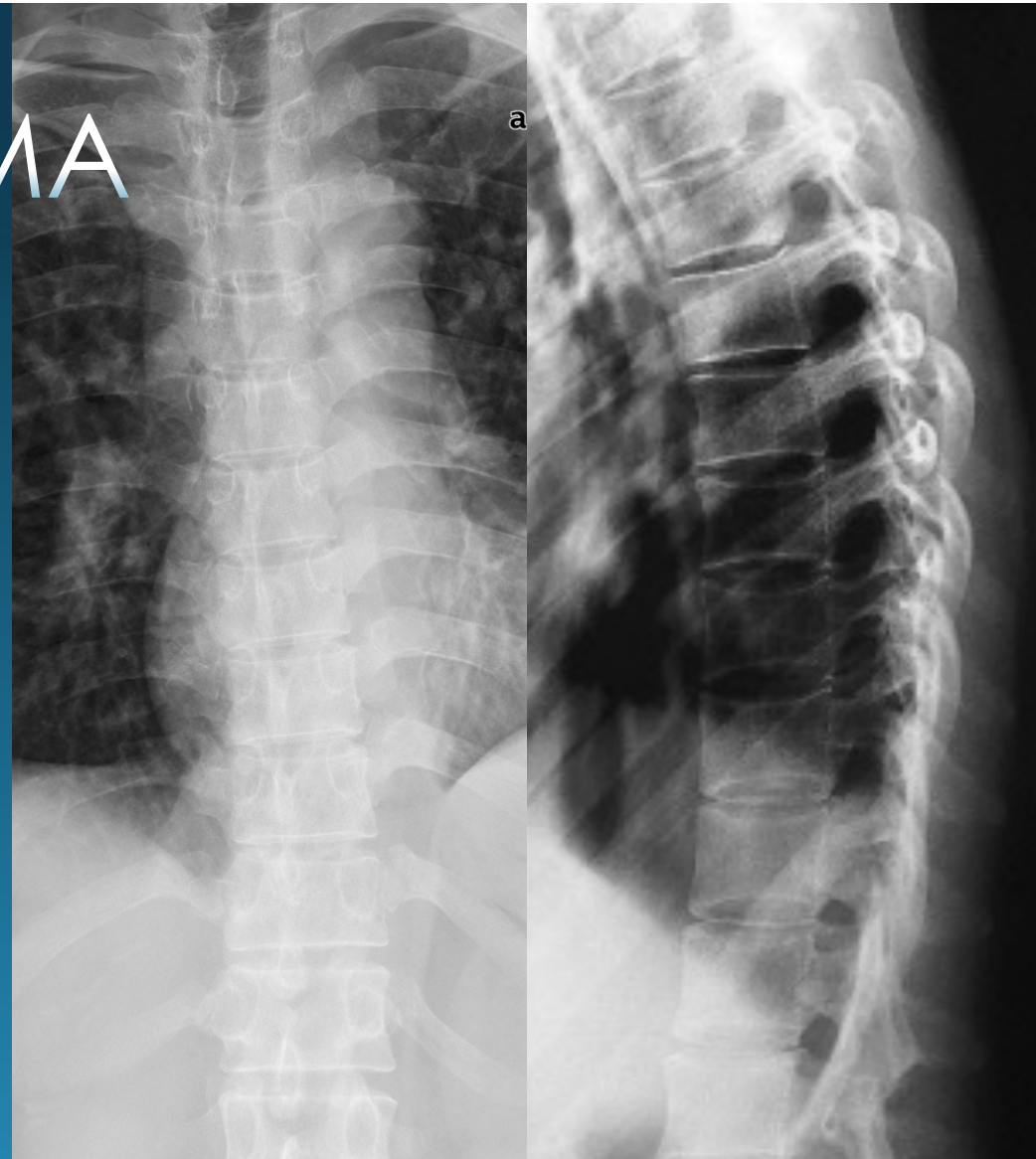
# T/L SPINE IMAGING



# T/L SPINE TRAUMA

## Targeted Spine X-Rays

- High kV, coned-in AP view
- X-table lateral (breathing technique)
- Swimmer's lateral for C-T jxn
- Screening largely replaced by CT

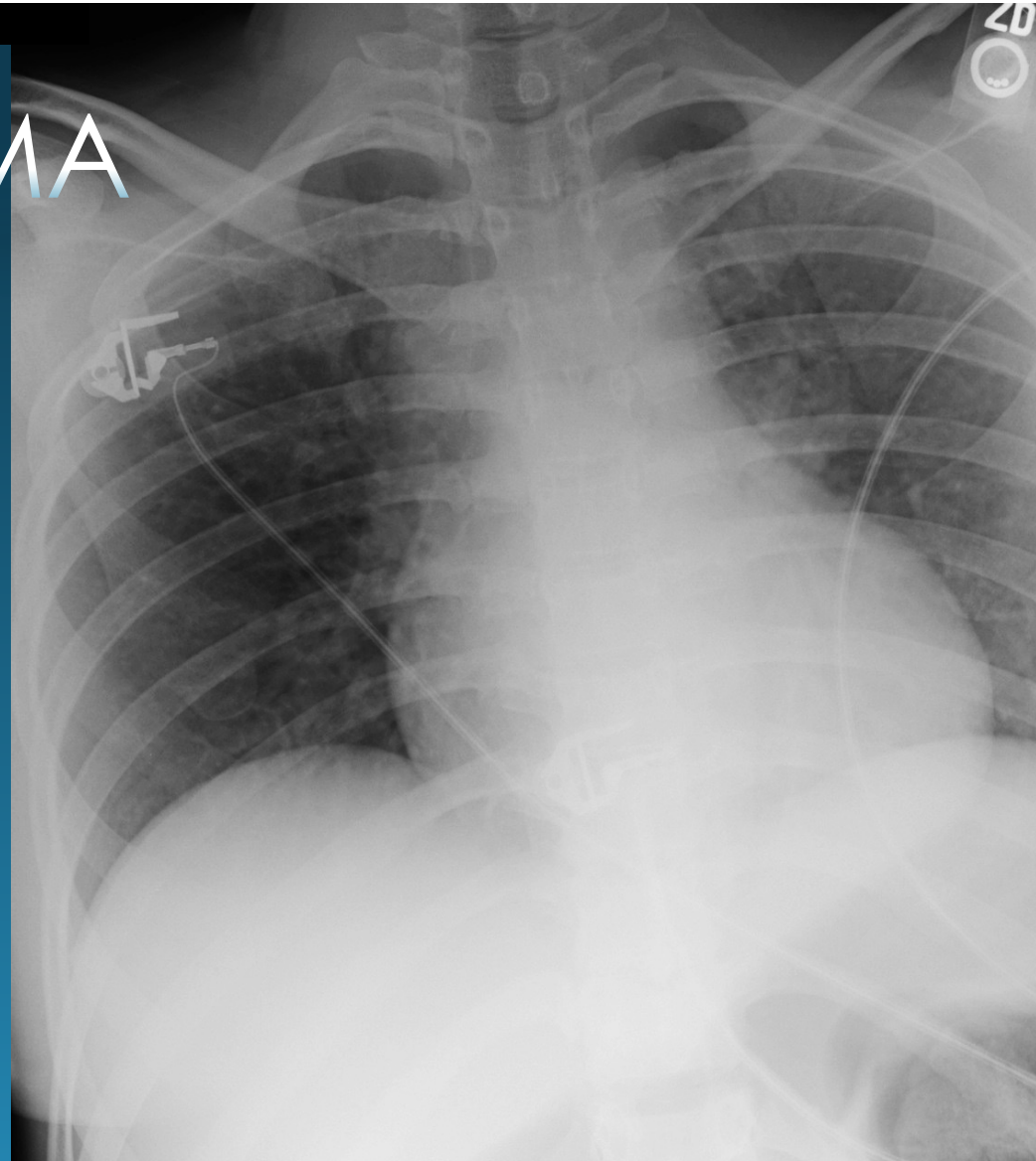


# T/L SPINE TRAUMA

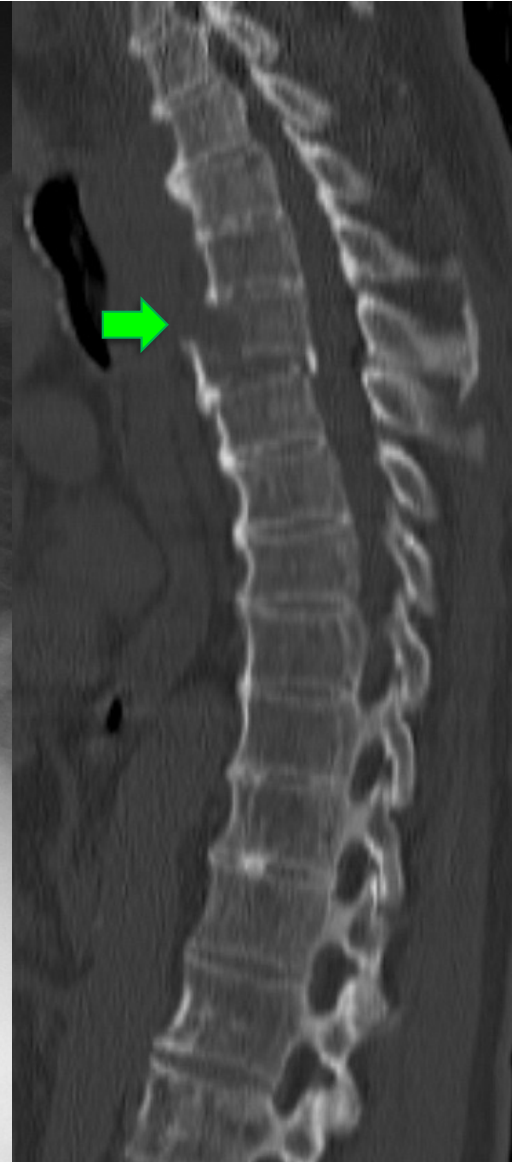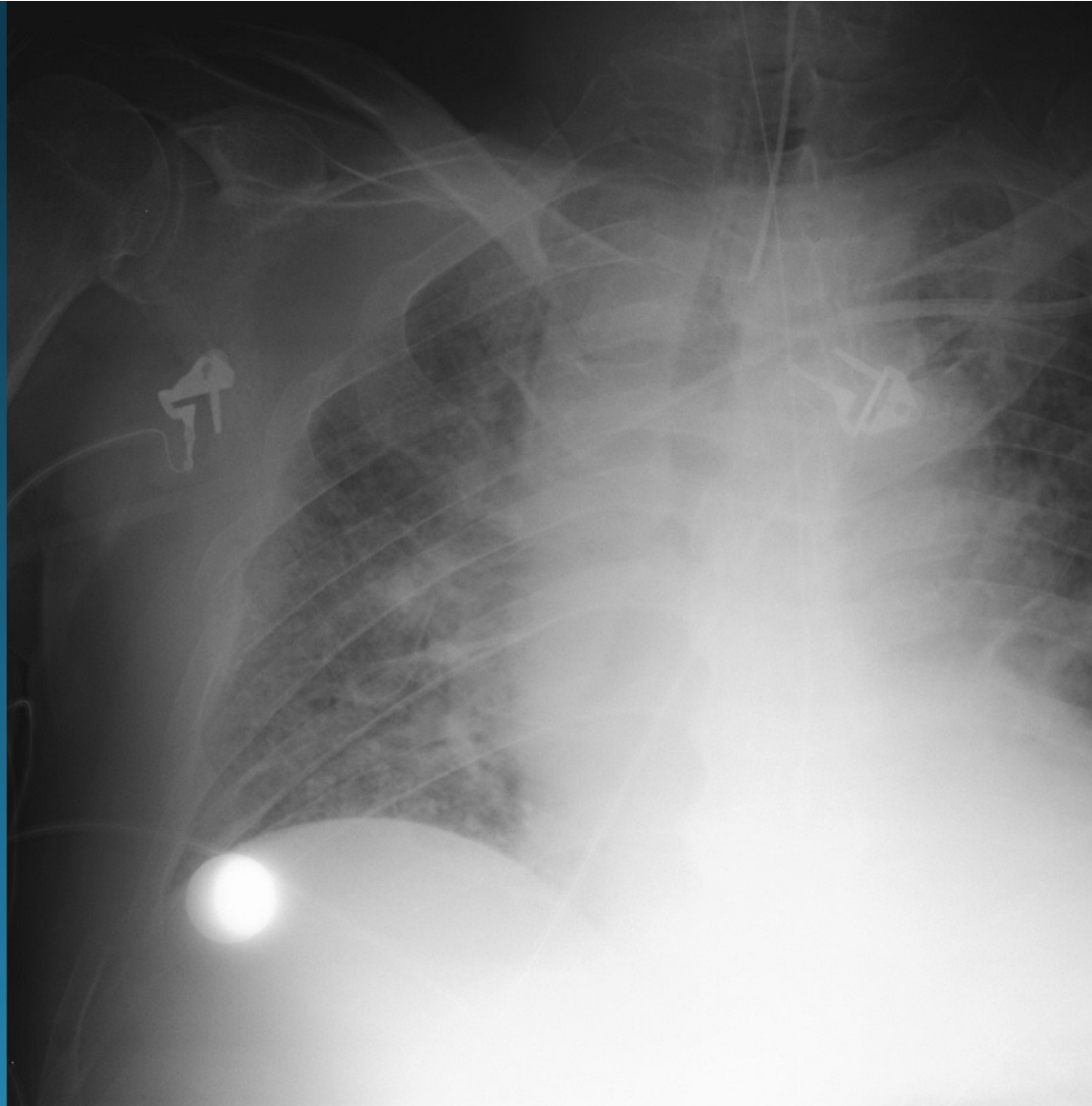
## Chest X-ray

- 50% AP CXR non-Dx
- **Indirect Signs:**
  - Paraspinal widening\*
  - Indistinct mediastinal contours\*
  - Hemothorax\*

*\*same signs as traumatic aortic injury*

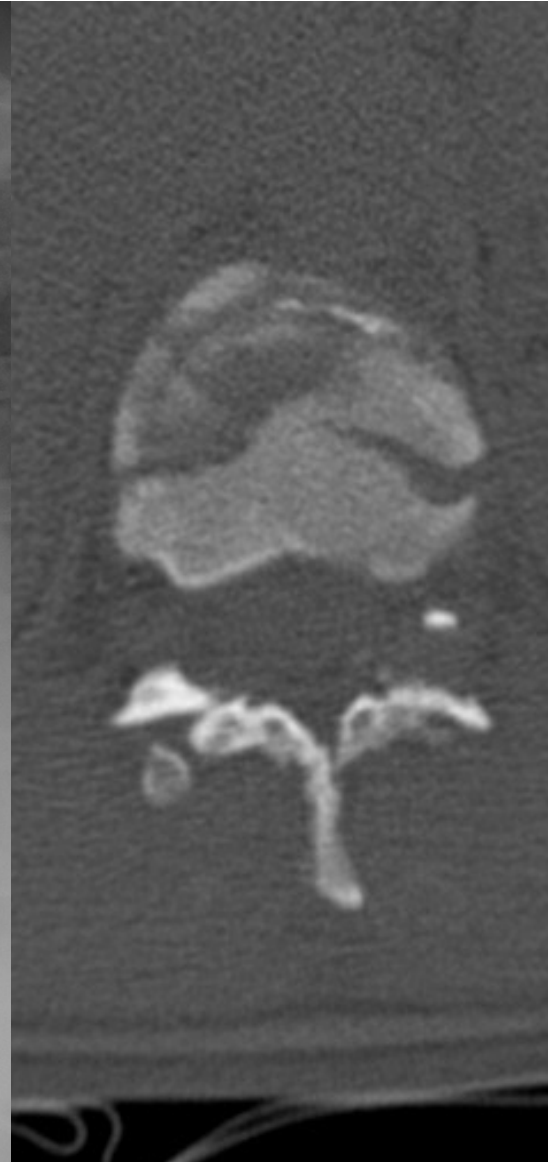
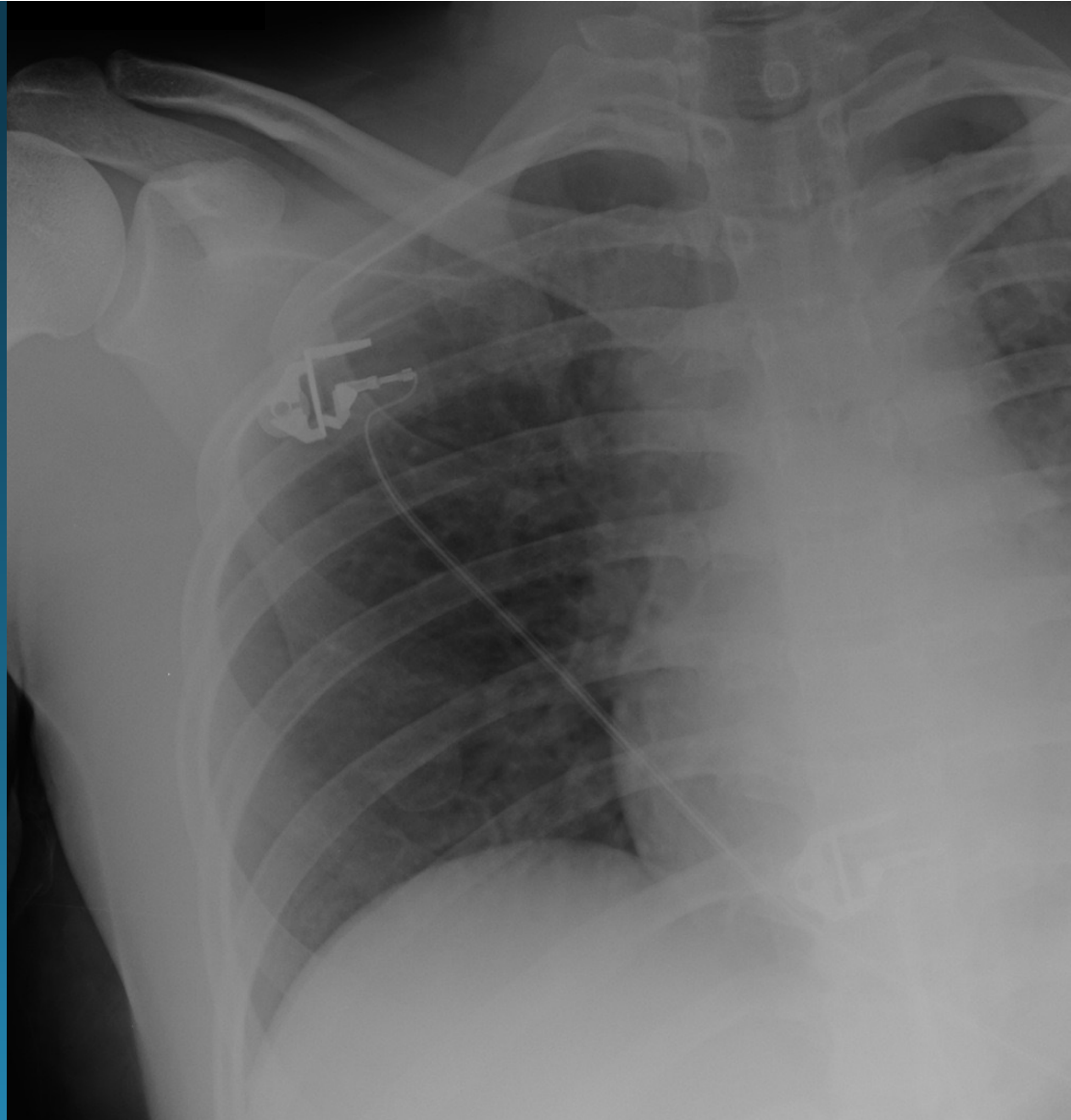


T-spine fx  
portable trauma CXR

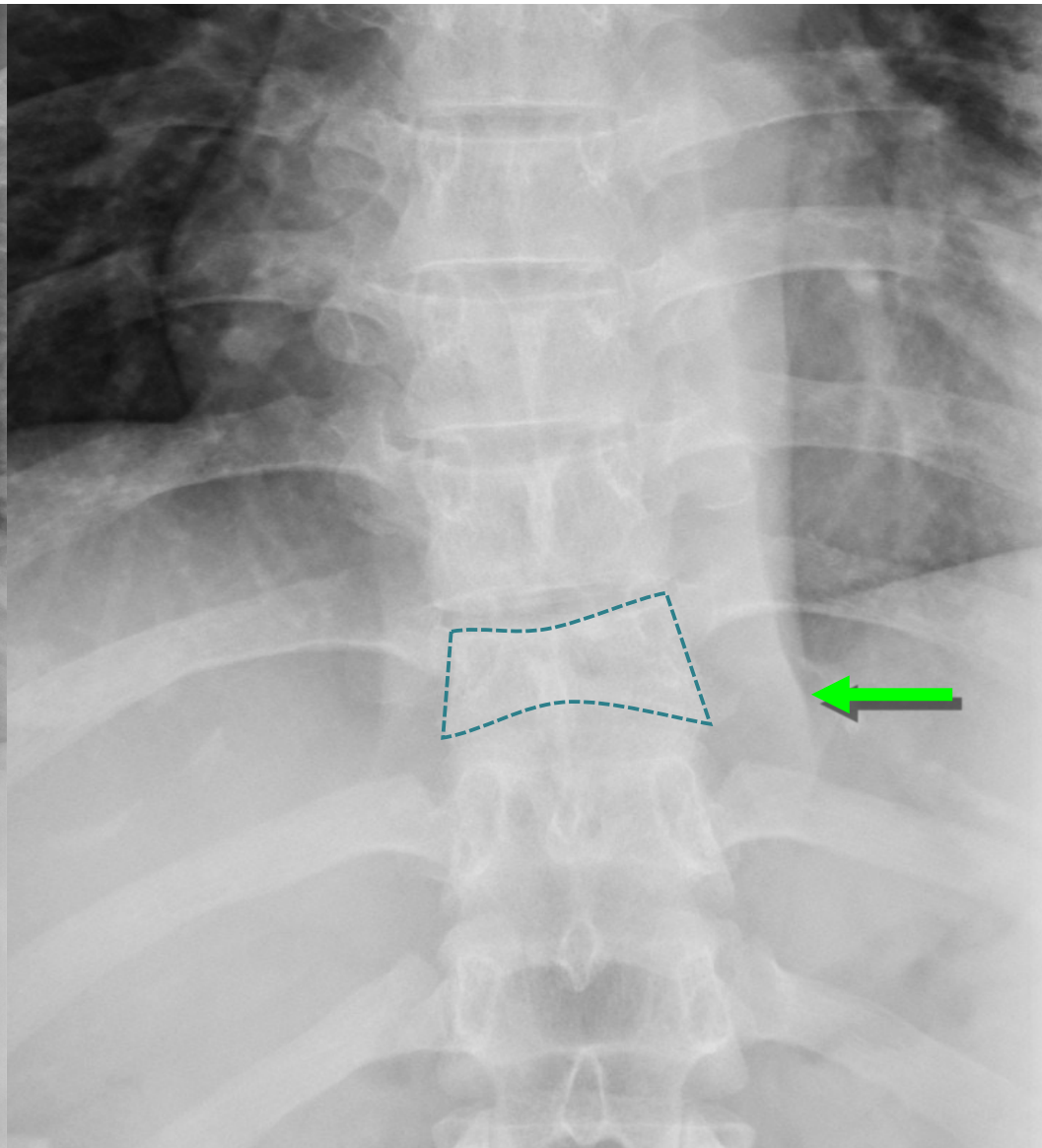
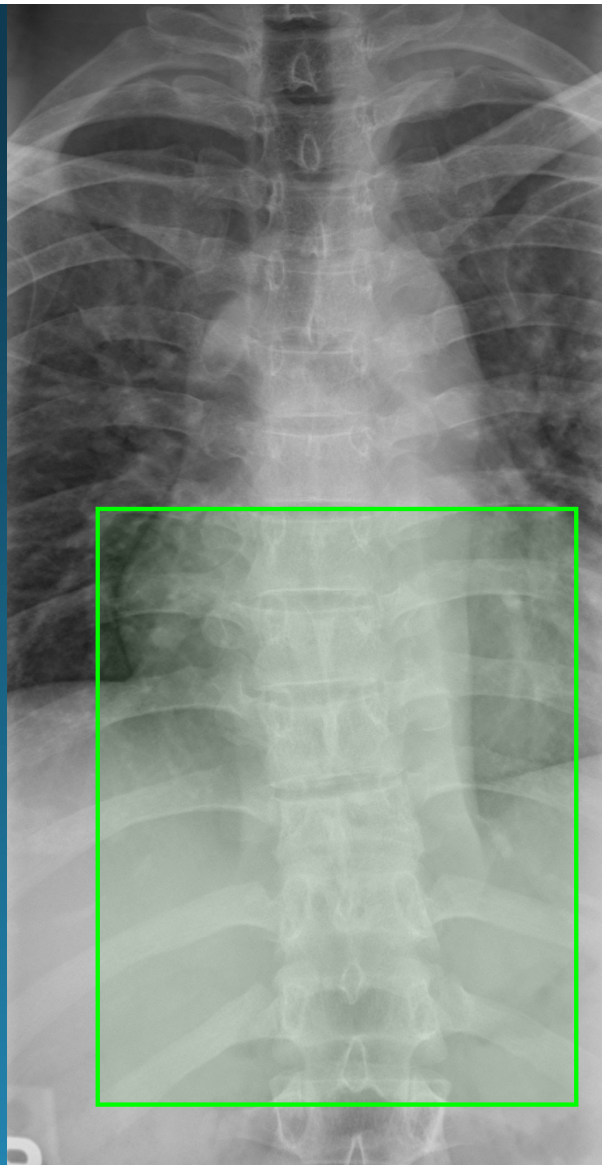




T-spine fx  
portable trauma CXR



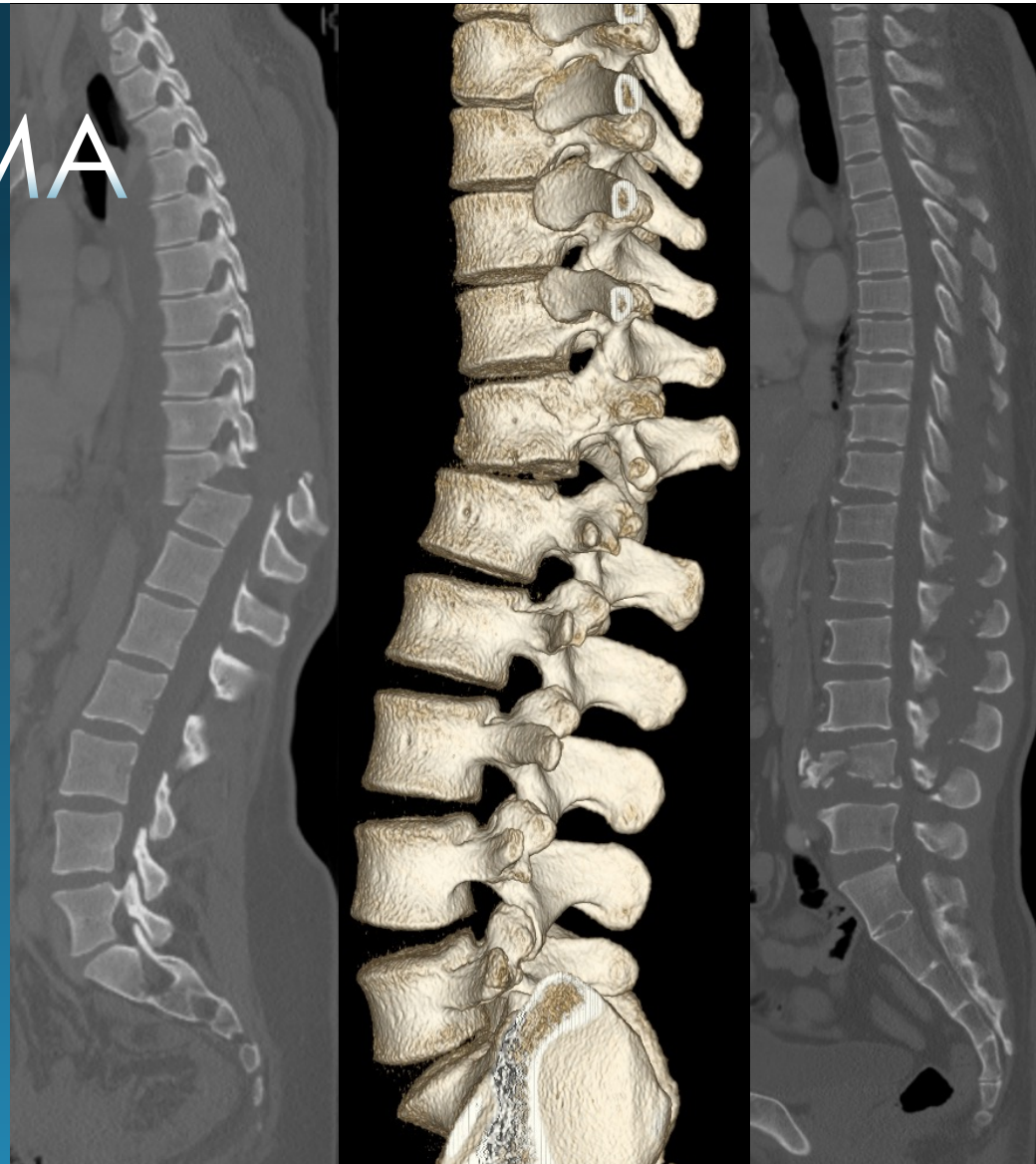
T-spine fx  
APT-spine X-ray



# T/L SPINE TRAUMA

## MDCT

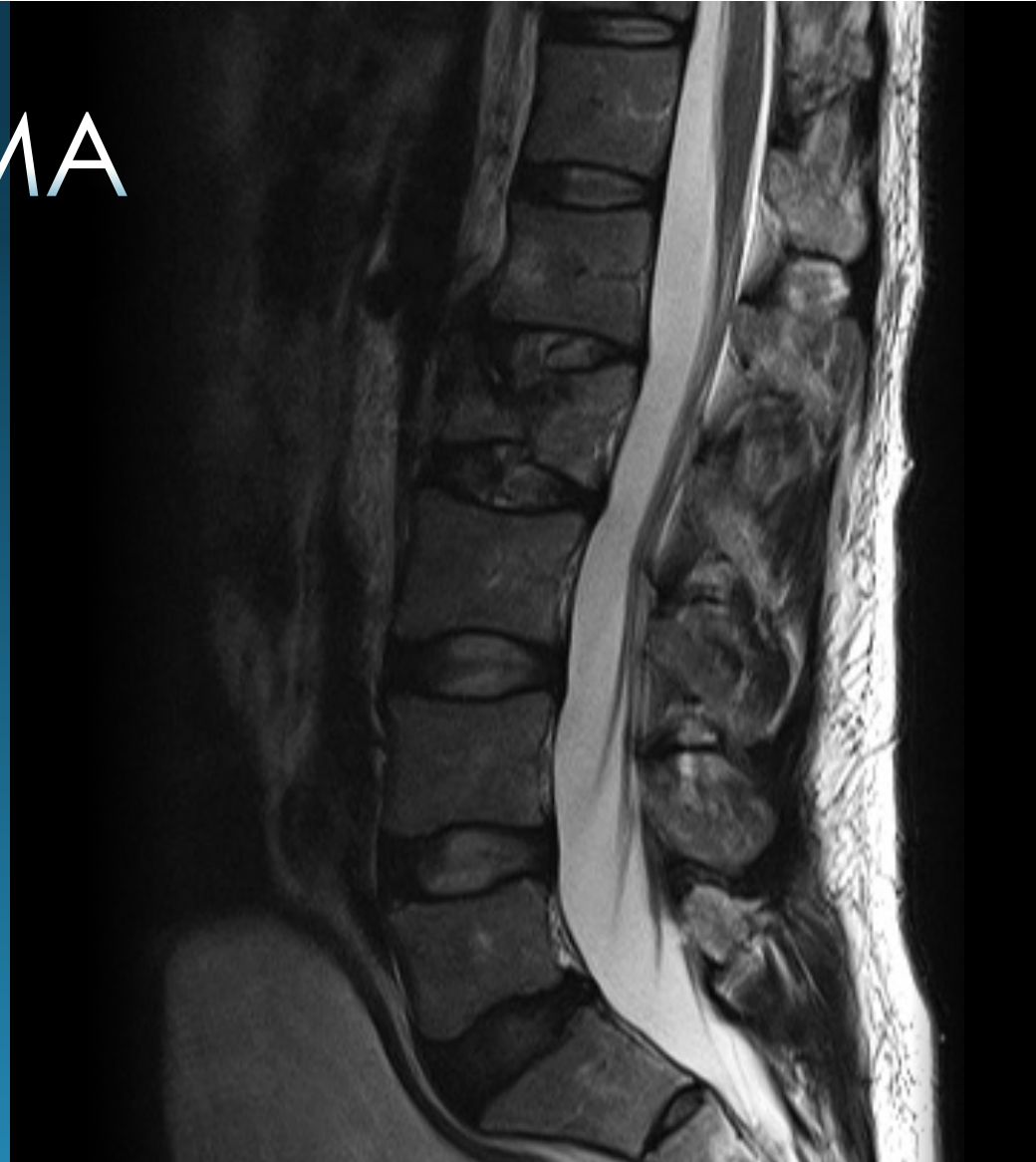- Gold standard for trauma:
  - fracture
  - alignment
- Spine reconstructed from CT torso dataset
  - 2x2 mm images in 3 planes
  - 3D rendering




# T/L SPINE TRAUMA

## MRI

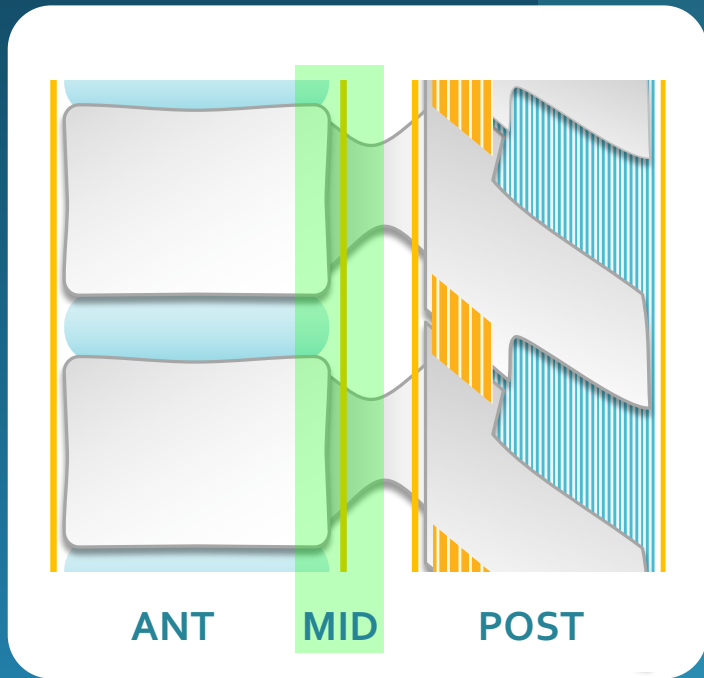
- Gold standard for soft tissue:
  - Cord, disk, epidural process
  - Ligaments (too sensitive?)
- Sensitive for detecting noncontiguous fractures
- Limited availability and access



# T/L SPINE FRACTURE PATTERNS



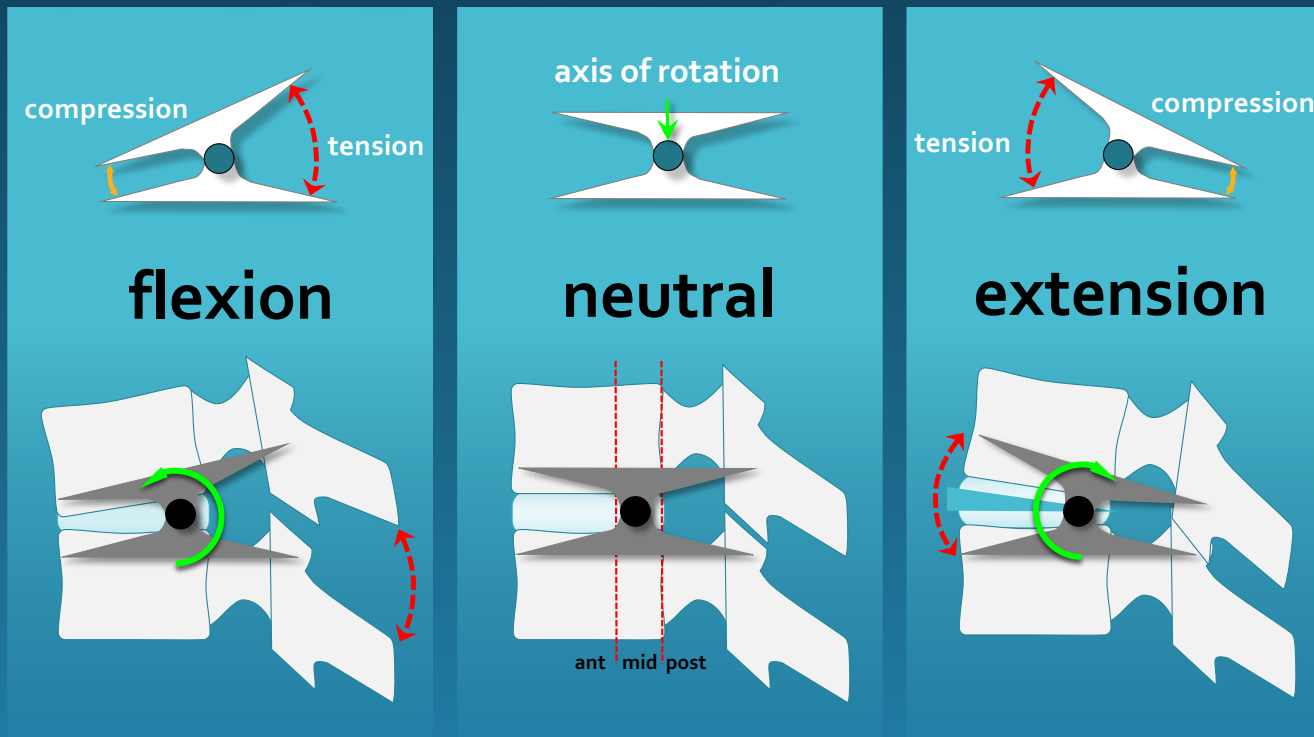
# 3 COLUMN - MODES OF FAILURE



	ANT	MID	POST
<b>Compression</b>	Compression	-	-
<b>Burst</b>	Compression	Compression	-
<b>Chance Type</b>	None or Compression	Distraction	Distraction
<b>Fracture Dislocation</b>	Compression, Rotation, Shear	Distraction, Compression, Shear	Distraction, Rotation, Shear
<b>Fused Spine Hyperextension</b>	Distraction	Distraction	None or Compression

**UNSTABLE**

# T/L SPINE TRAUMA

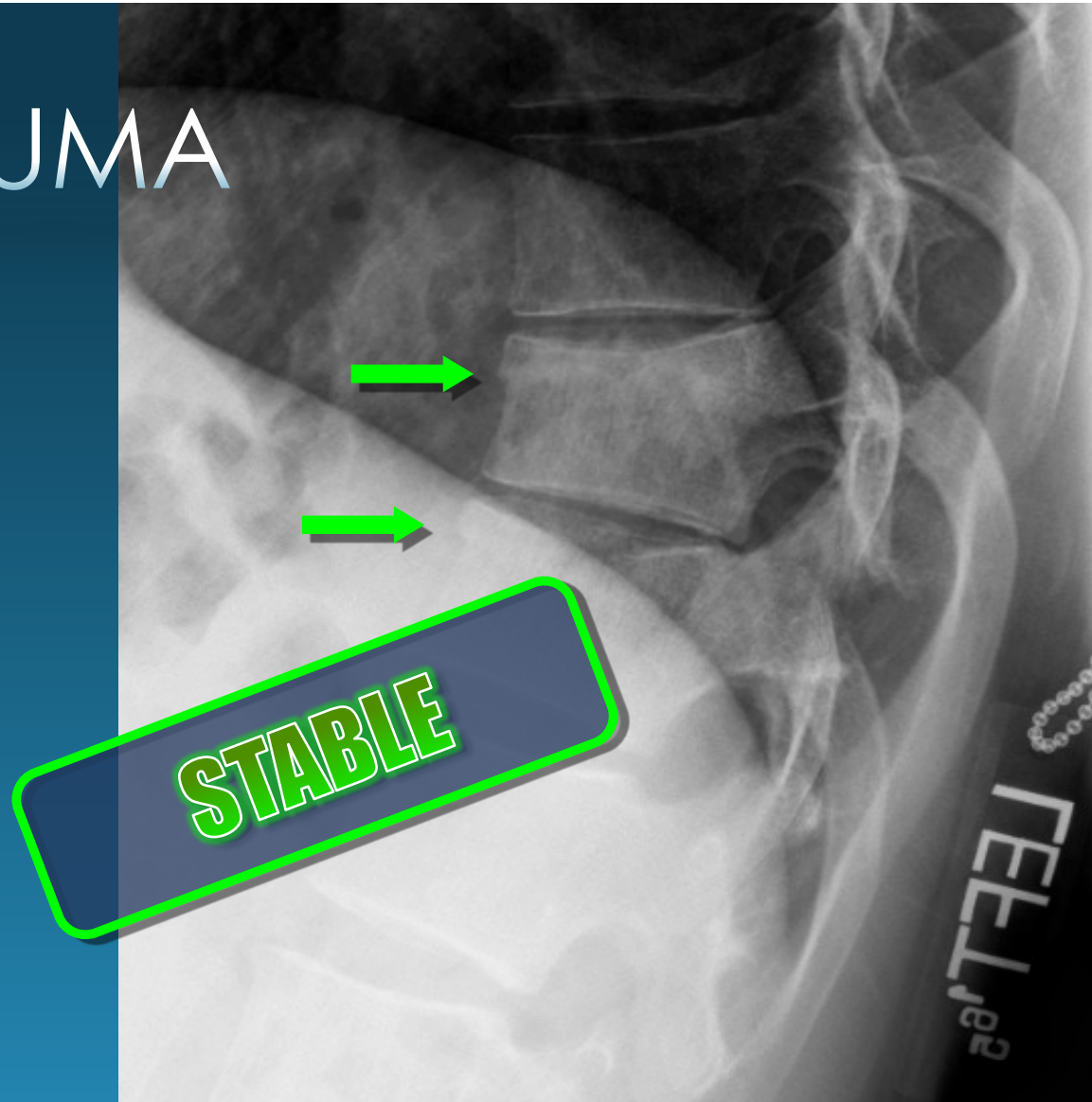


mechanism of injury

# T/L SPINE TRAUMA

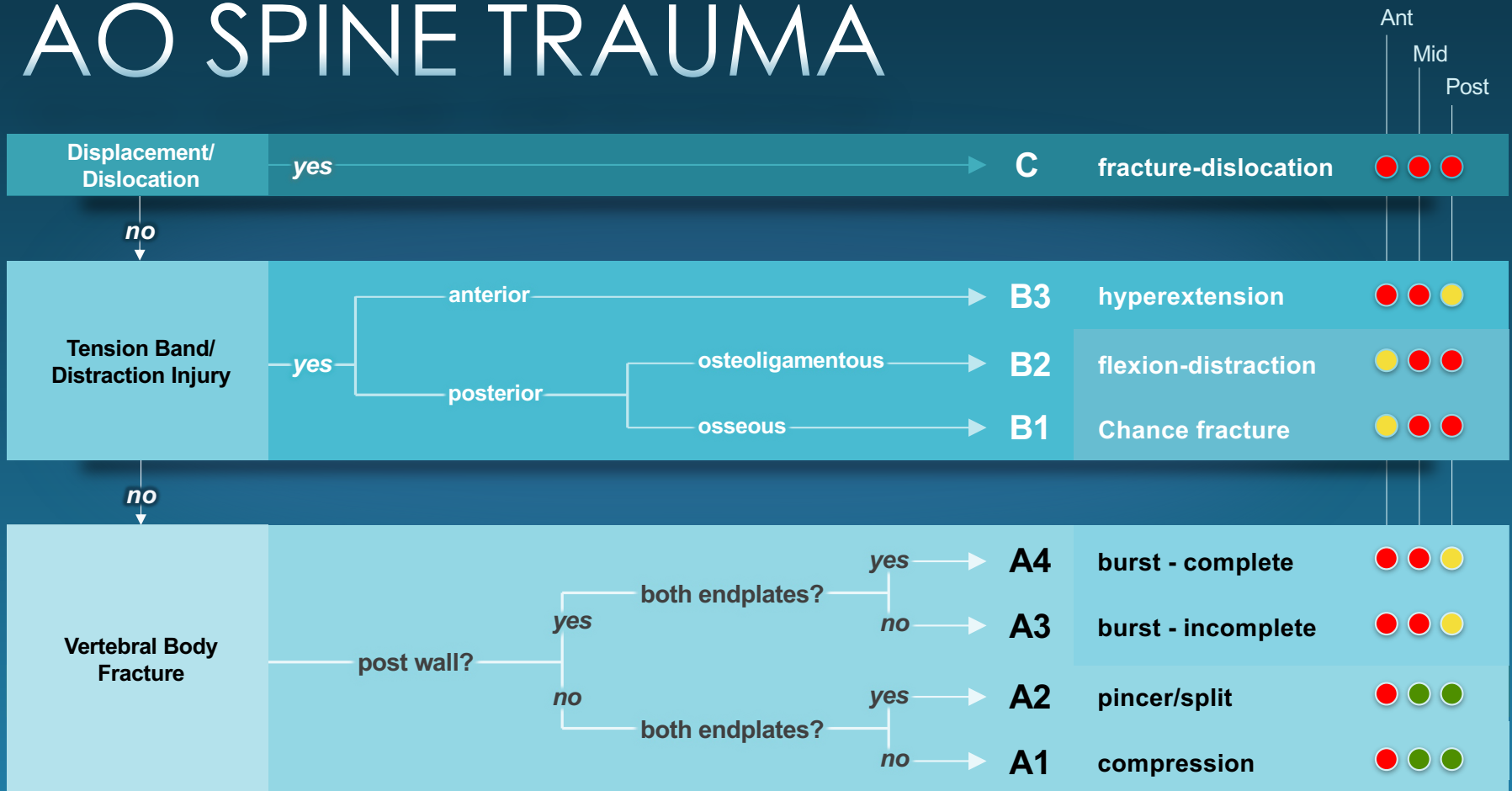
## Compression Fx

<i>Failure</i>	Anterior column
<i>Force</i>	Flexion
<i>aka</i>	wedge

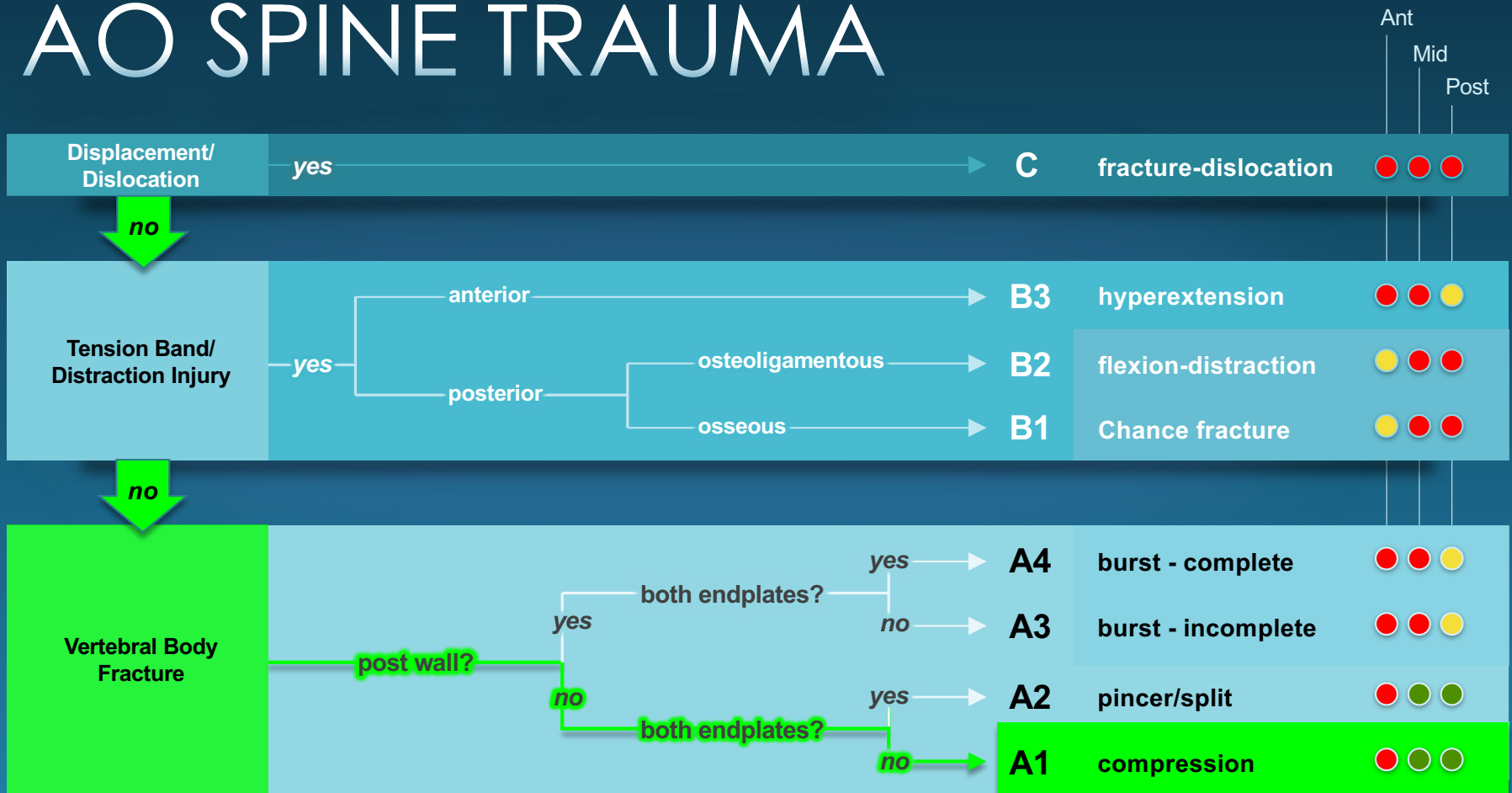




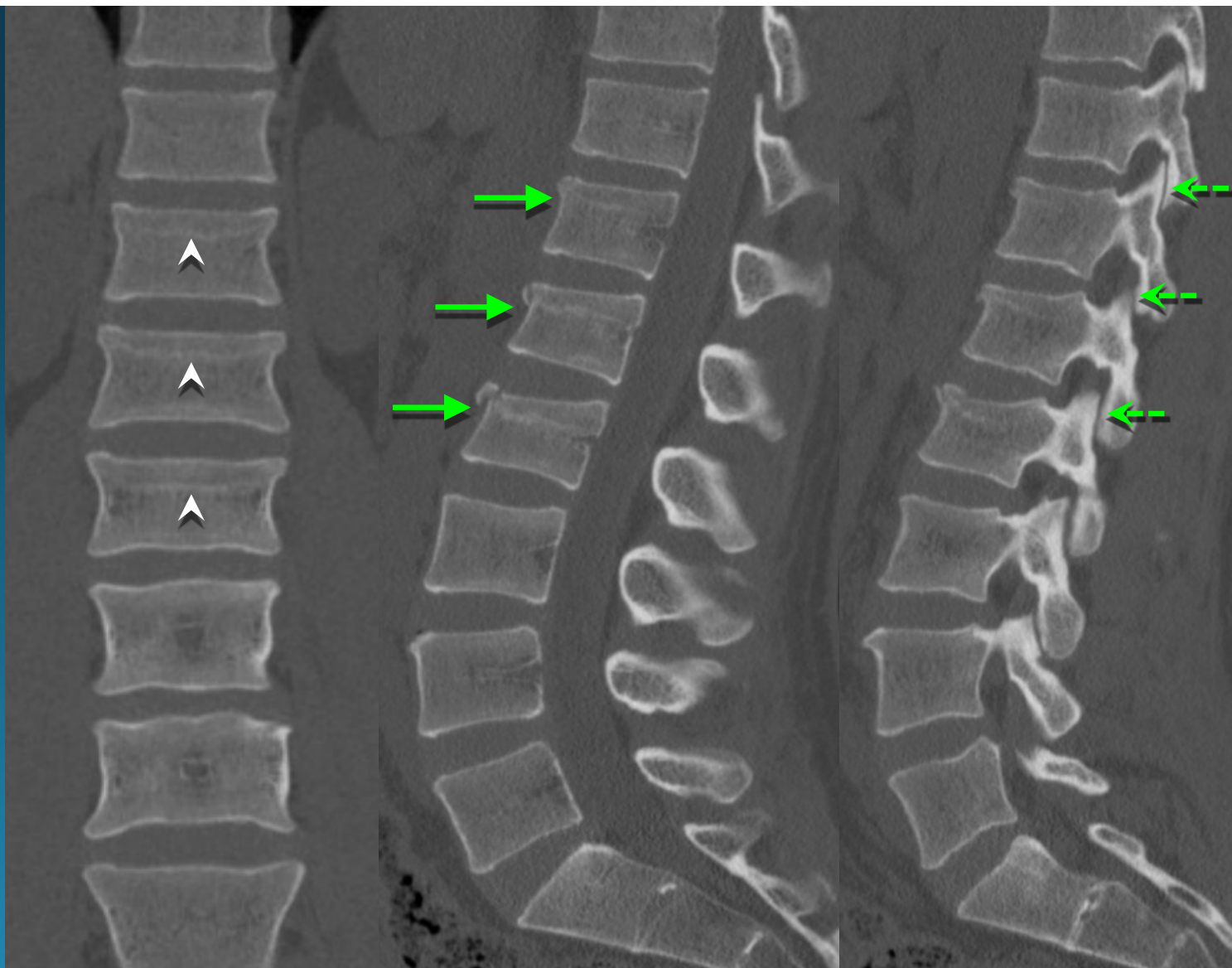
# AO SPINE TRAUMA



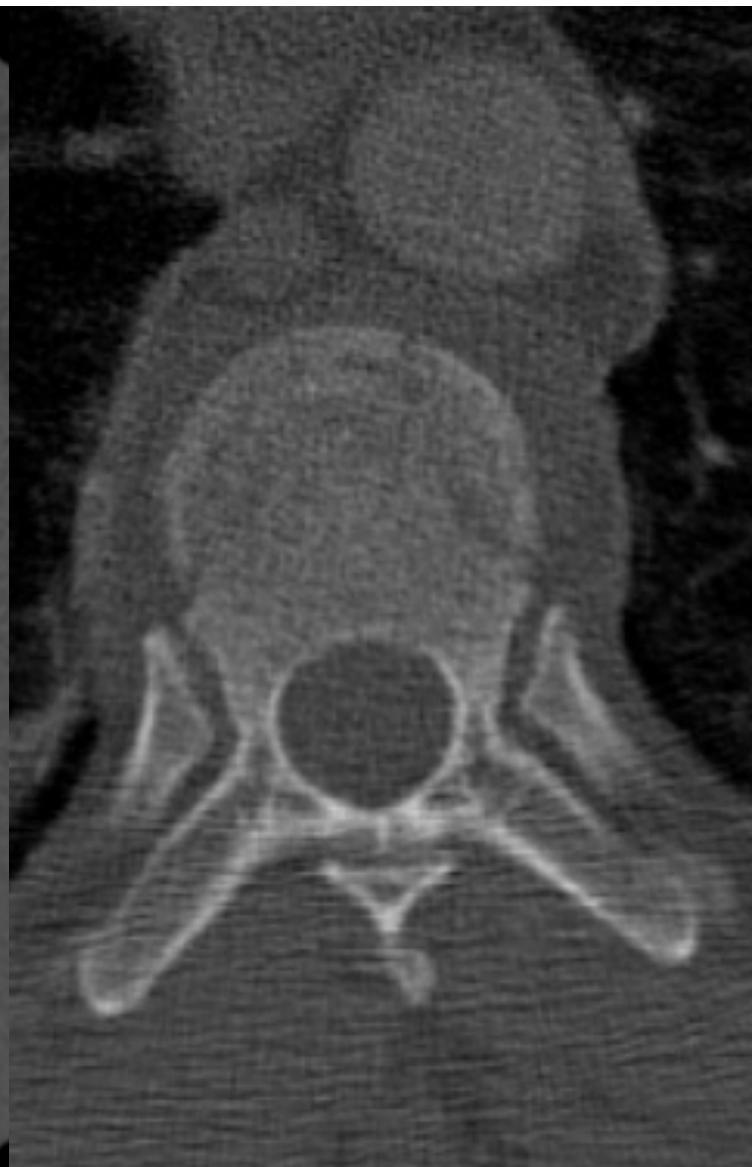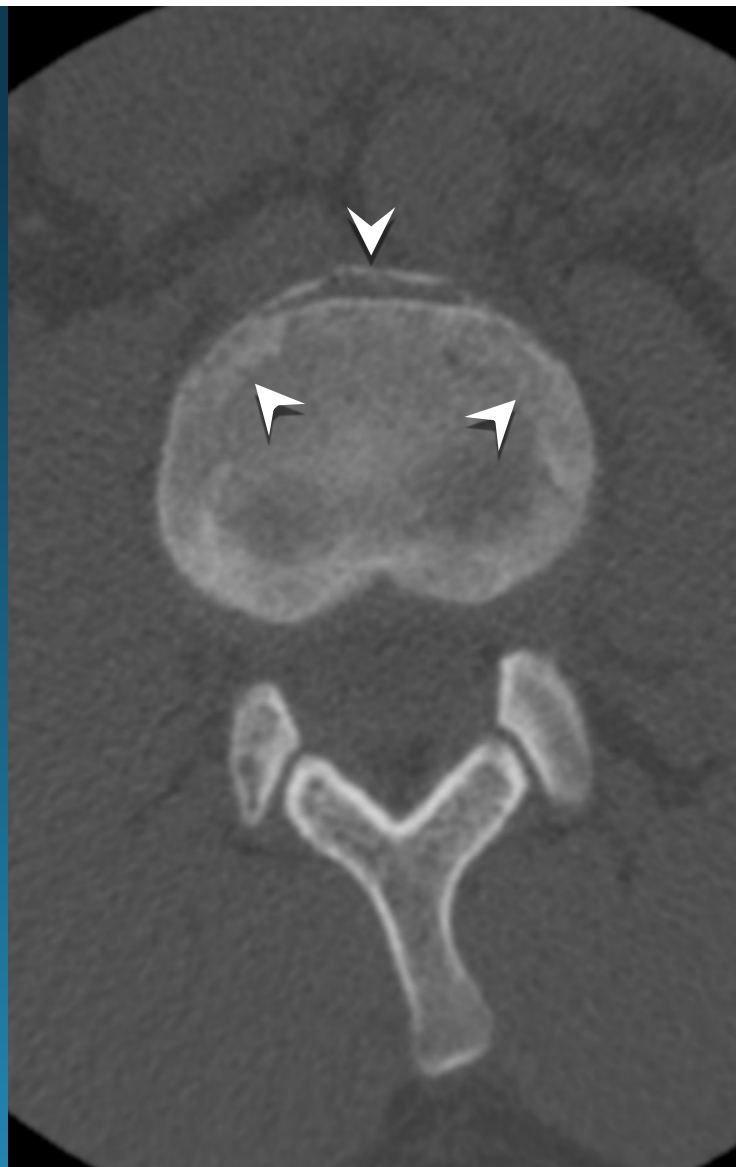# AO SPINE TRAUMA



compression fractures  
(A1)



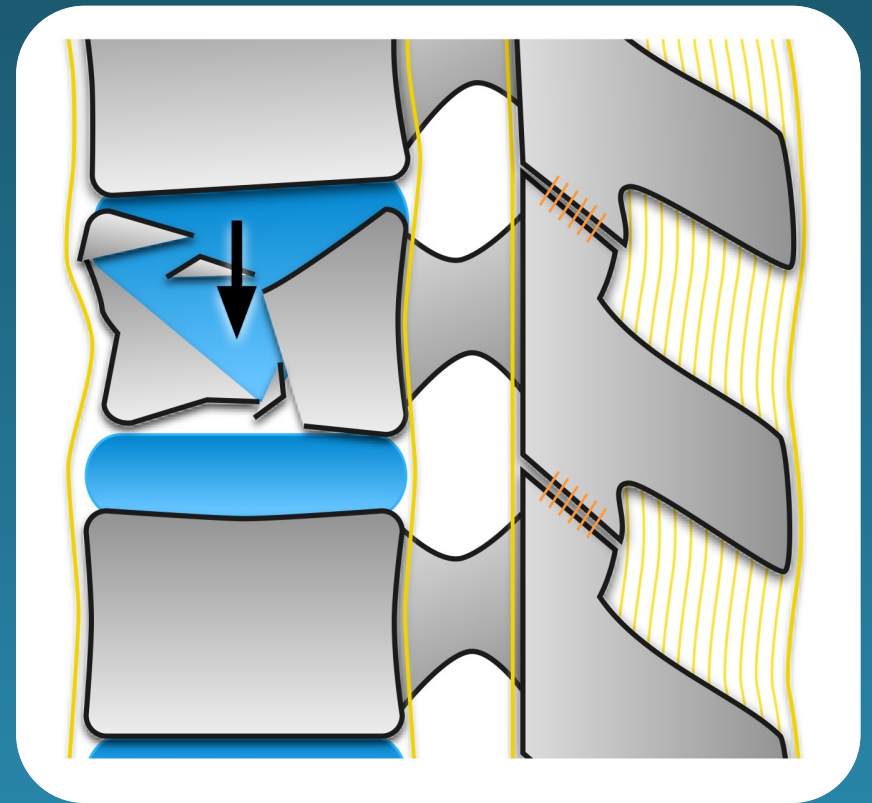
compression fractures  
(A1)



**Except...**

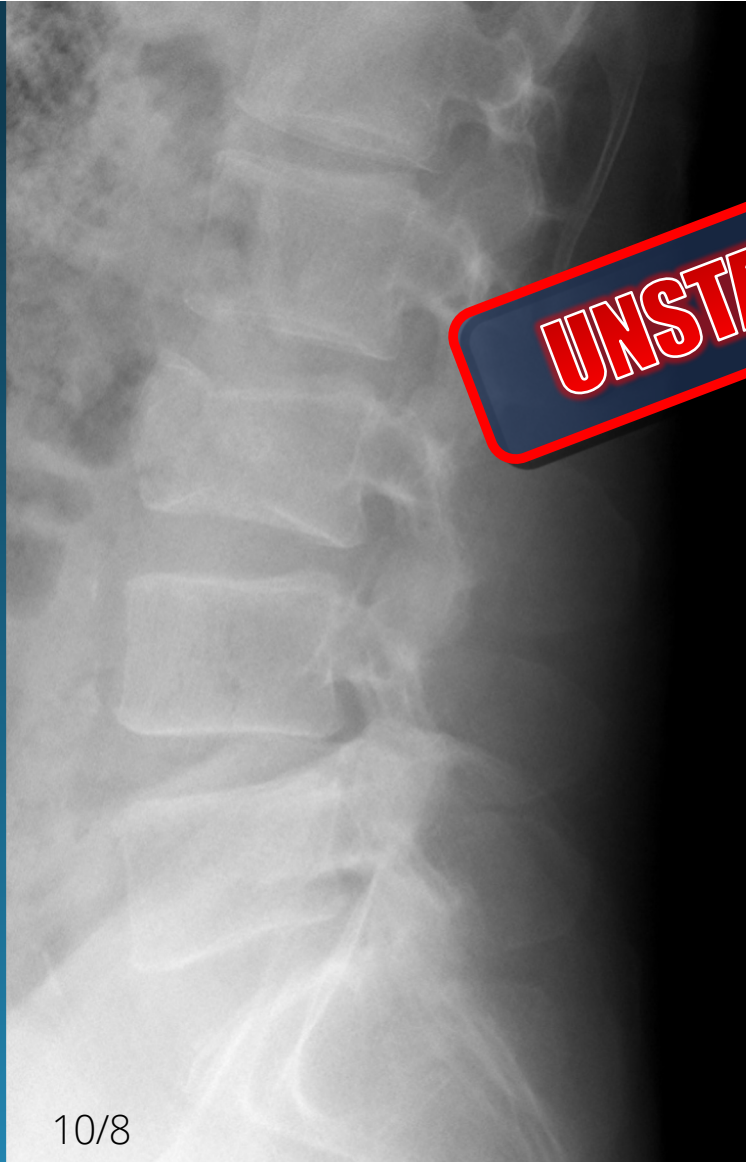**Unstable Variant :**

- **Pincer Fracture (A2)**
  - coronal body fx with disc herniation and loss of support for upper vertebrae
- **Severe wedge impaction** with  $>$  50% anterior vertebral height loss\*
  - look closely for facet separation, subtle retropulsion (e.g. flexion-distraction or burst fx)

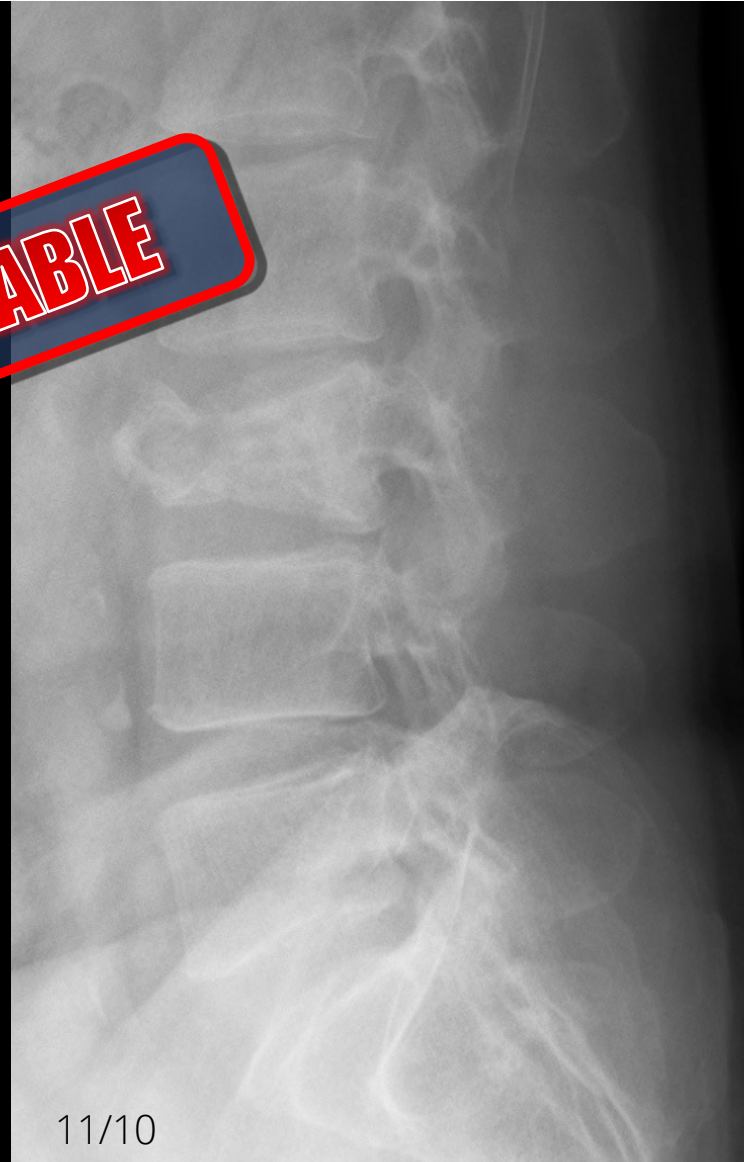


pincer fracture (A2)

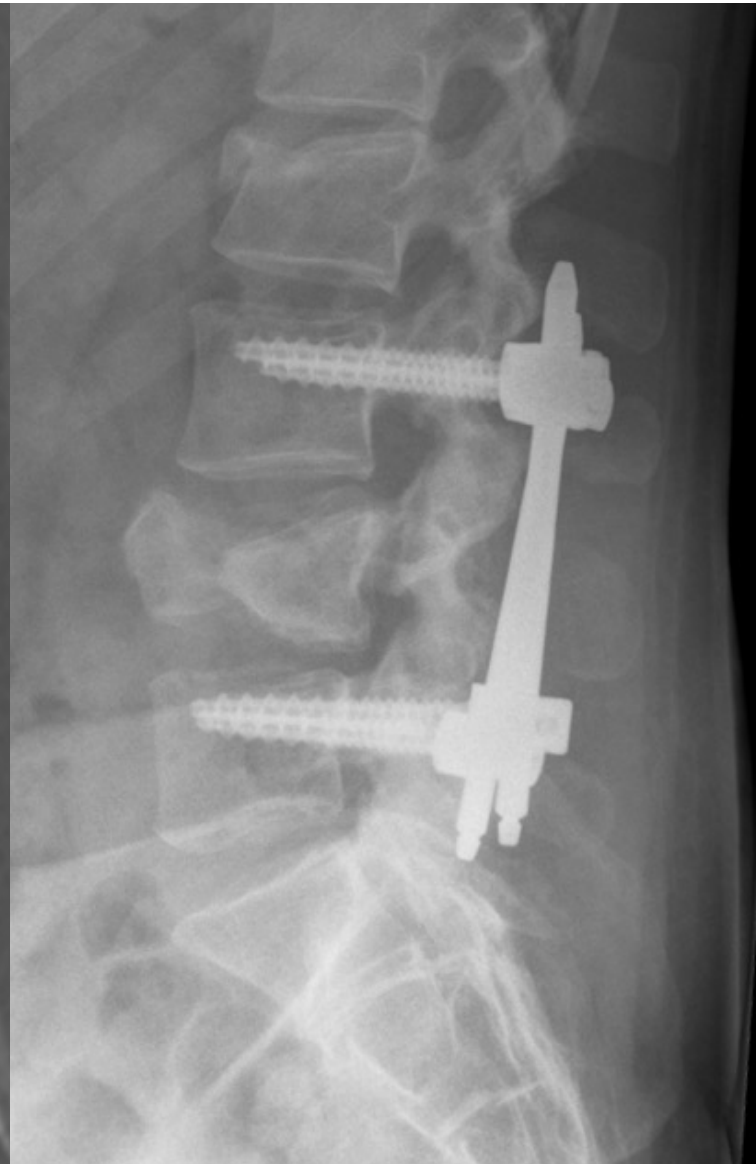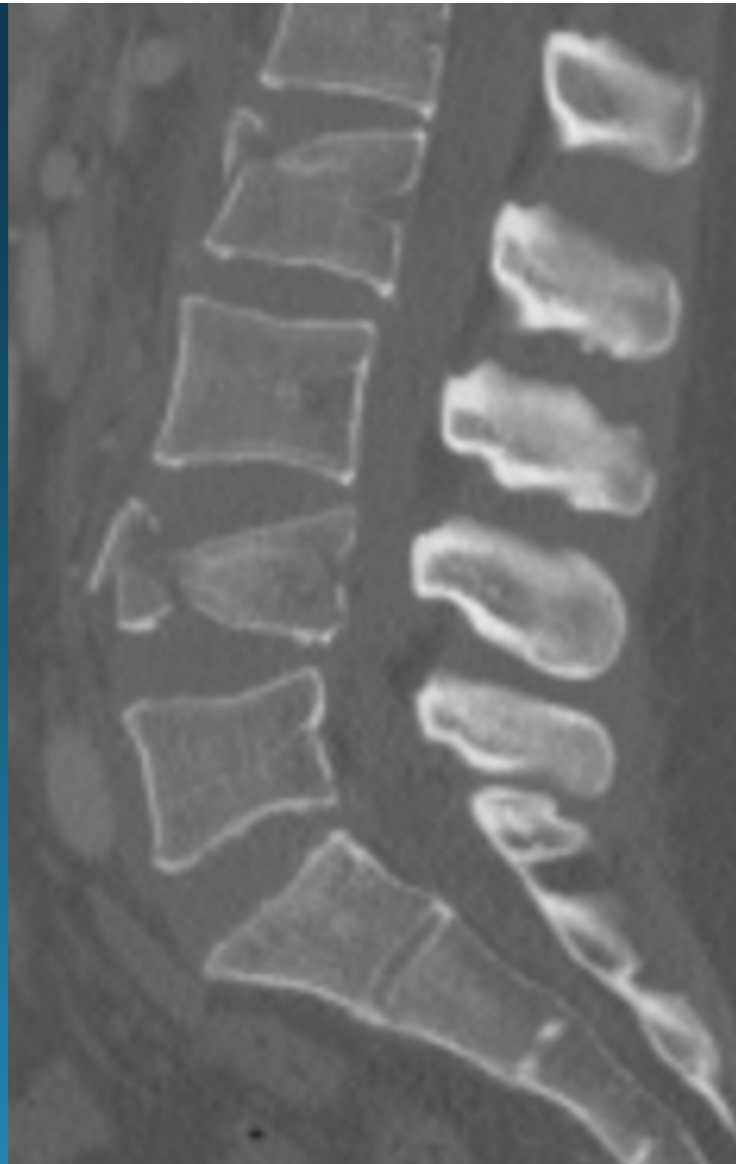
- coronal fx unable to support load



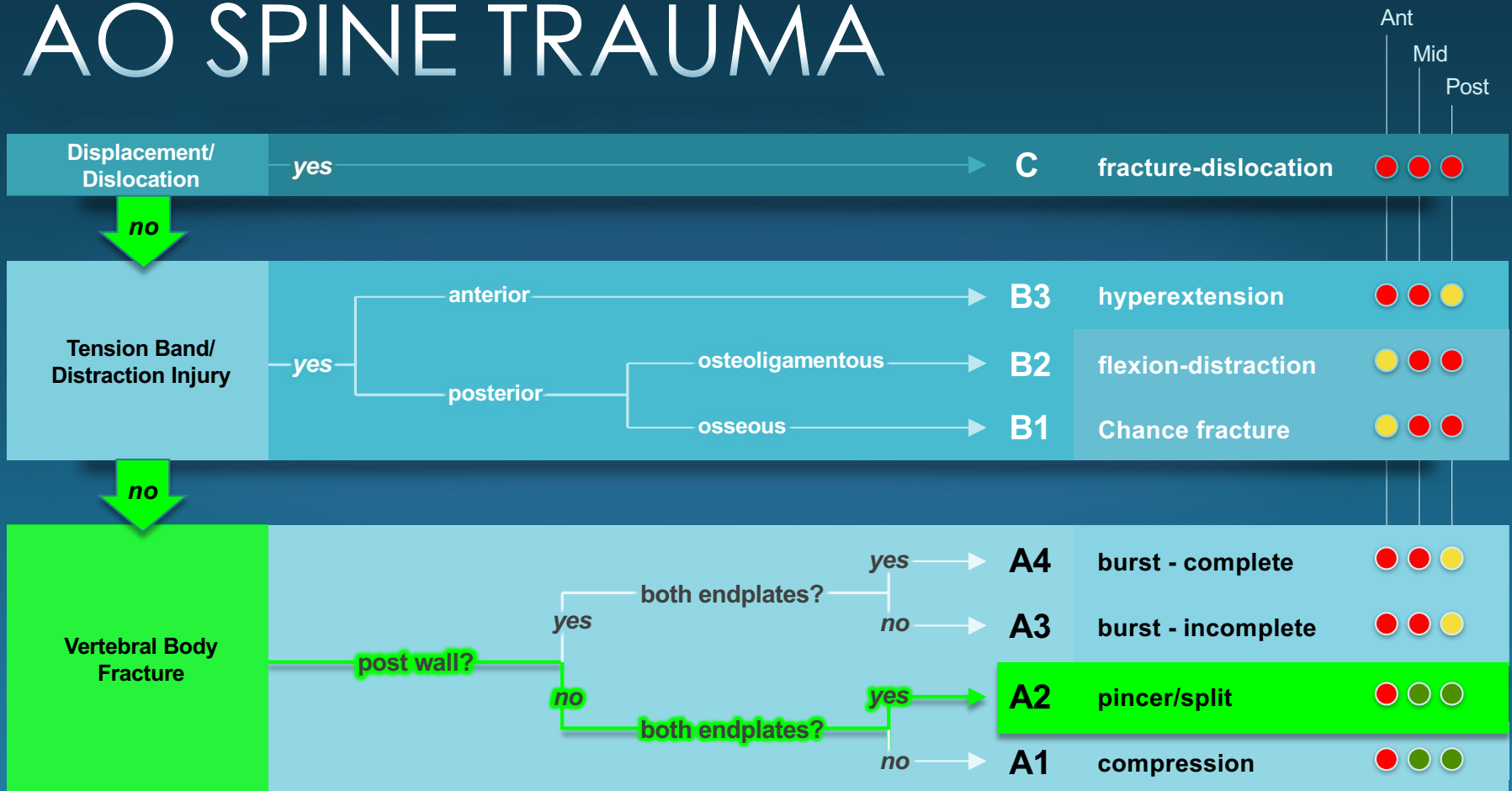
**UNSTABLE**



pincer fracture (A2)



# AO SPINE TRAUMA





# T/L SPINE TRAUMA

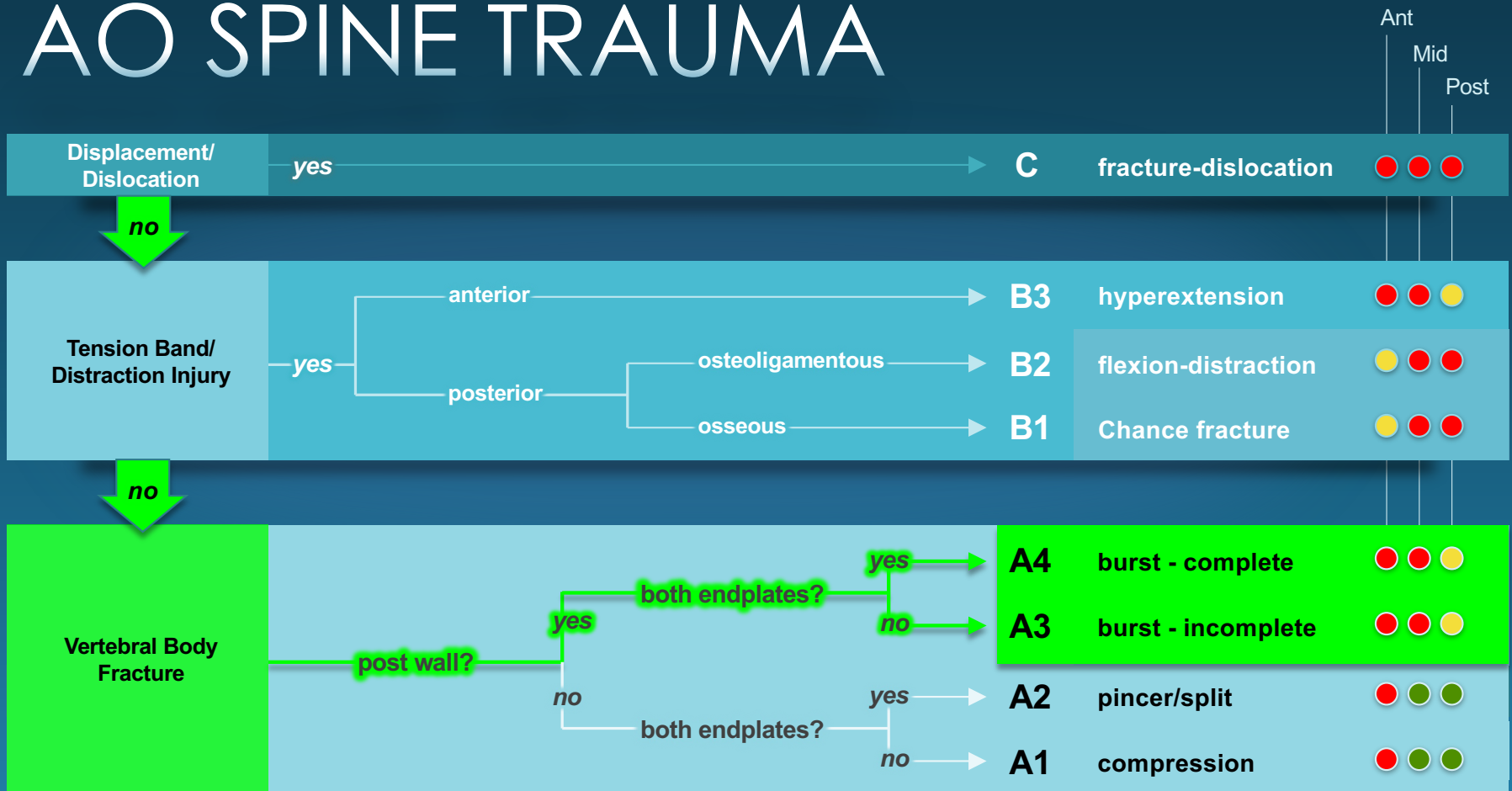
## Burst Fx

<i>Failure</i>	Anterior Middle +/- Posterior
<i>Force</i>	Axial load
<i>Types</i>	Complete vs. incomplete

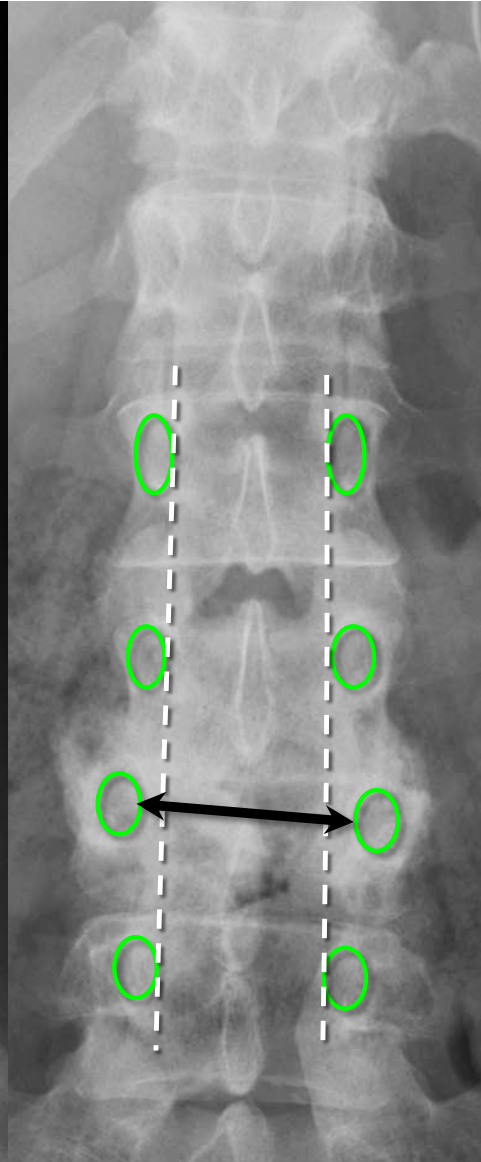
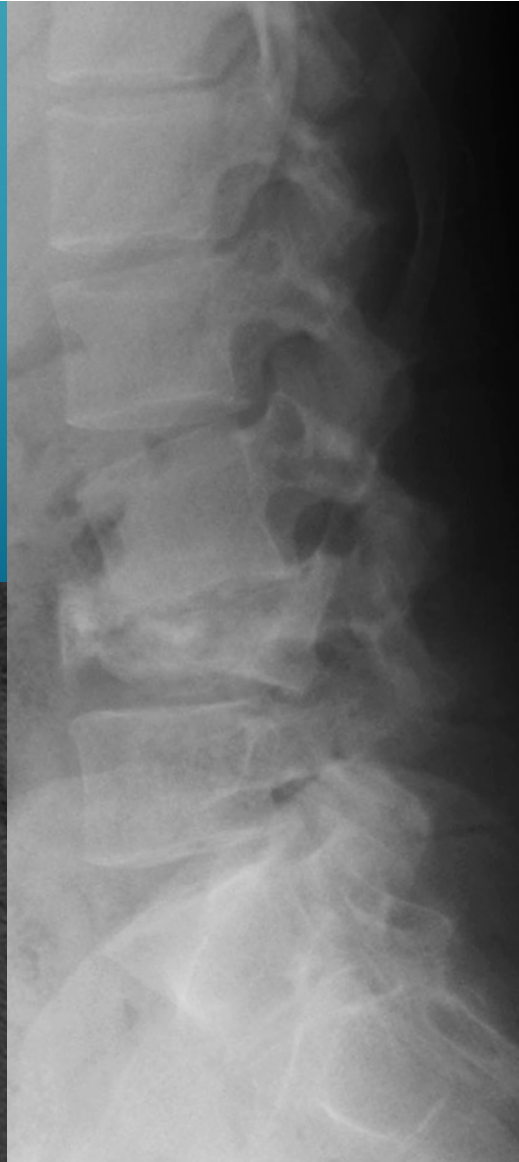
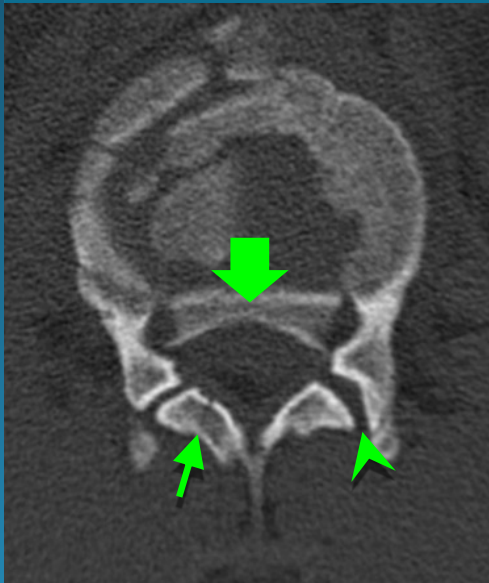



**UNSTABLE**

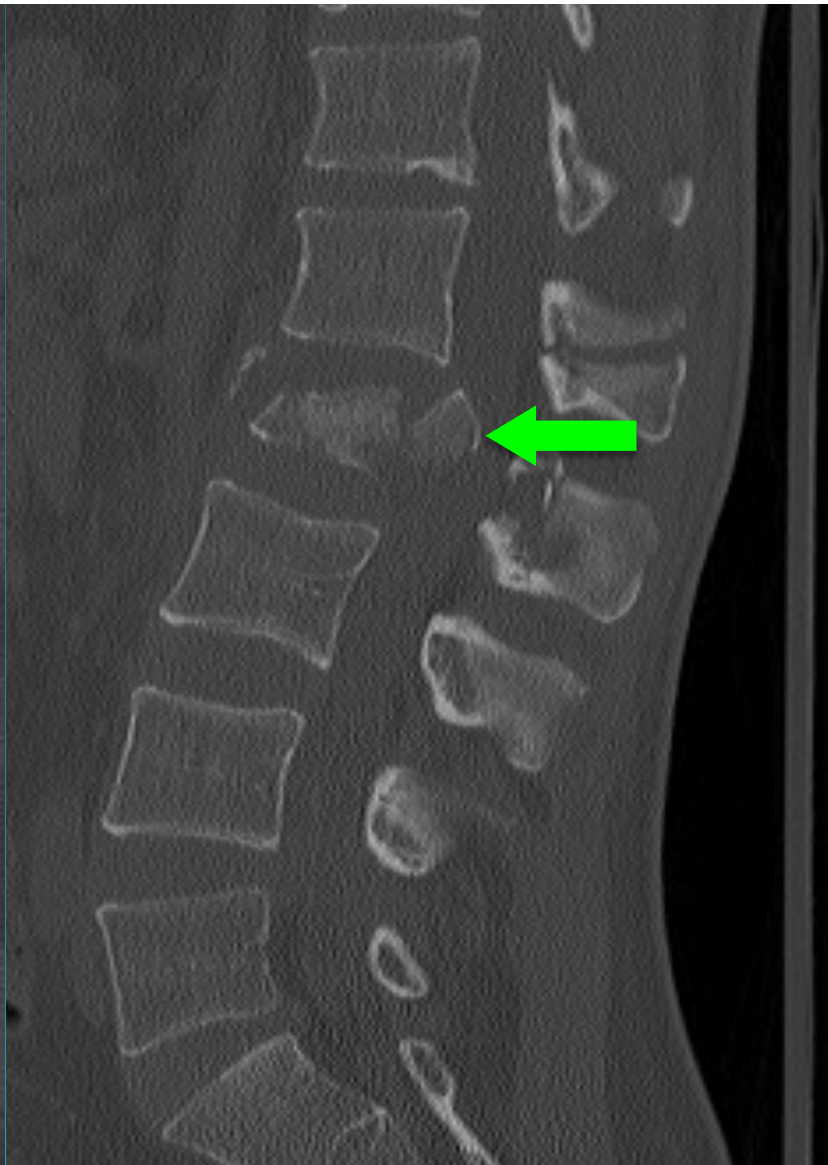
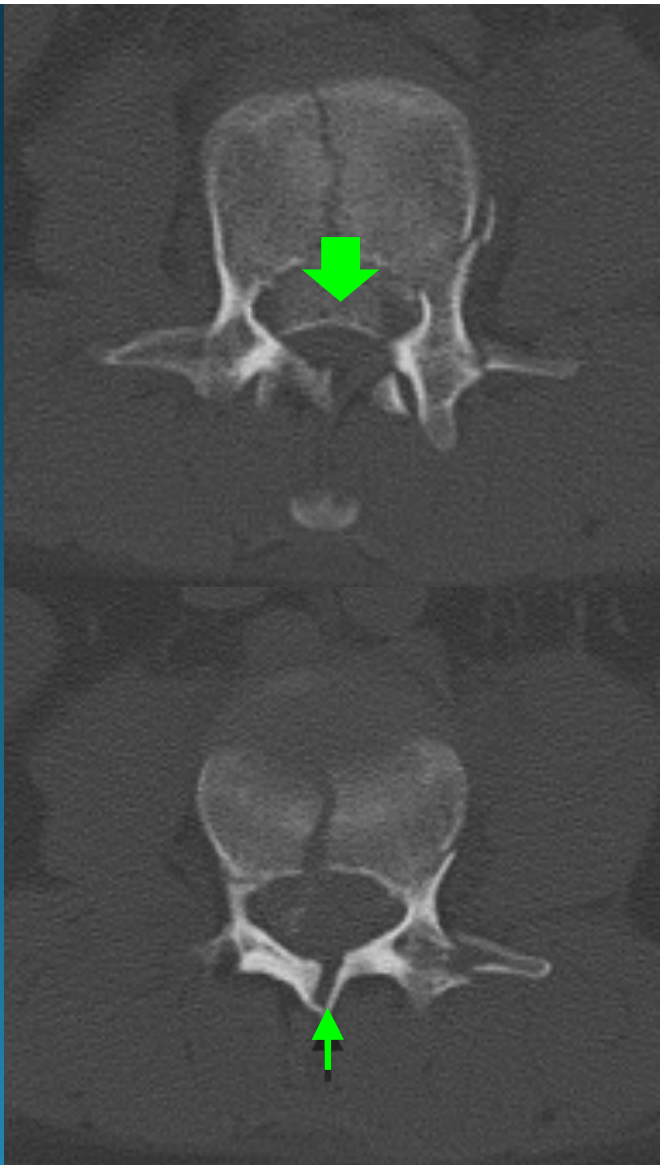
# AO SPINE TRAUMA



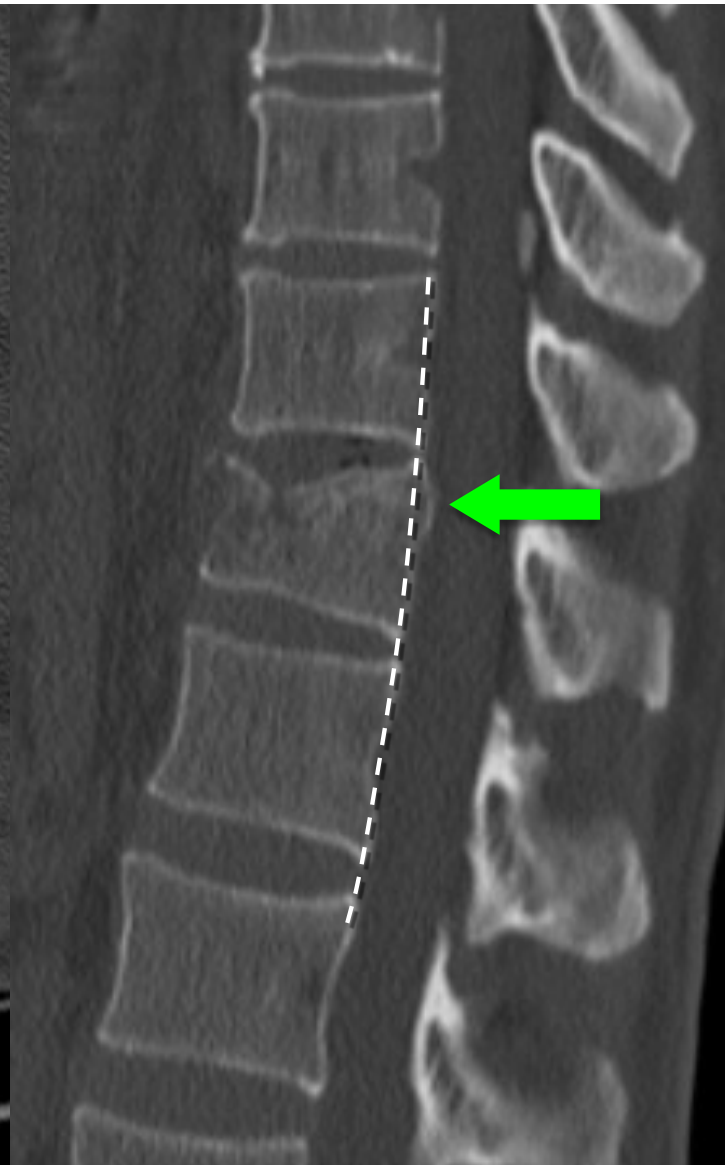
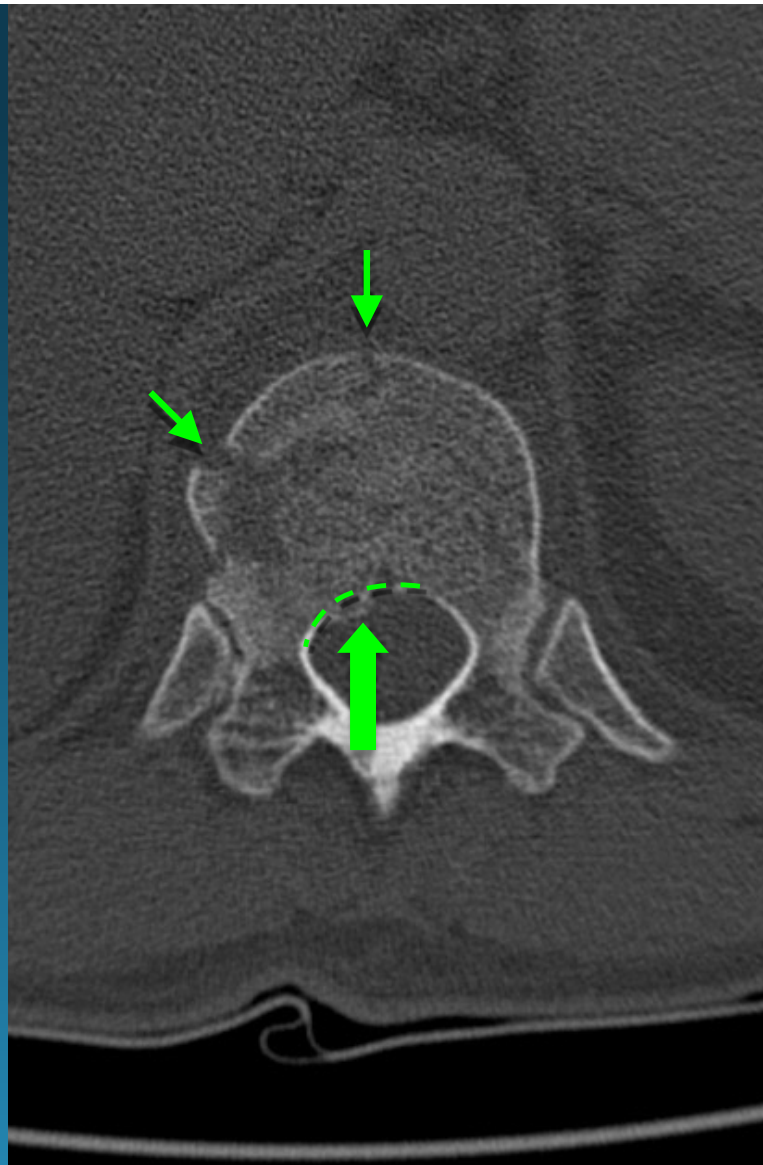
burst fracture



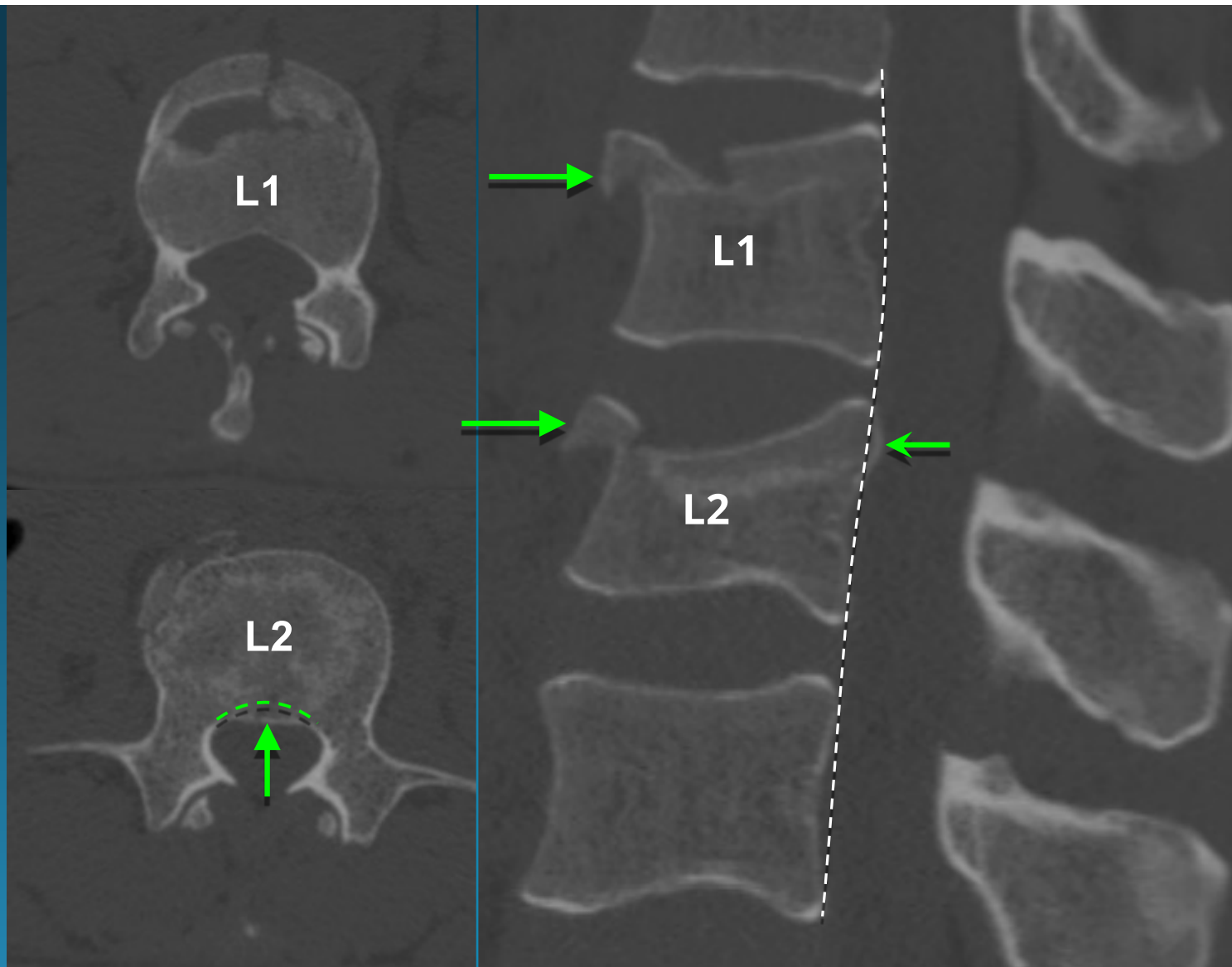
complete burst fracture  
(A4)

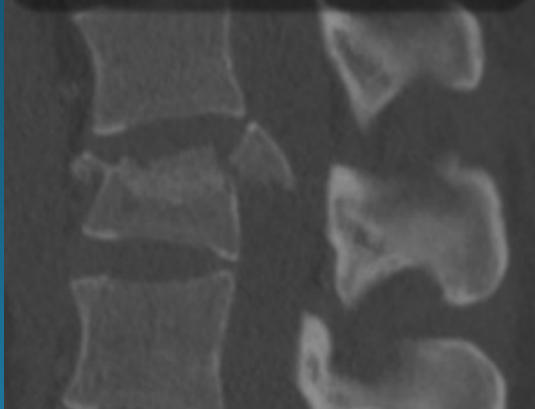
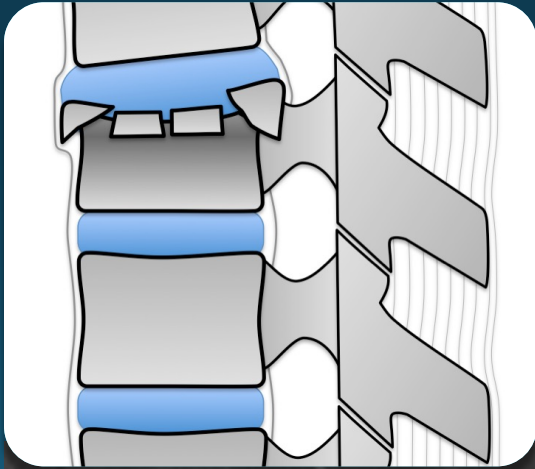


incomplete burst fracture  
(A3)

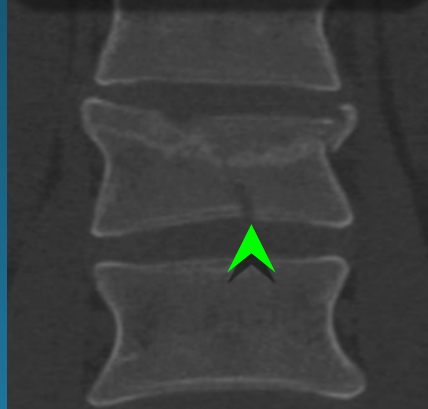



subtle L2 burst fracture (A3)  
L1 compression fracture (A1)

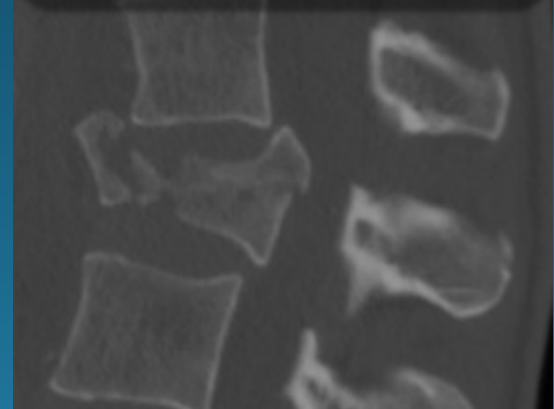
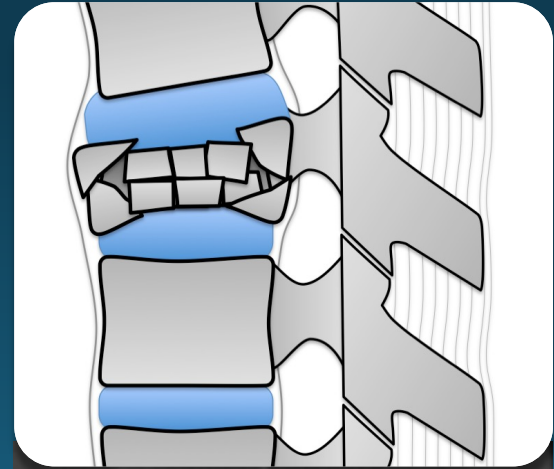




A3



A4

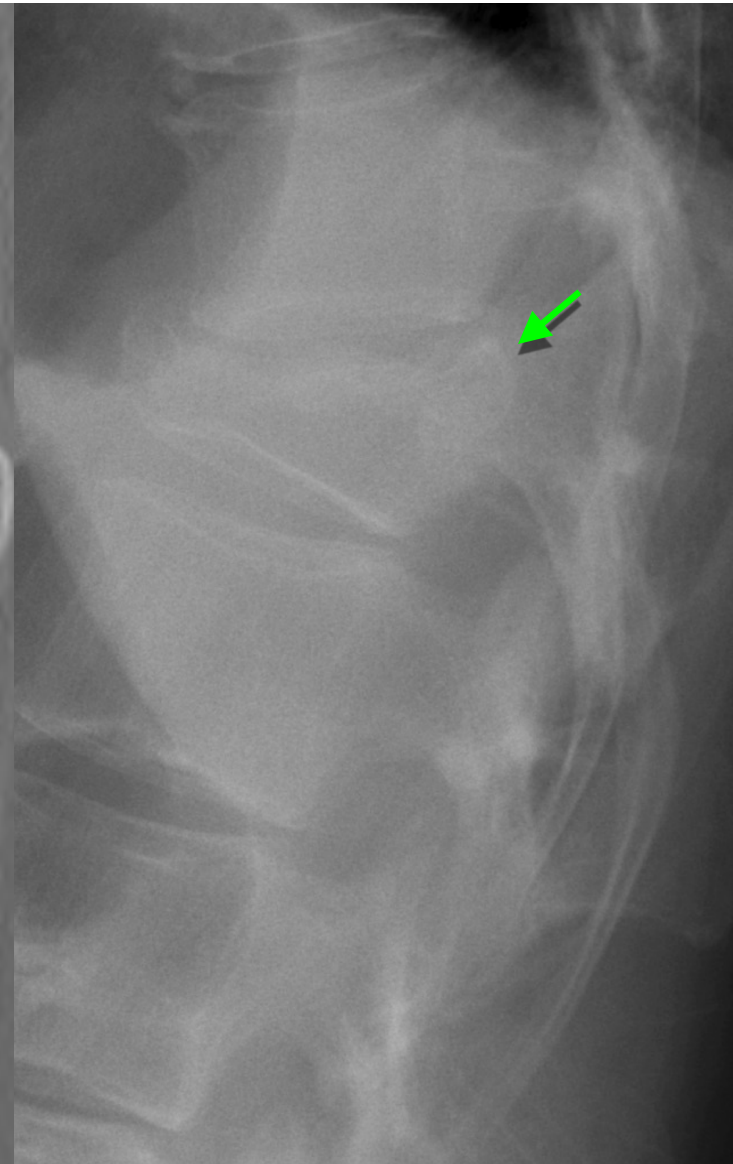
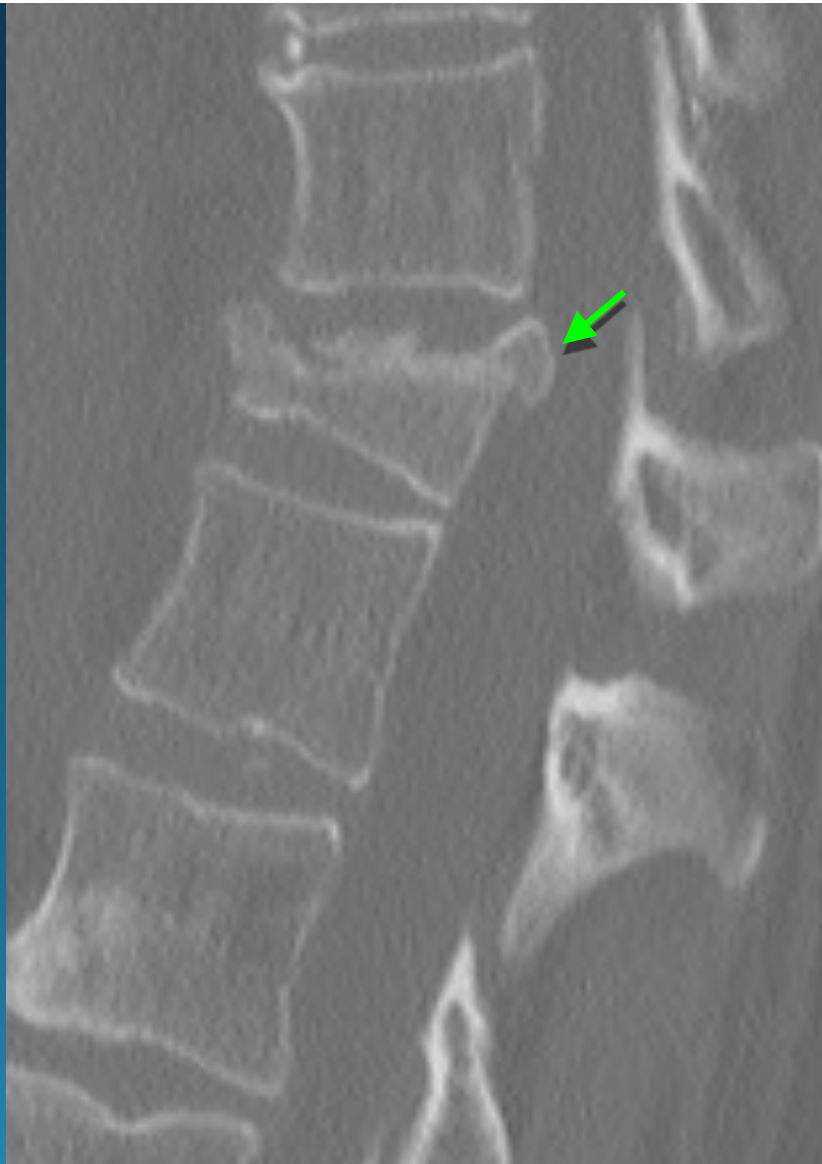

A4

burst fracture subtypes

**burst fracture**

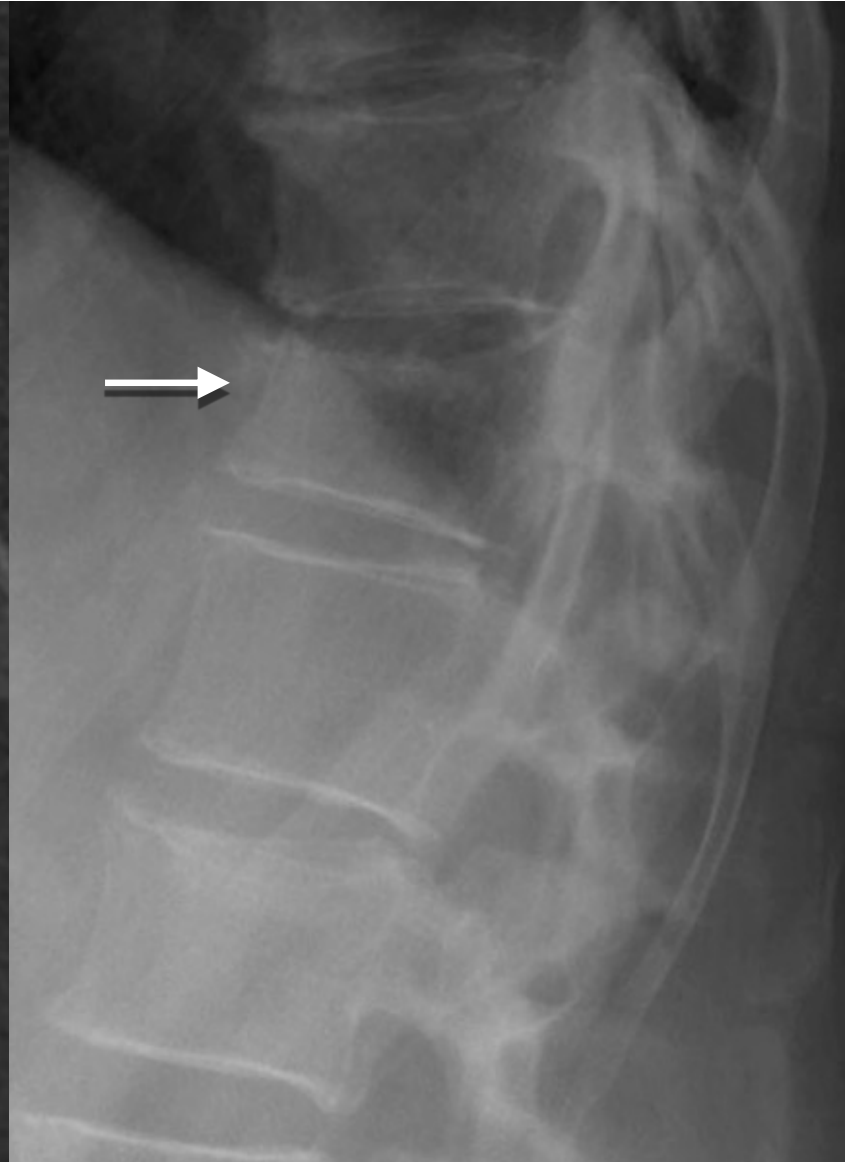
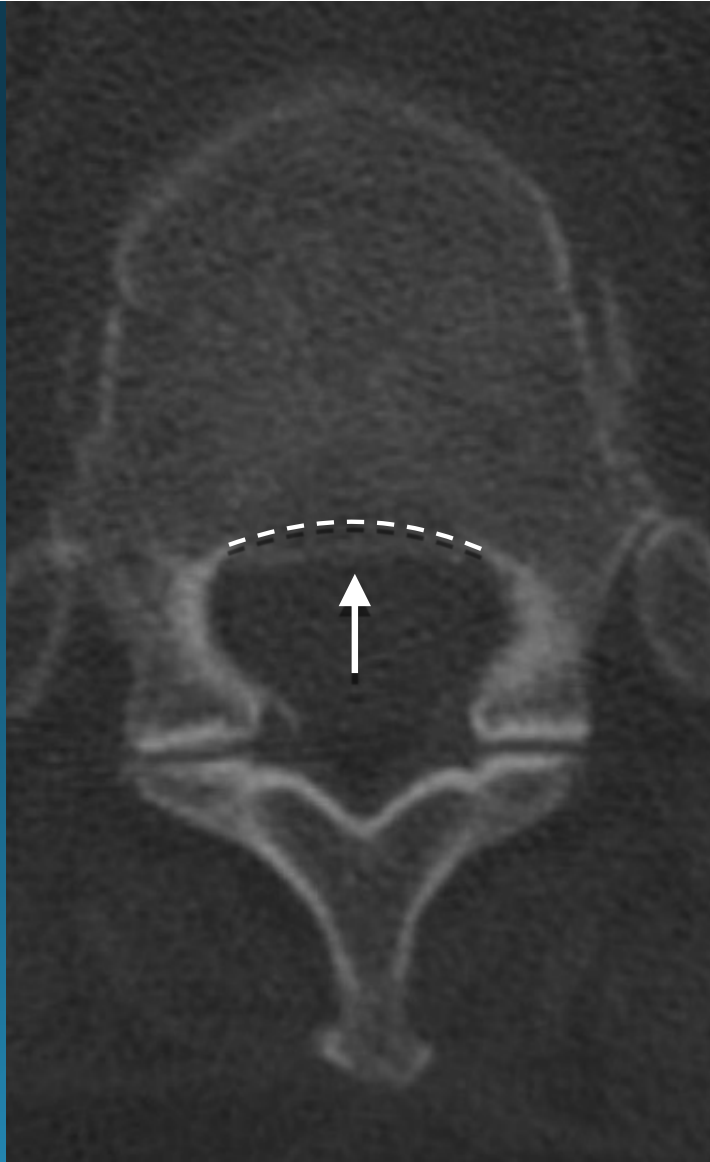
posterior body  
cortex retropulsion  
on XR





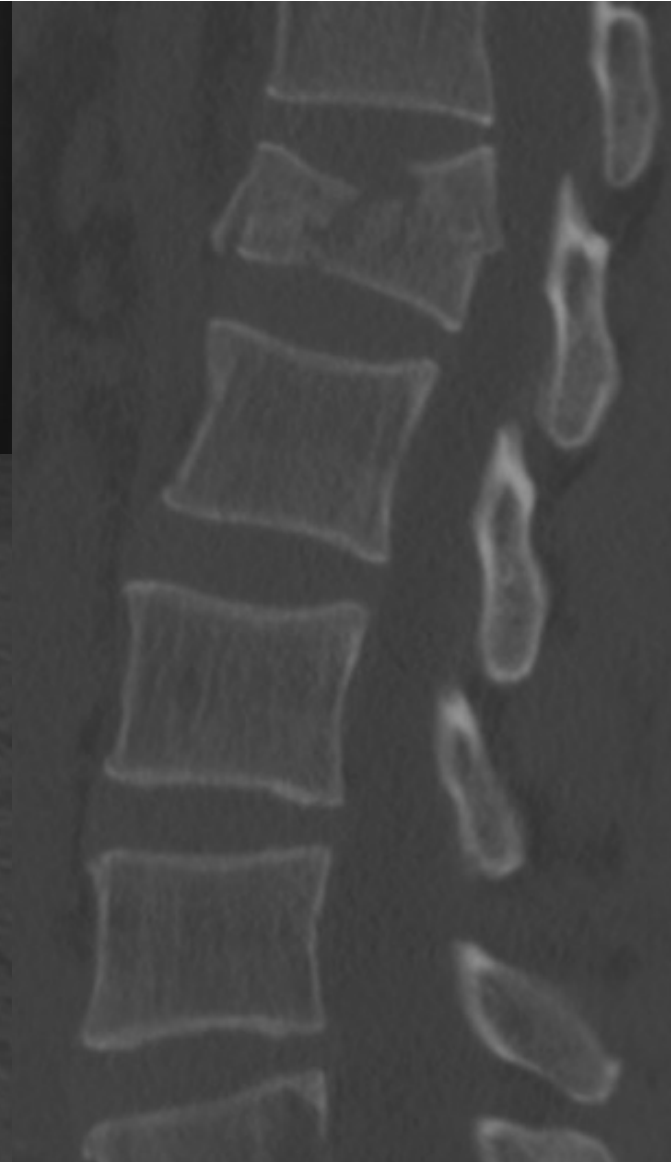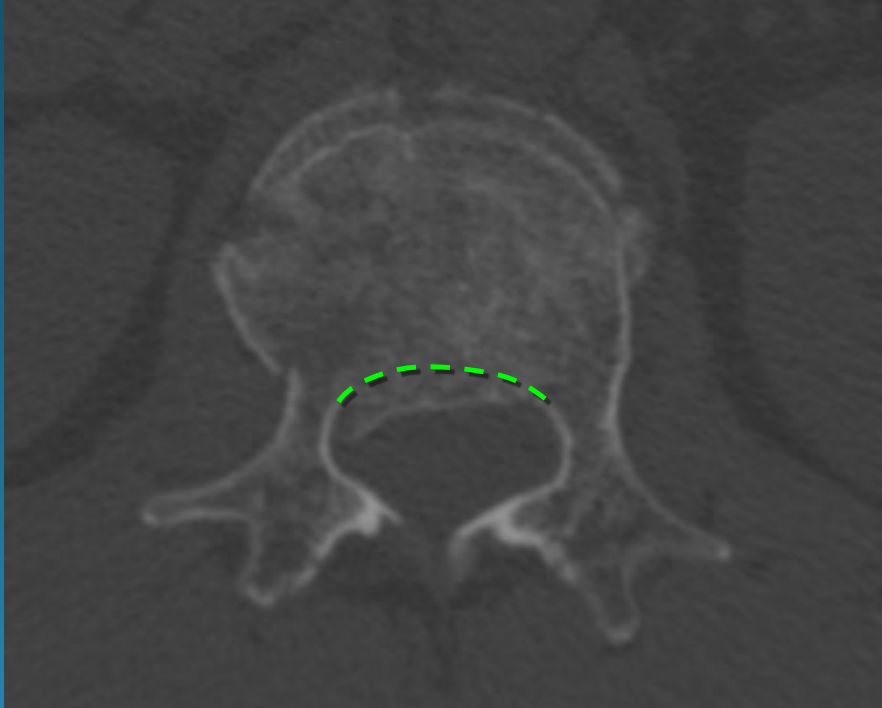
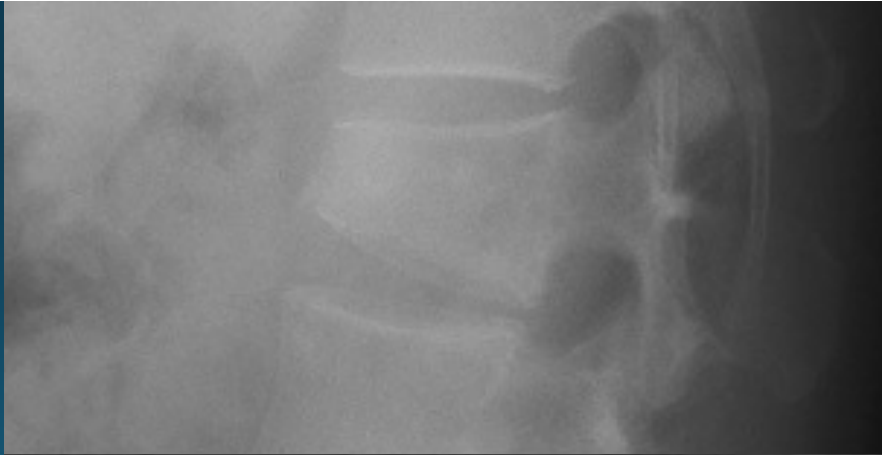
**burst fracture**

posterior body  
cortex obscured by  
ribs on XR



**burst fracture**

posterior body  
cortex retropulsion  
only seen at CT

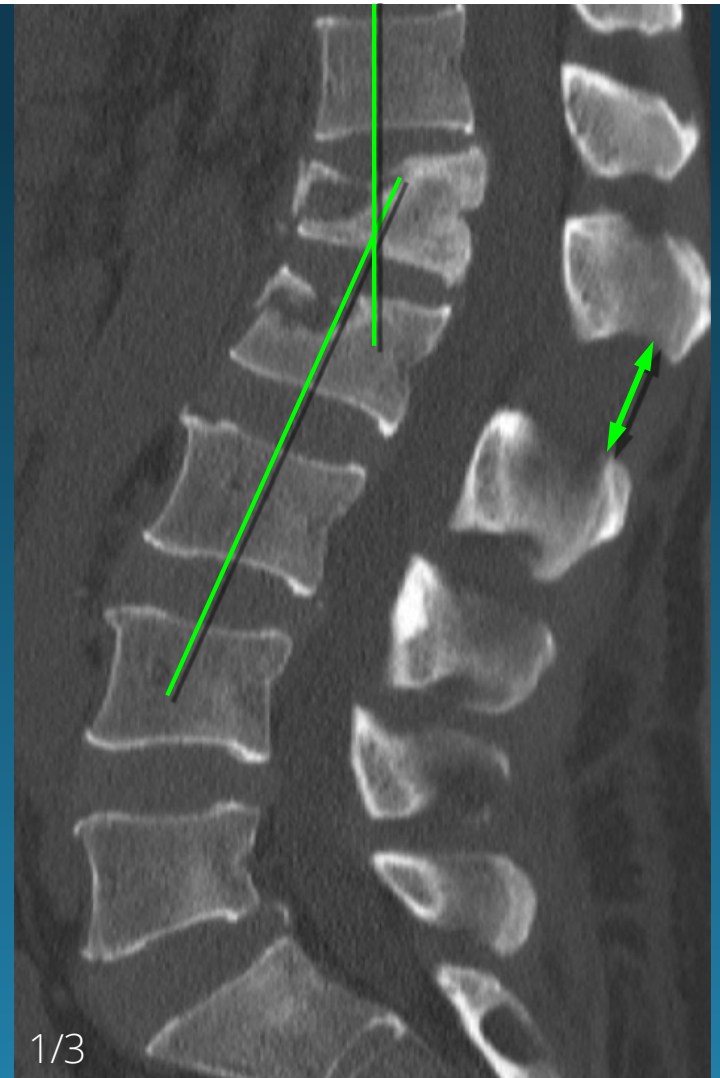
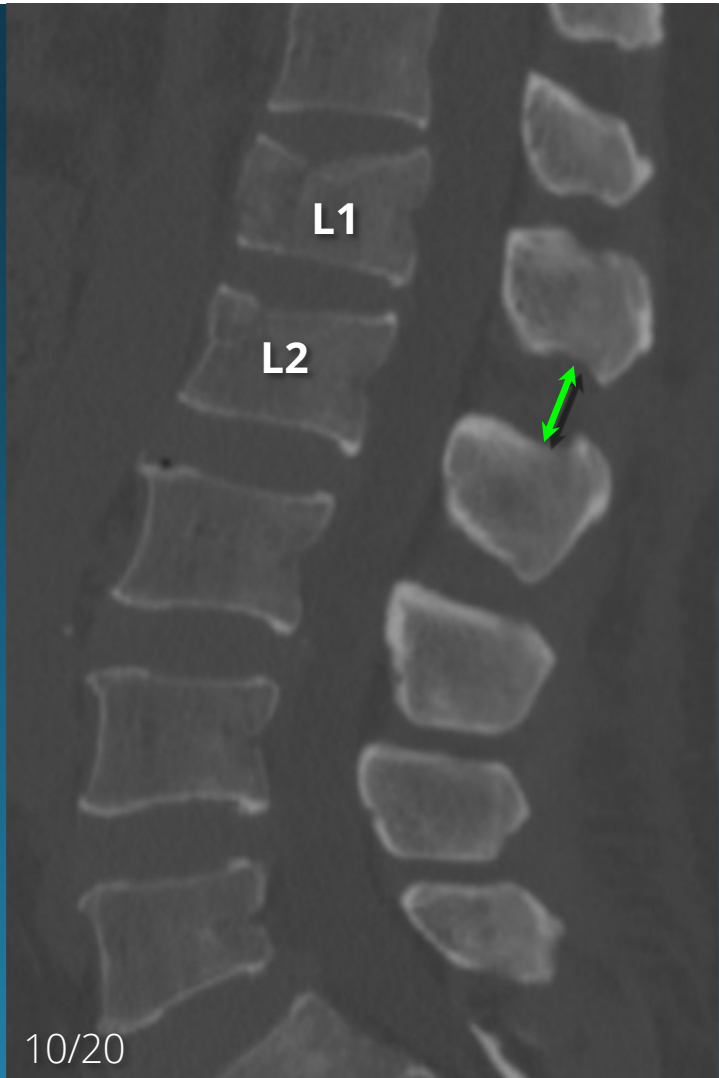


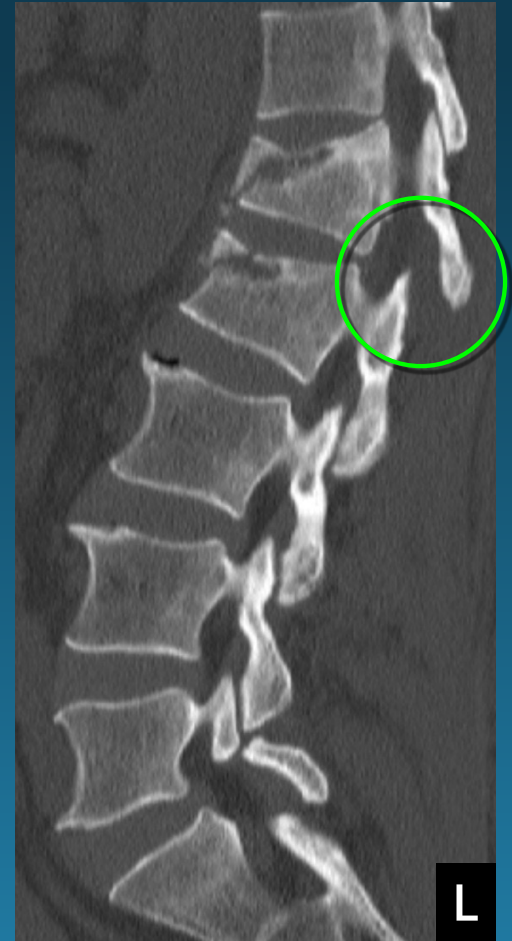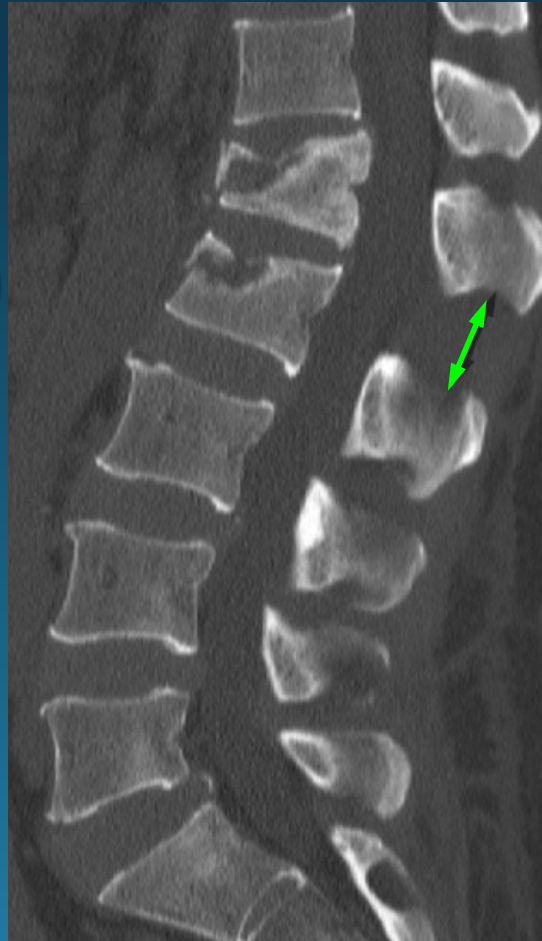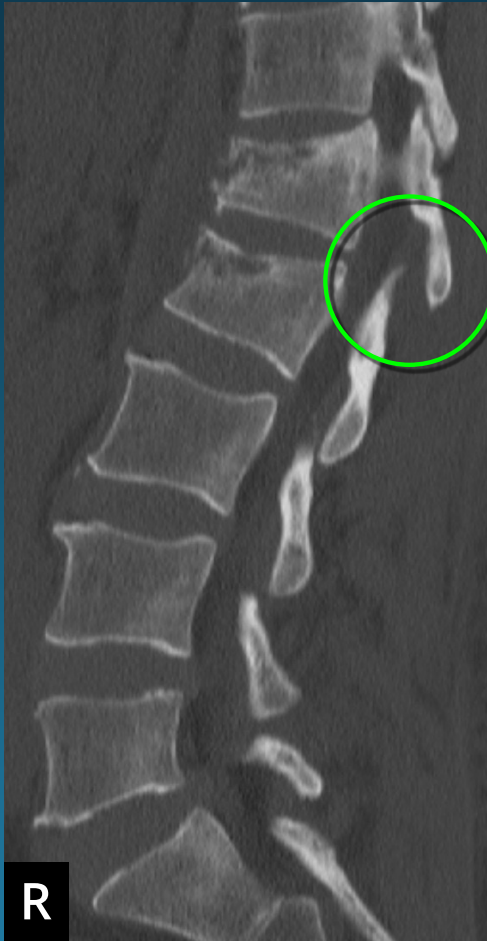# CASE

**Q: What Fracture Type is Present?**

- A) Compression
- B) Burst
- C) Flexion Distraction
- D) Fracture Dislocation
- E) Hyperextension





# T/L SPINE TRAUMA

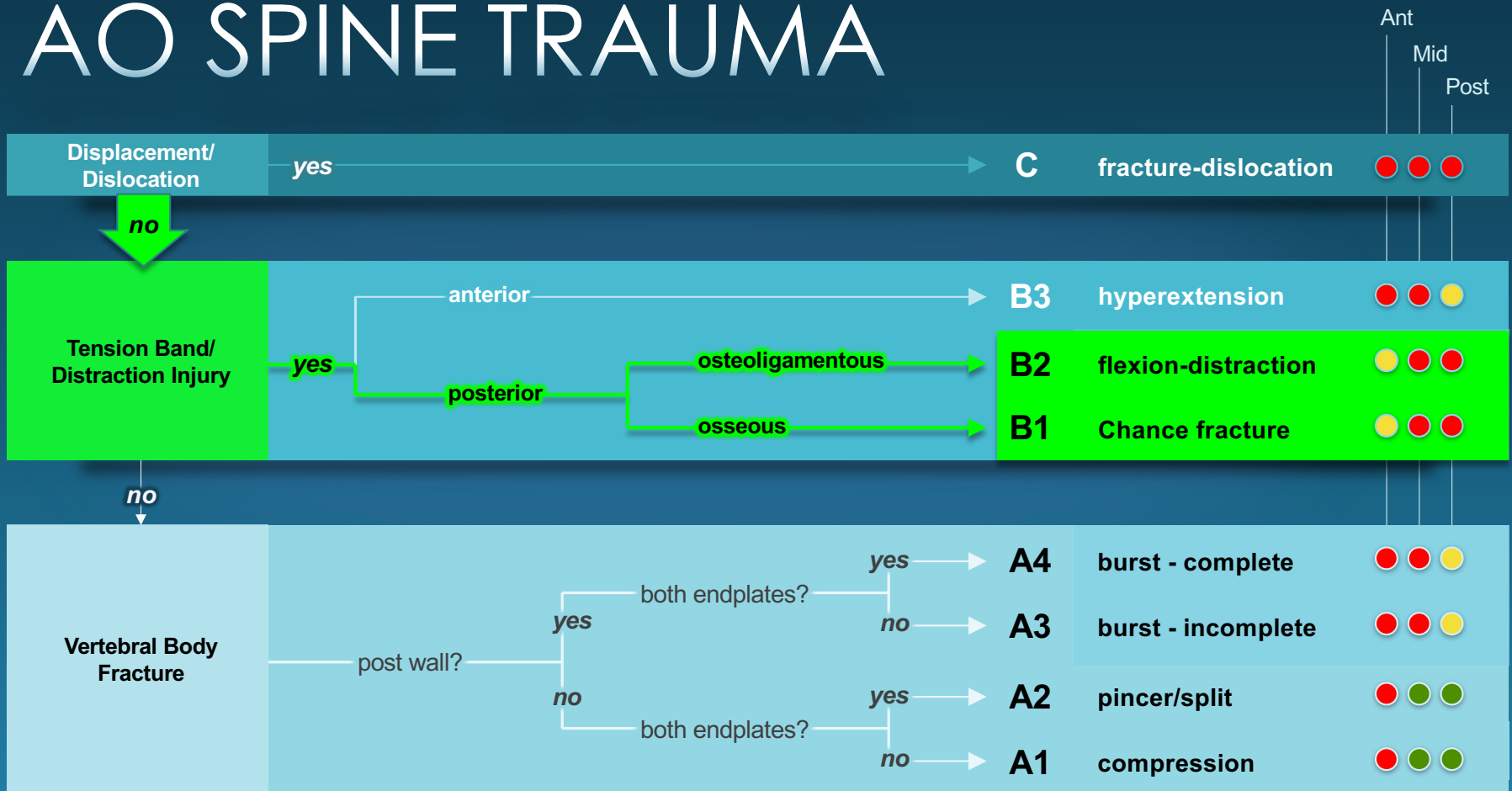
## Chance-type Fx

<i>Force</i>	Flexion & Distraction
<i>Failure</i>	Posterior Middle ± Anterior
<i>Types</i>	Bony vs Ligamentous
<i>aka</i>	Seat belt Flexion-distraction
<i>Neuro</i>	Usually intact



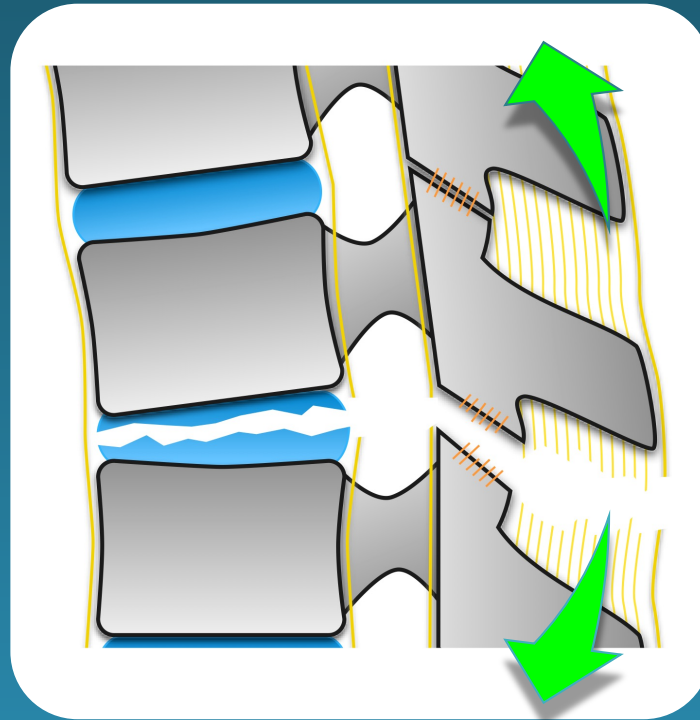
**UNSTABLE**

# AO SPINE TRAUMA

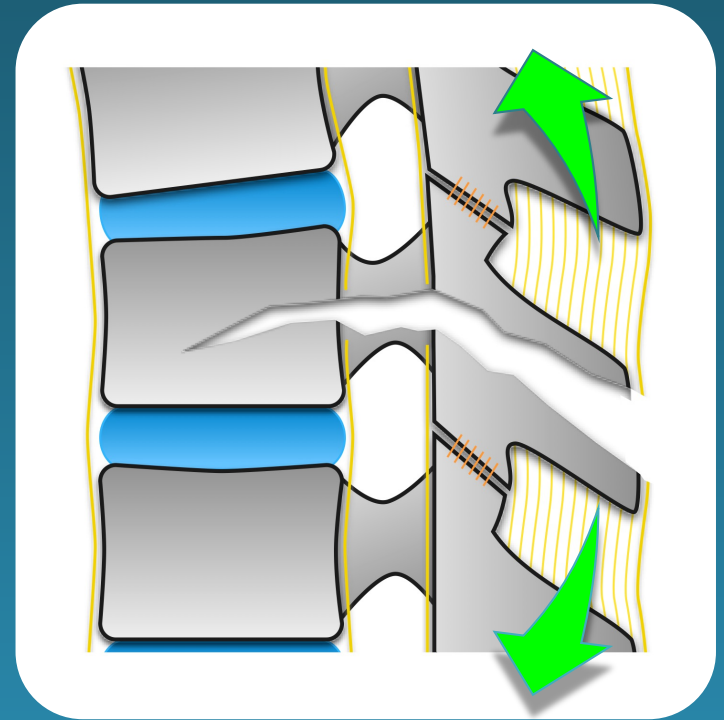


flexion distraction

ligamentous injury (B2)



bony Chance fracture (B1)

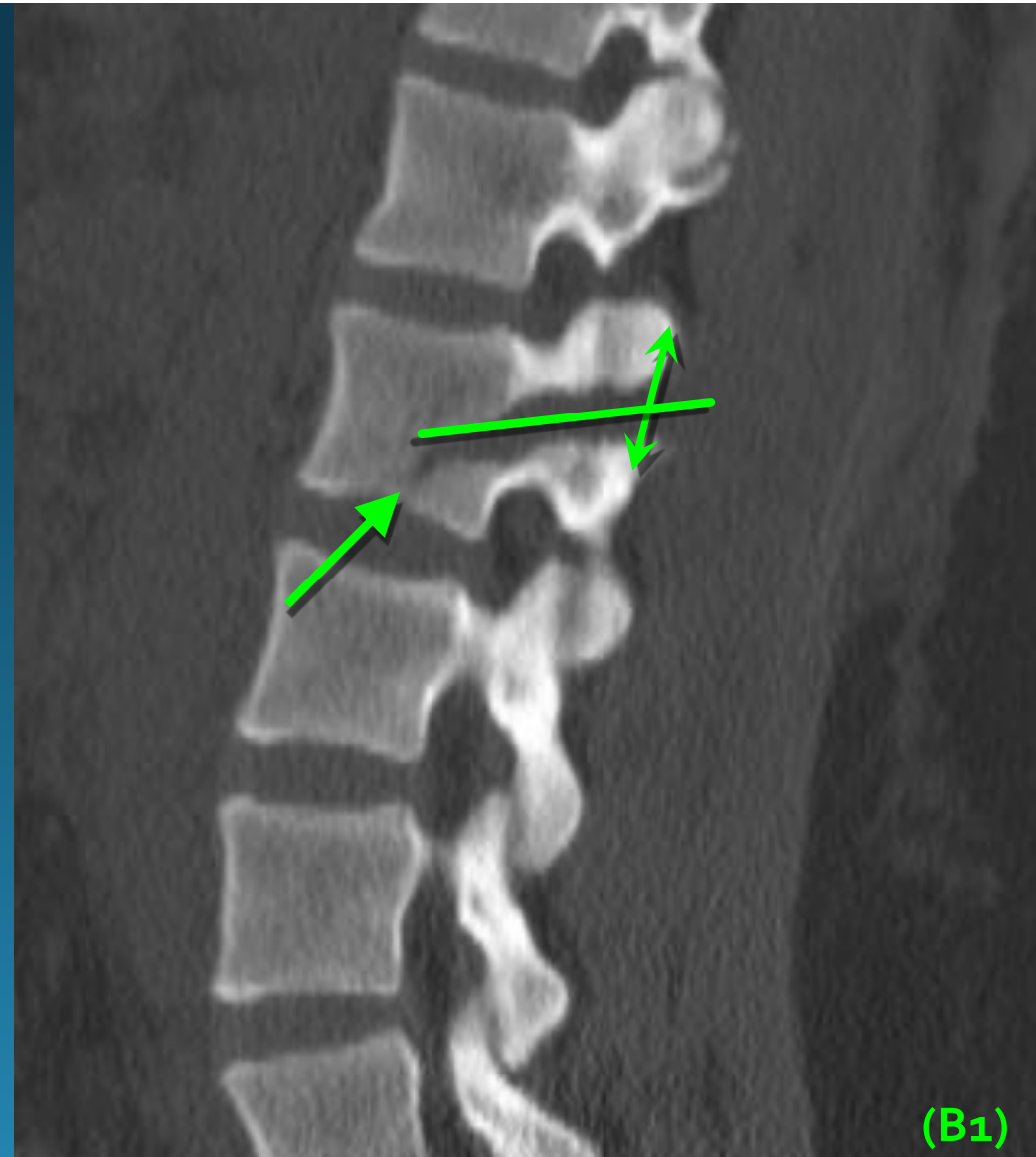



# CHANCE FXS

## CT – Sagittal

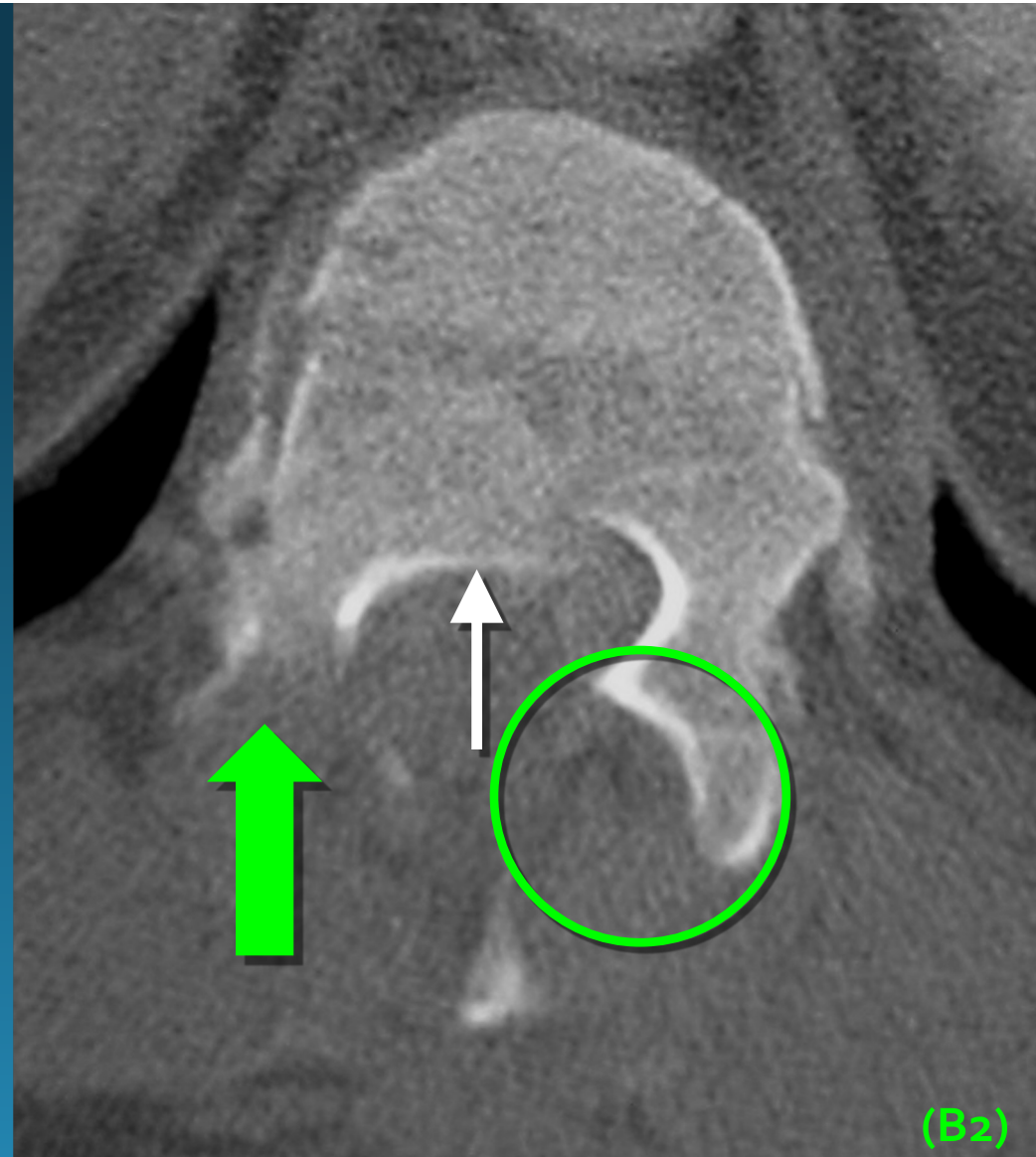- Wide interspinous distance
- Transverse pedicle fracture
- Fracture may propagate into vertebral body
- Separation of facets
- Associated compression or burst components\*



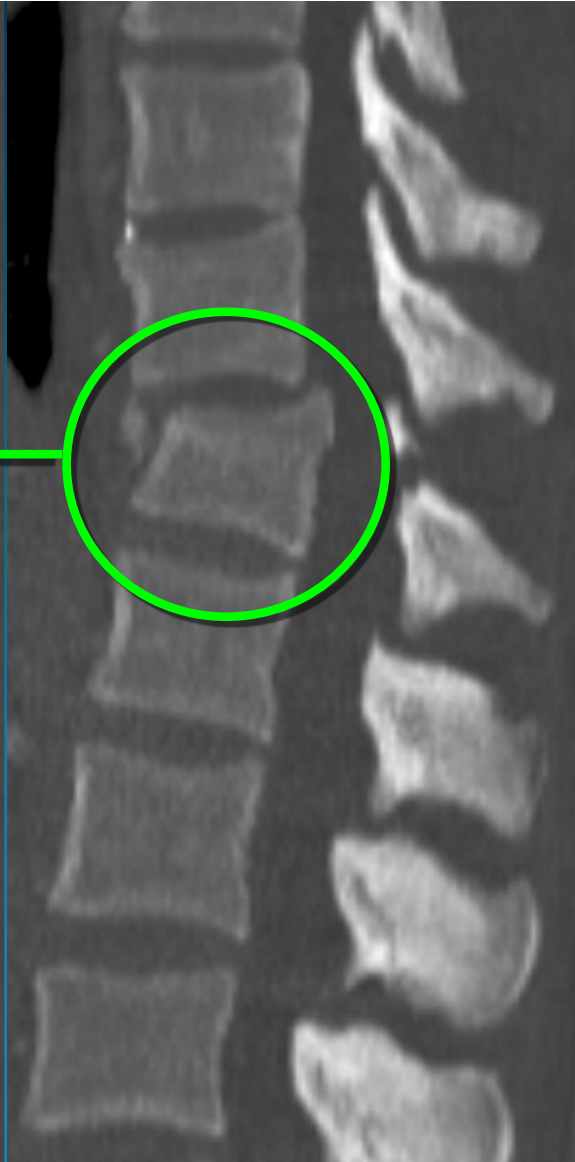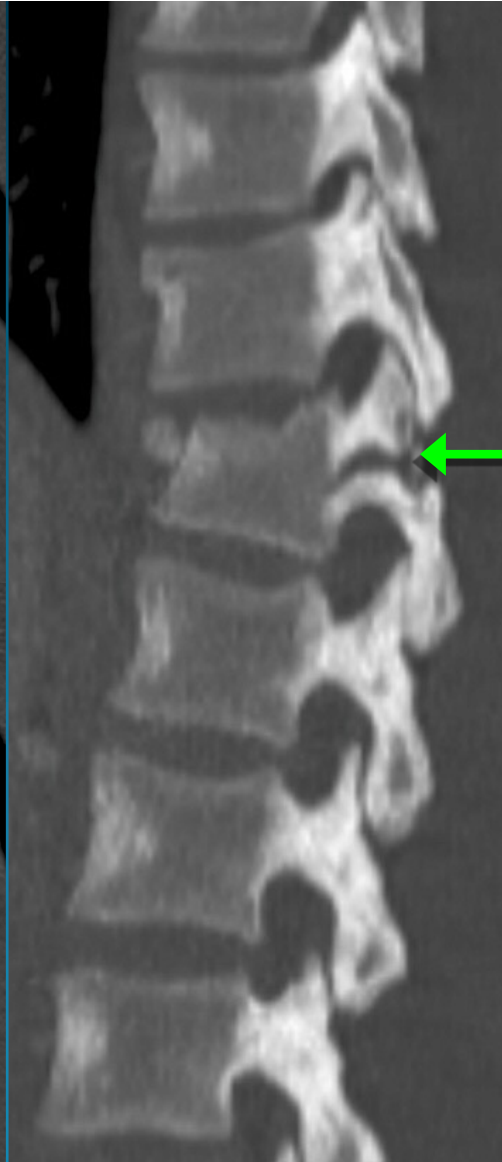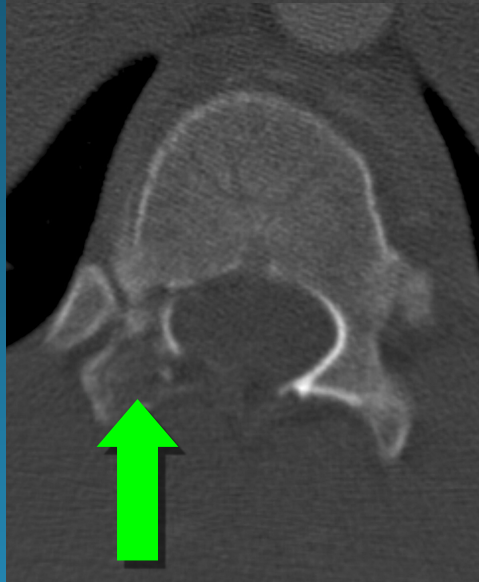
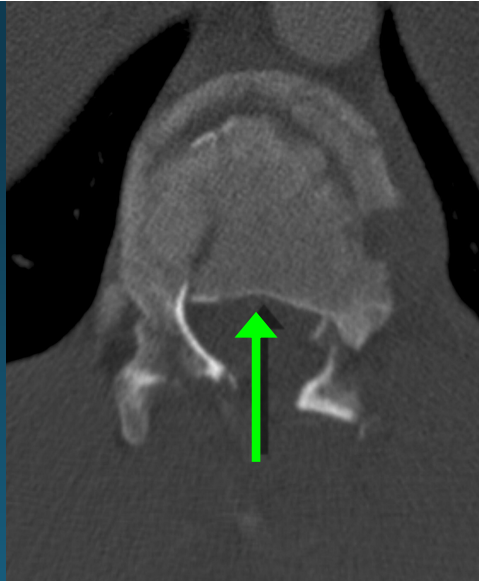# CHANCE FXS

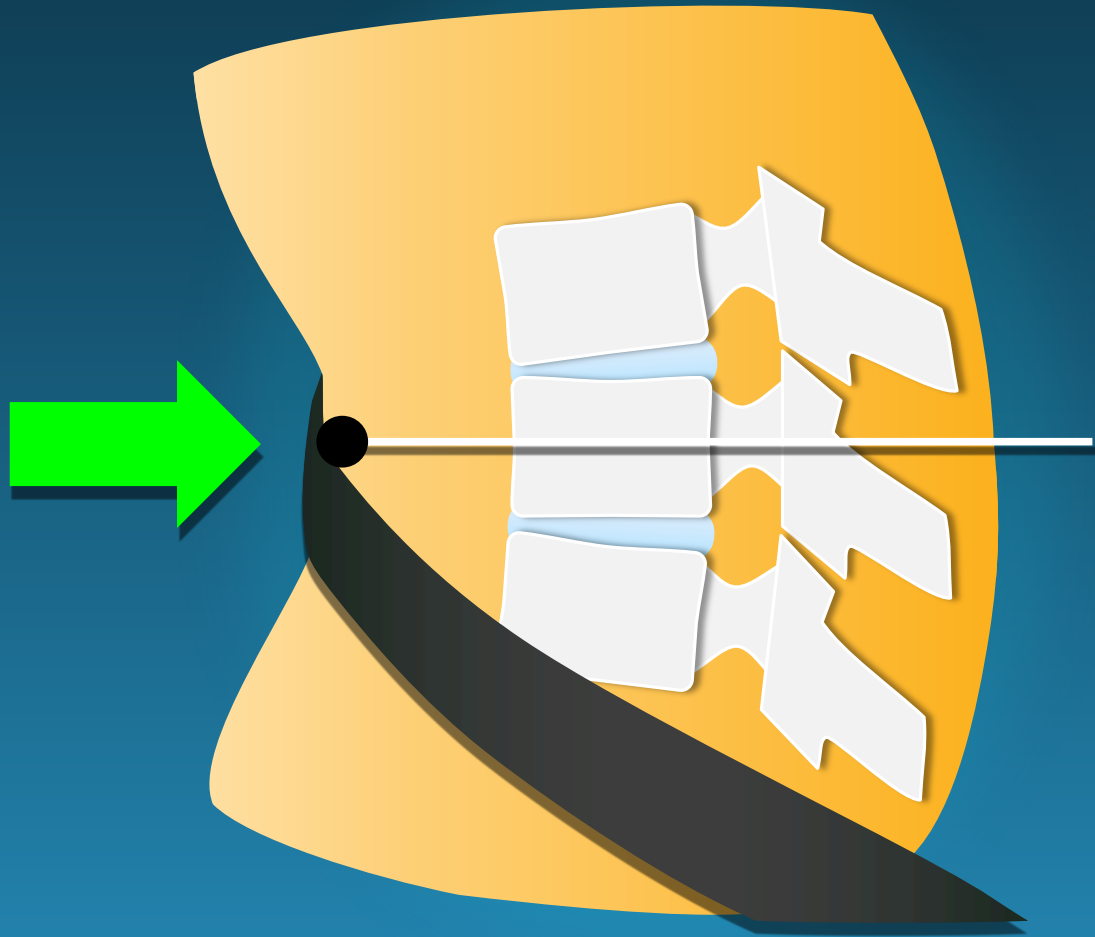
## CT – Transaxial

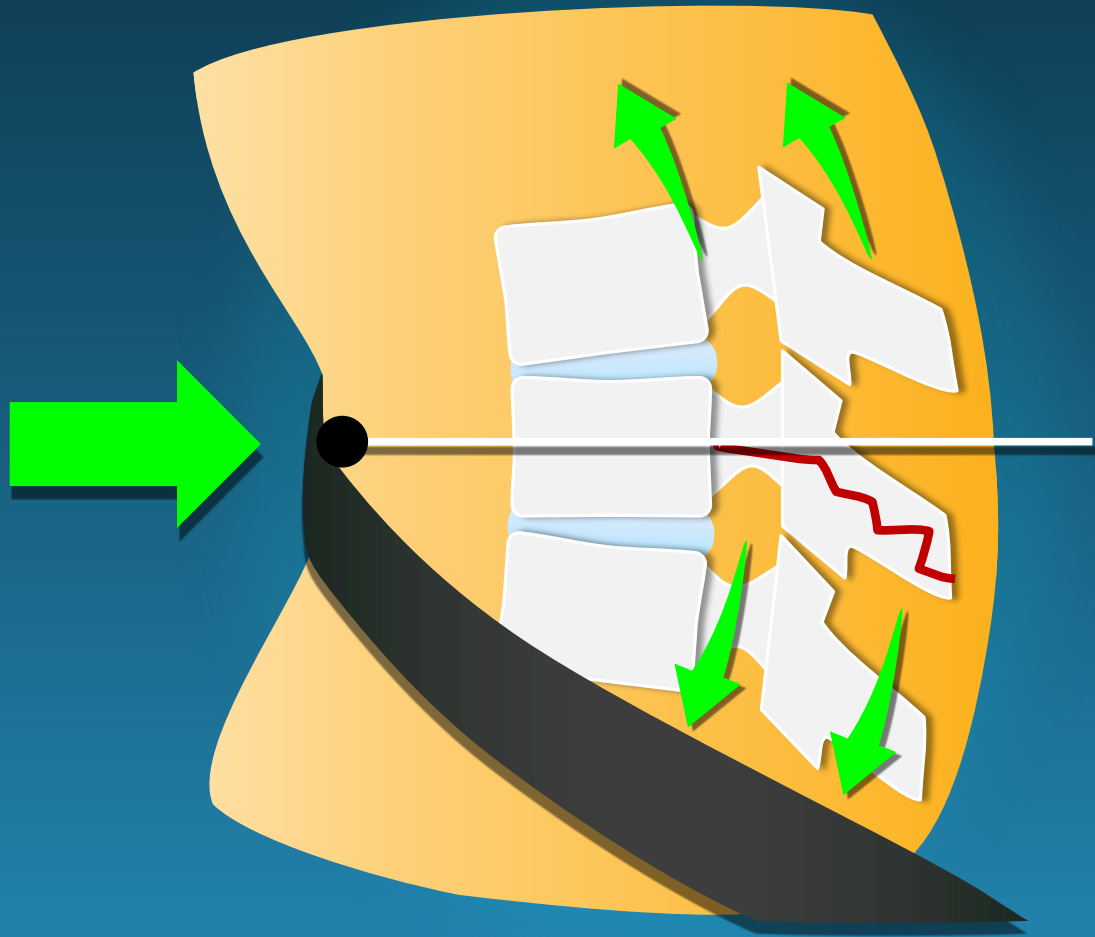
- Difficult – transverse orientation of fracture
- Naked facet
- “Dissolving Pedicle”
- Burst component\*\*

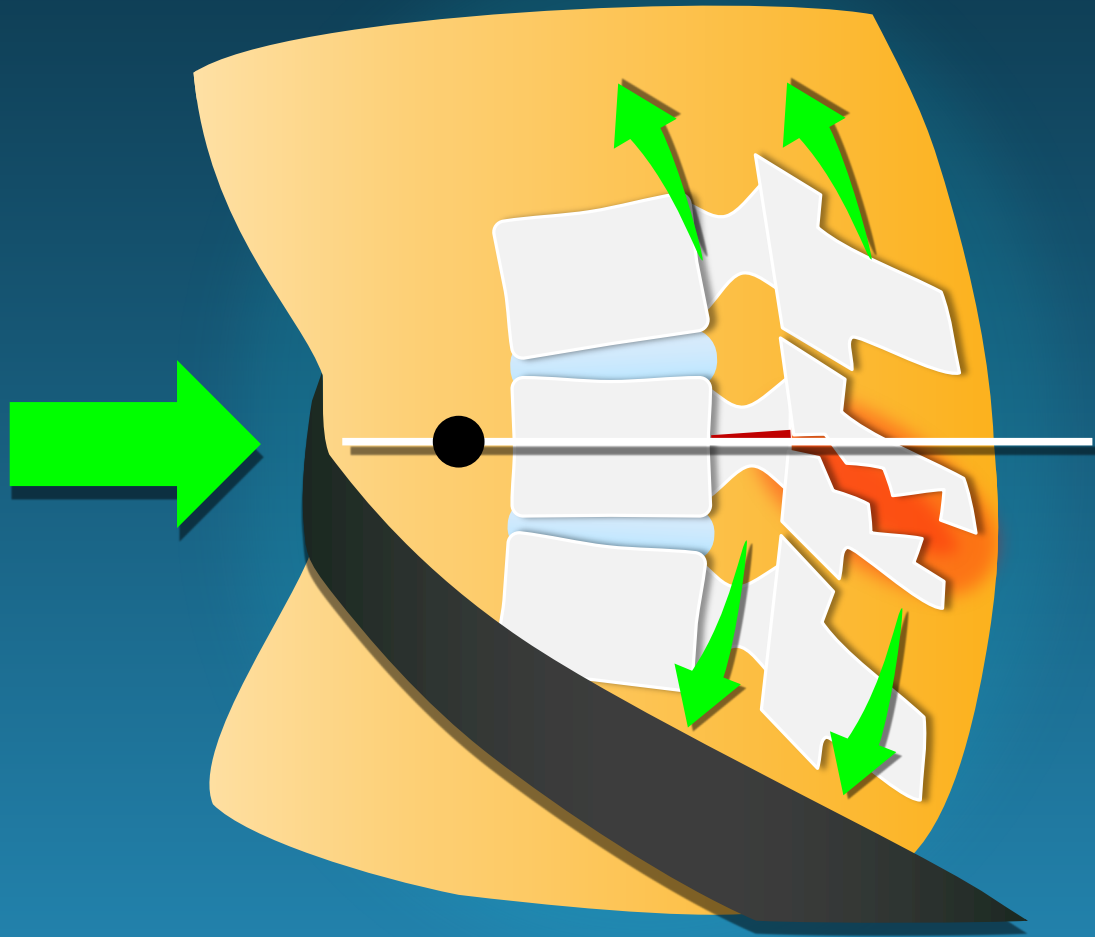


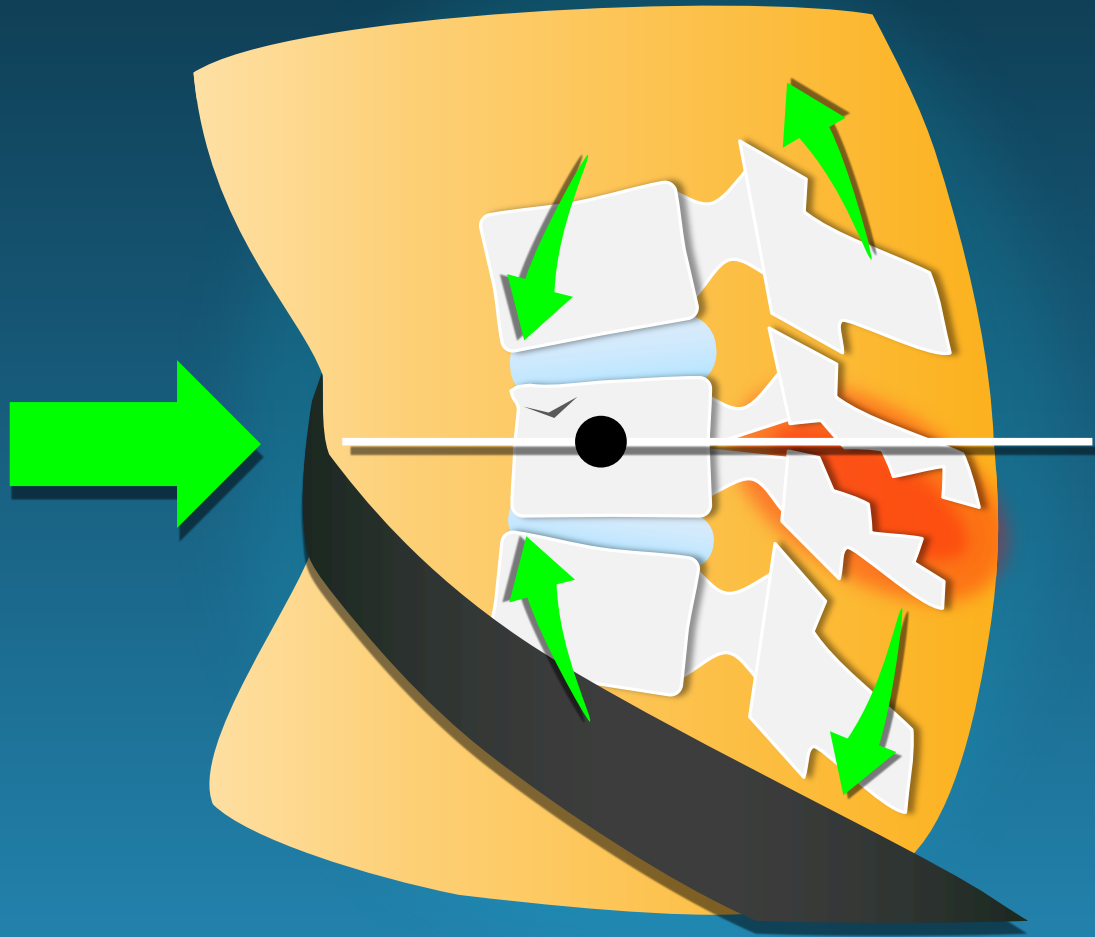
Chance-burst combo fx  
(B<sub>1</sub>, A<sub>3</sub>)

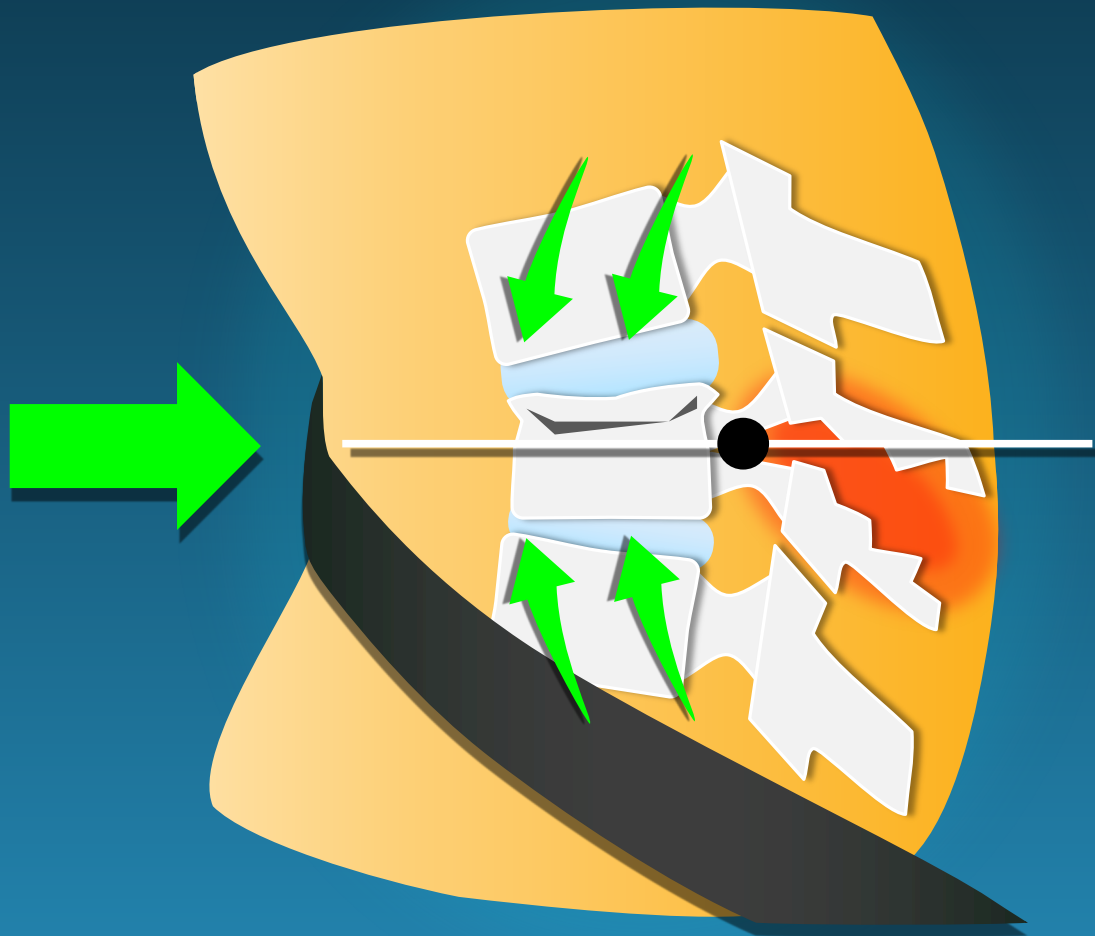




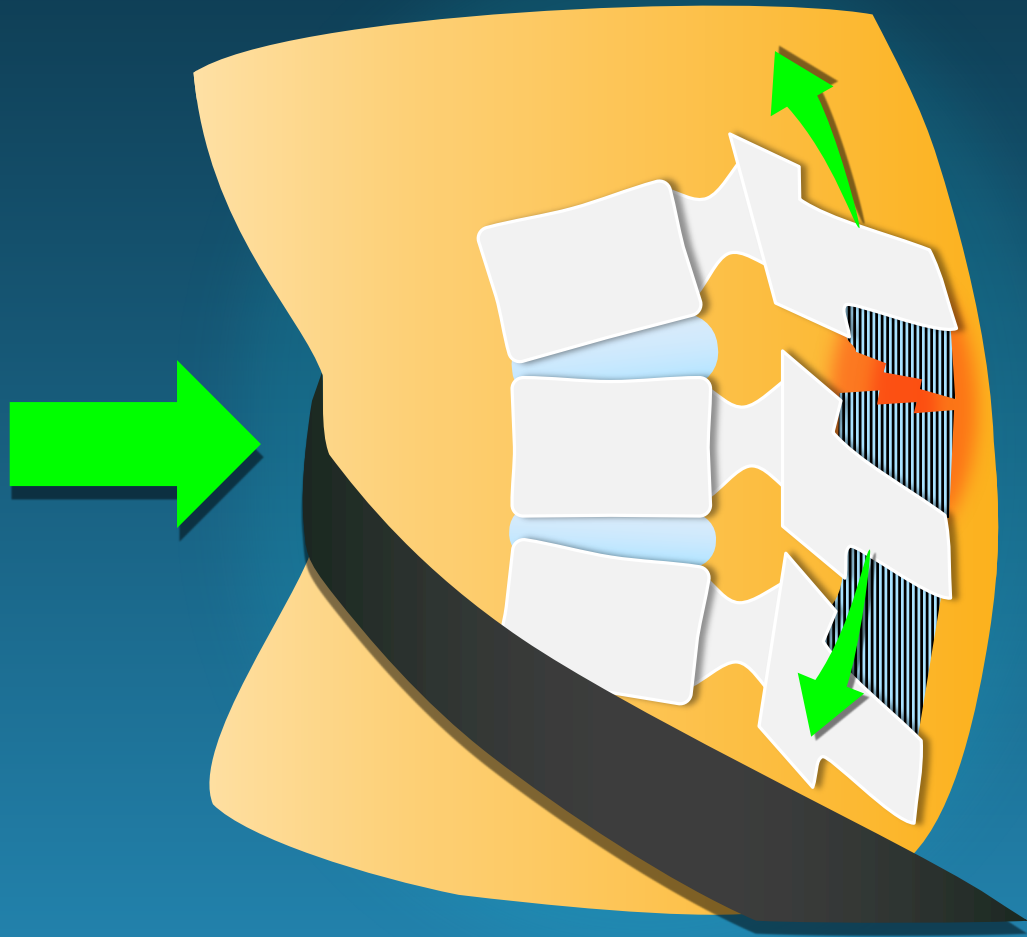








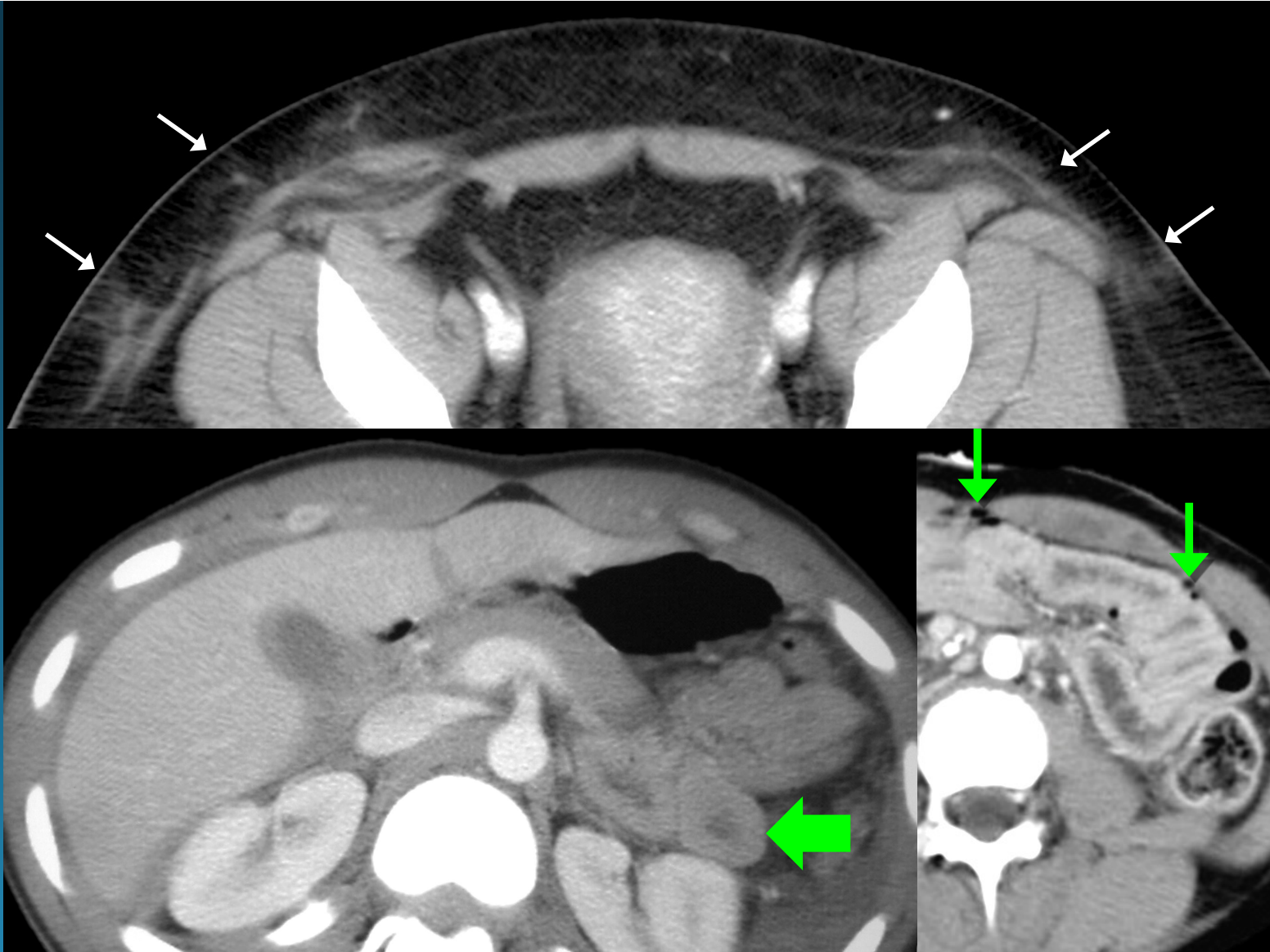



wide interspinous distance

## Chance fractures

seatbelt sign –  
bowel injury with  
free air



# T/L SPINE TRAUMA

## Hyperextension Fx

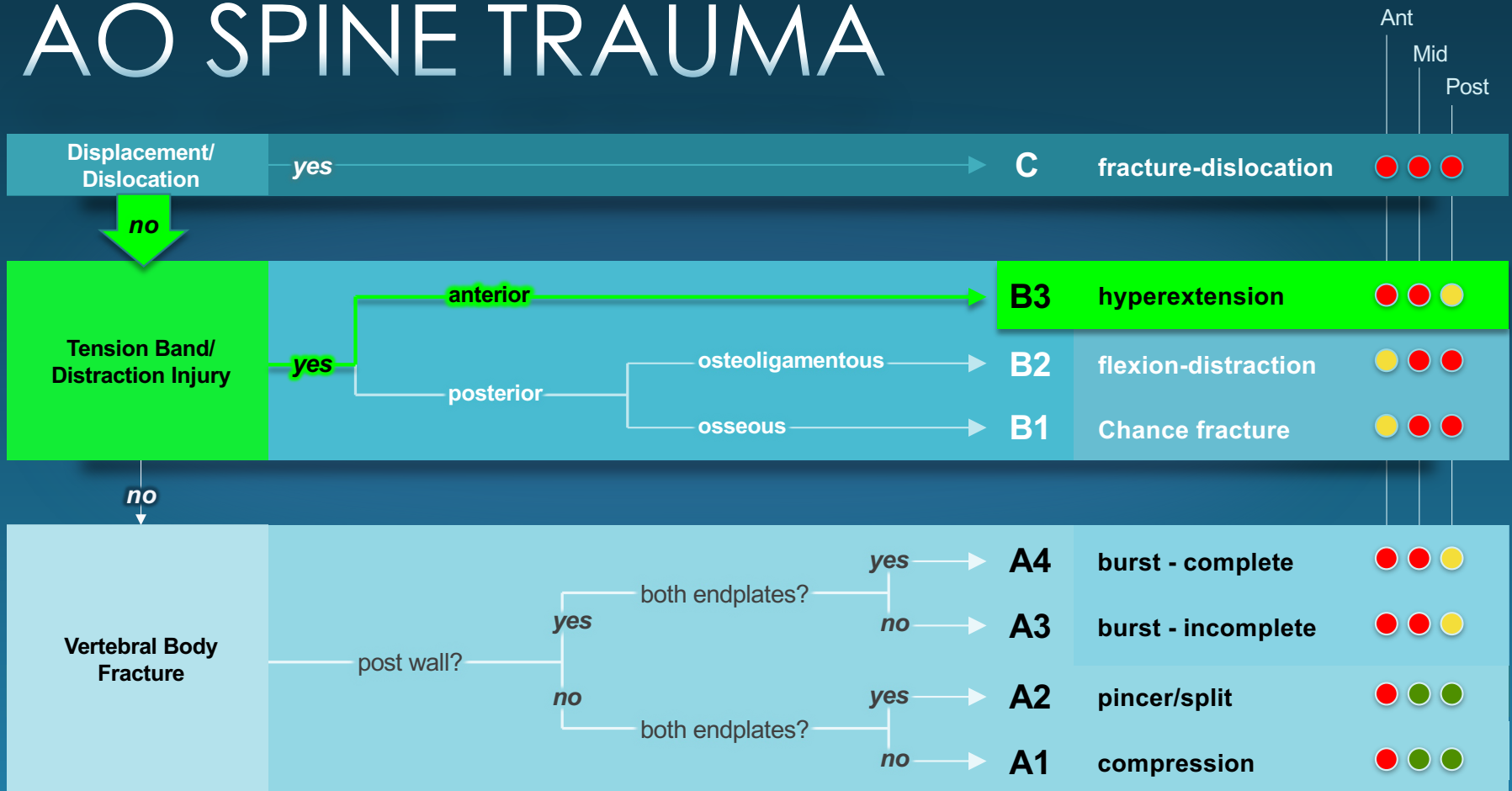
<i>Failure</i>	Anterior Middle ± Posterior
<i>Force</i>	Hyperextension
<i>Risks</i>	Ankylosing Spon. DISH, DJD
<i>Neuro</i>	High risk cord injury



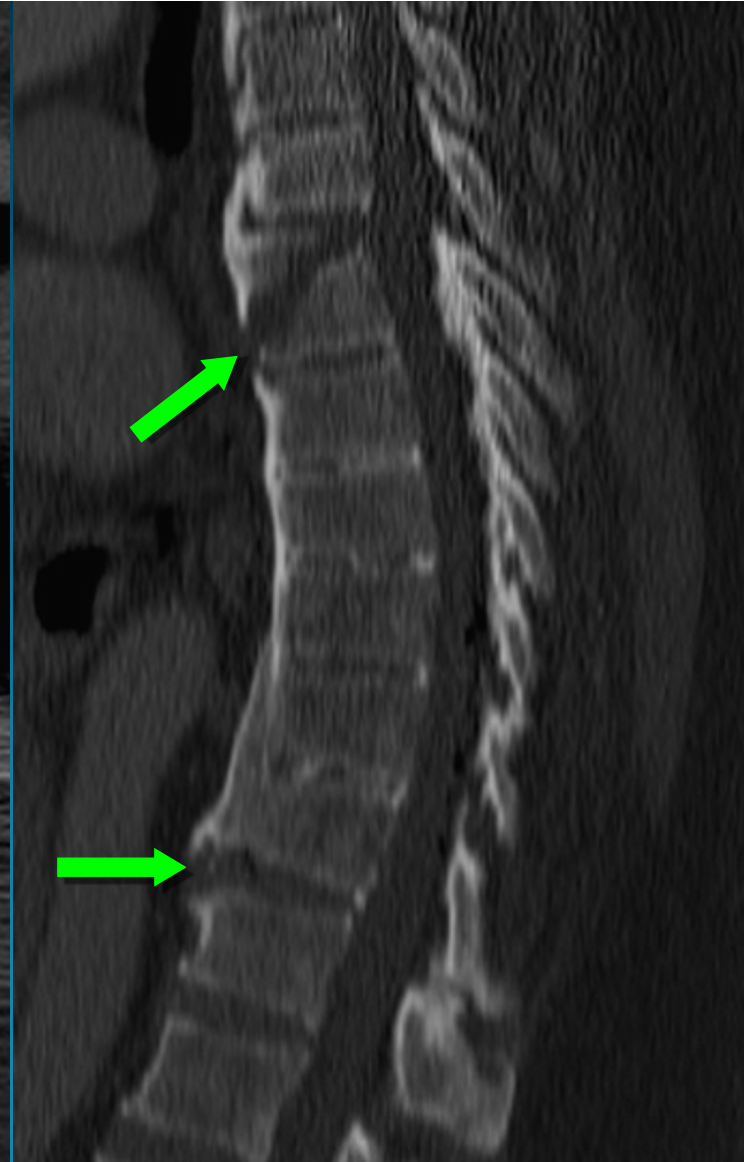
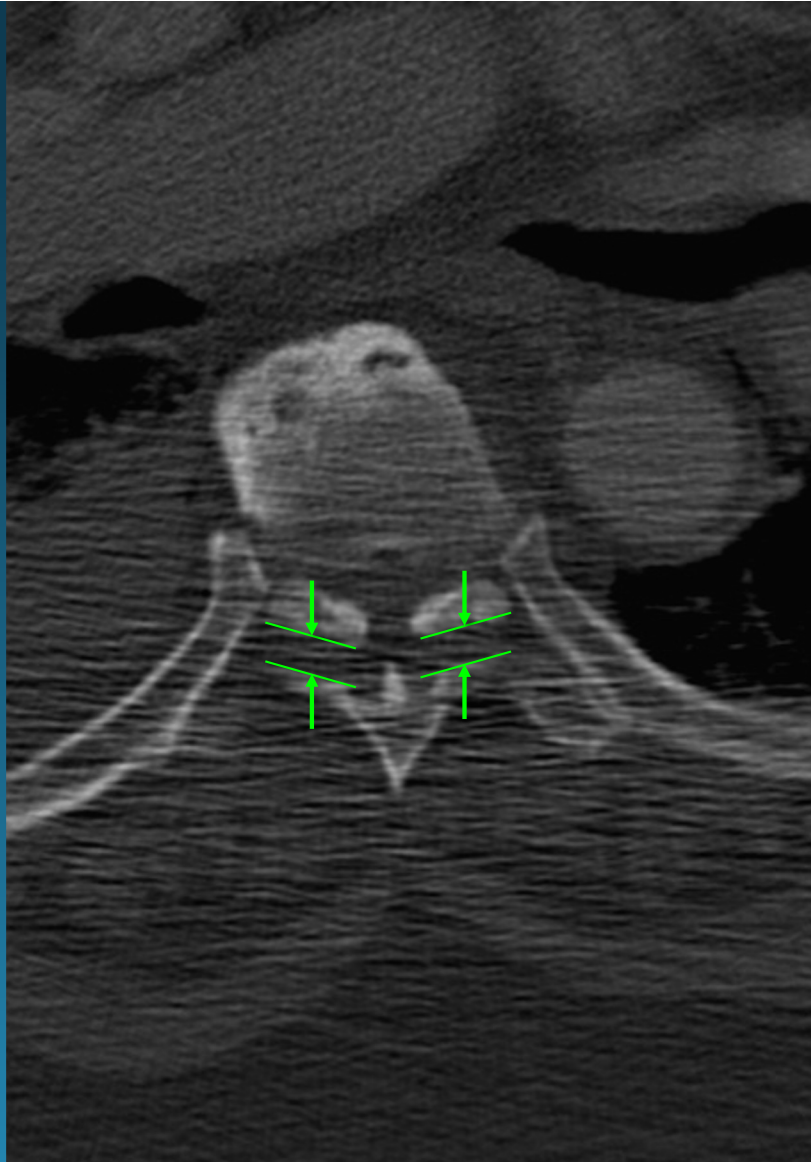
**UNSTABLE**

(fused spine) hyperextension injury

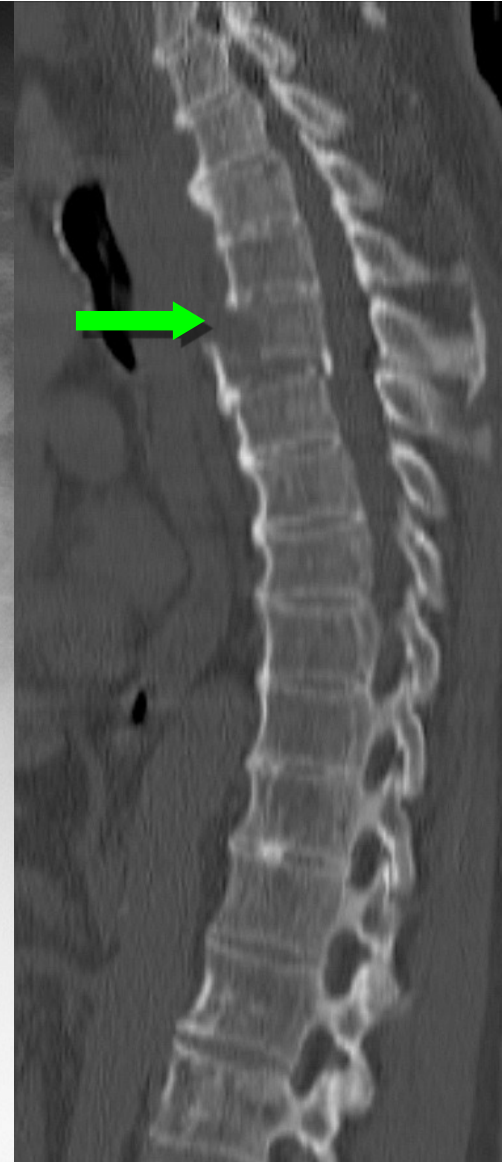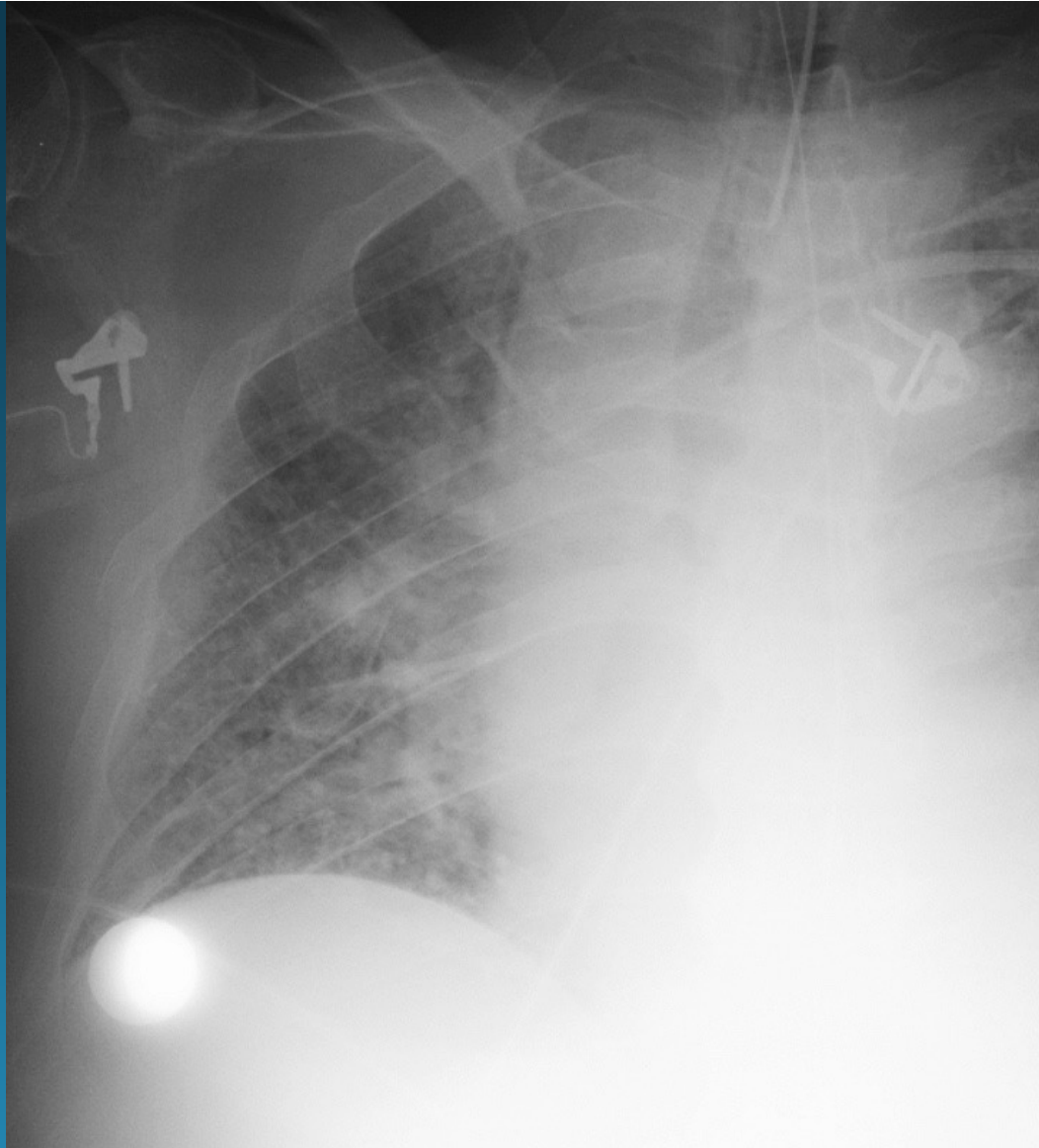
# AO SPINE TRAUMA



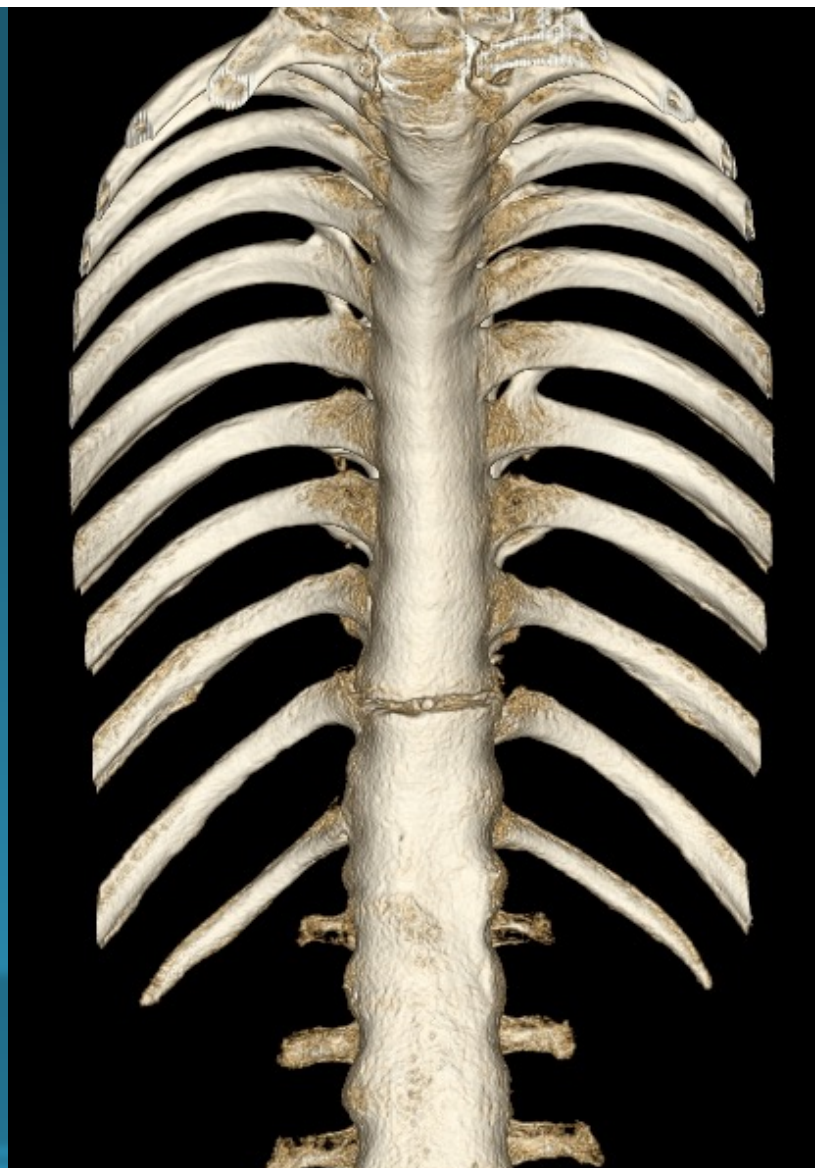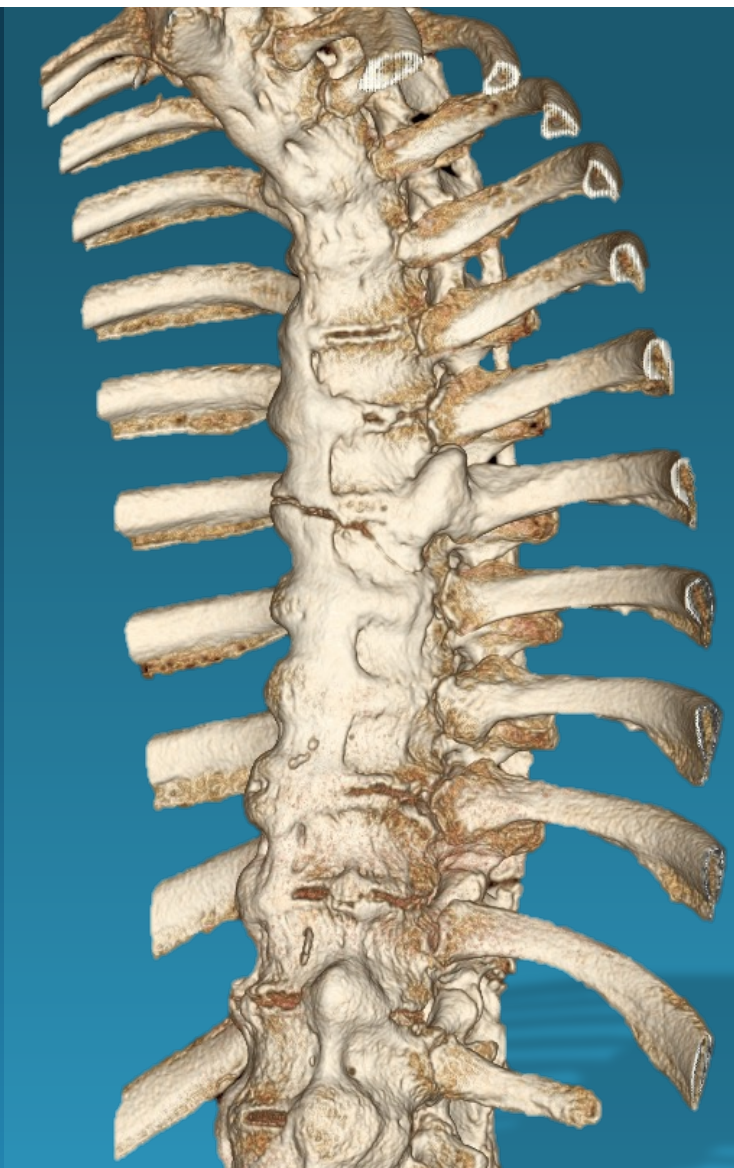
fused-spine  
hyperextension injury  
(B3)



fused-spine  
hyperextension injury  
(B3)



fused-spine  
hyperextension injury  
(B<sub>3</sub>)



# T/L SPINE TRAUMA

## Fx Dislocation

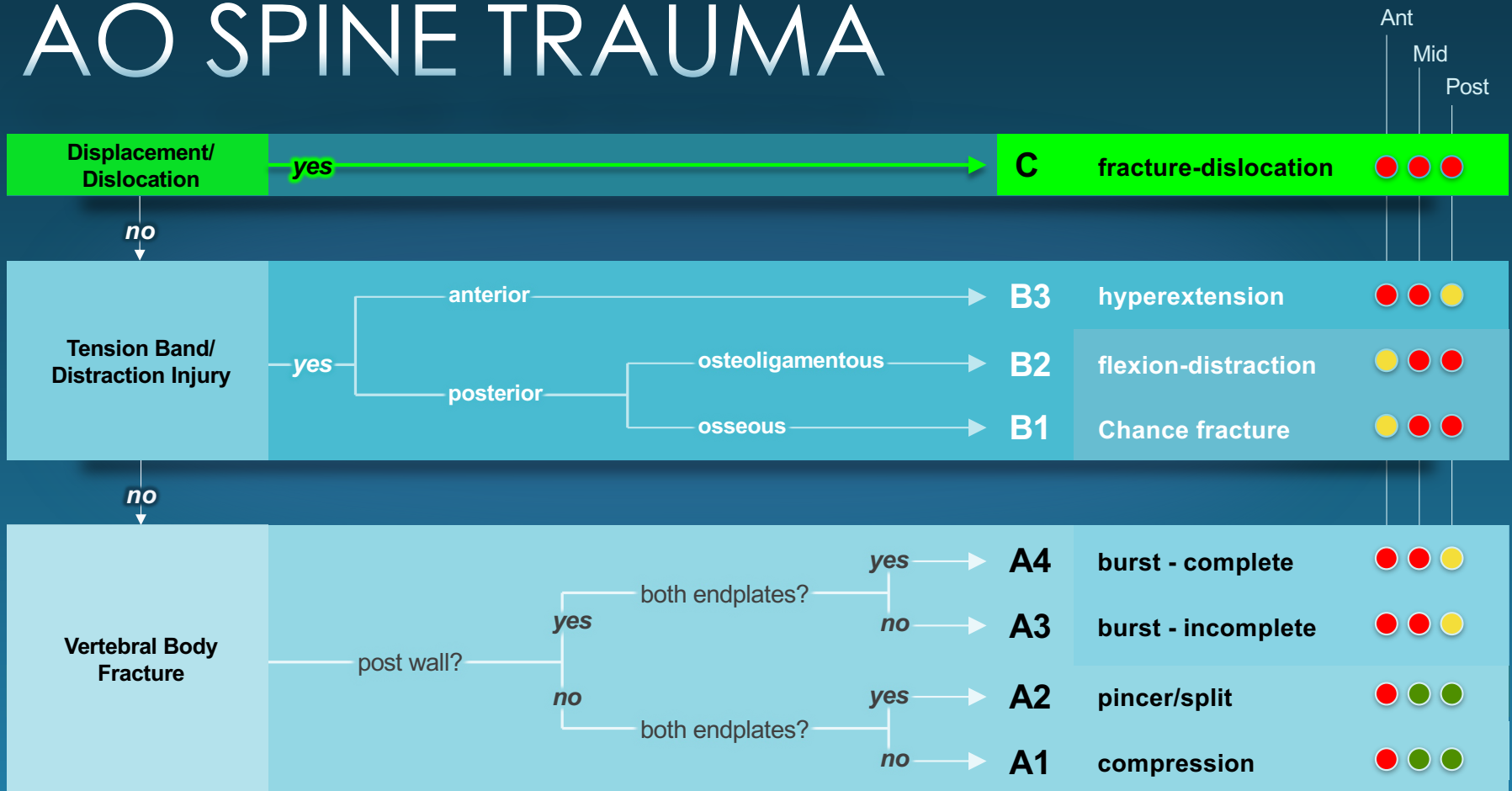
<i>Failure</i>	Anterior Middle Posterior
<i>Force</i>	Compression, Tension, Rotation, or Shear
<i>Neuro</i>	Usually devastating



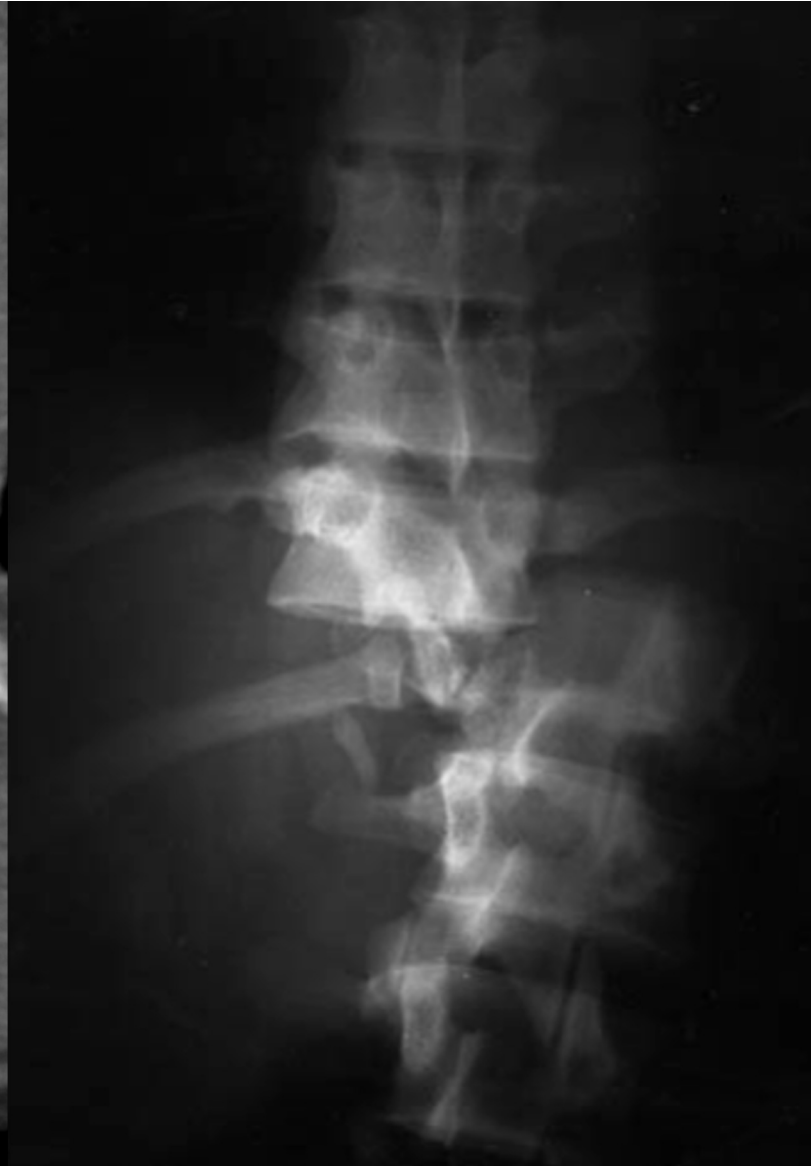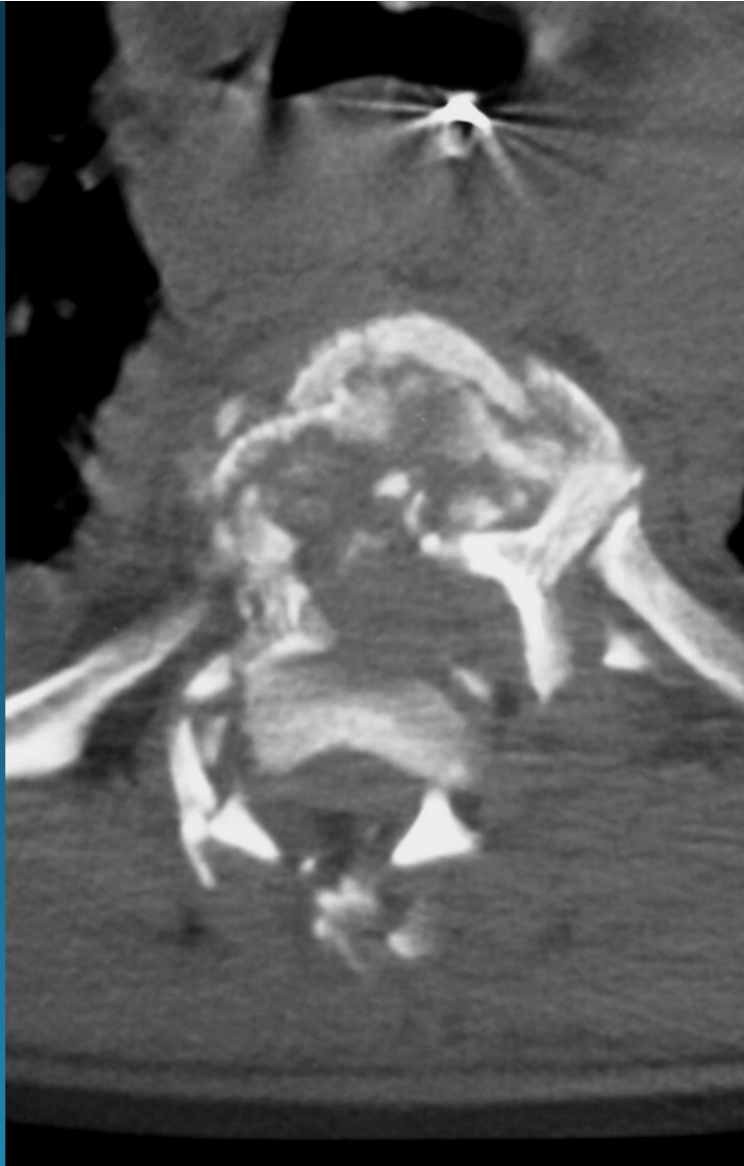
**UNSTABLE**



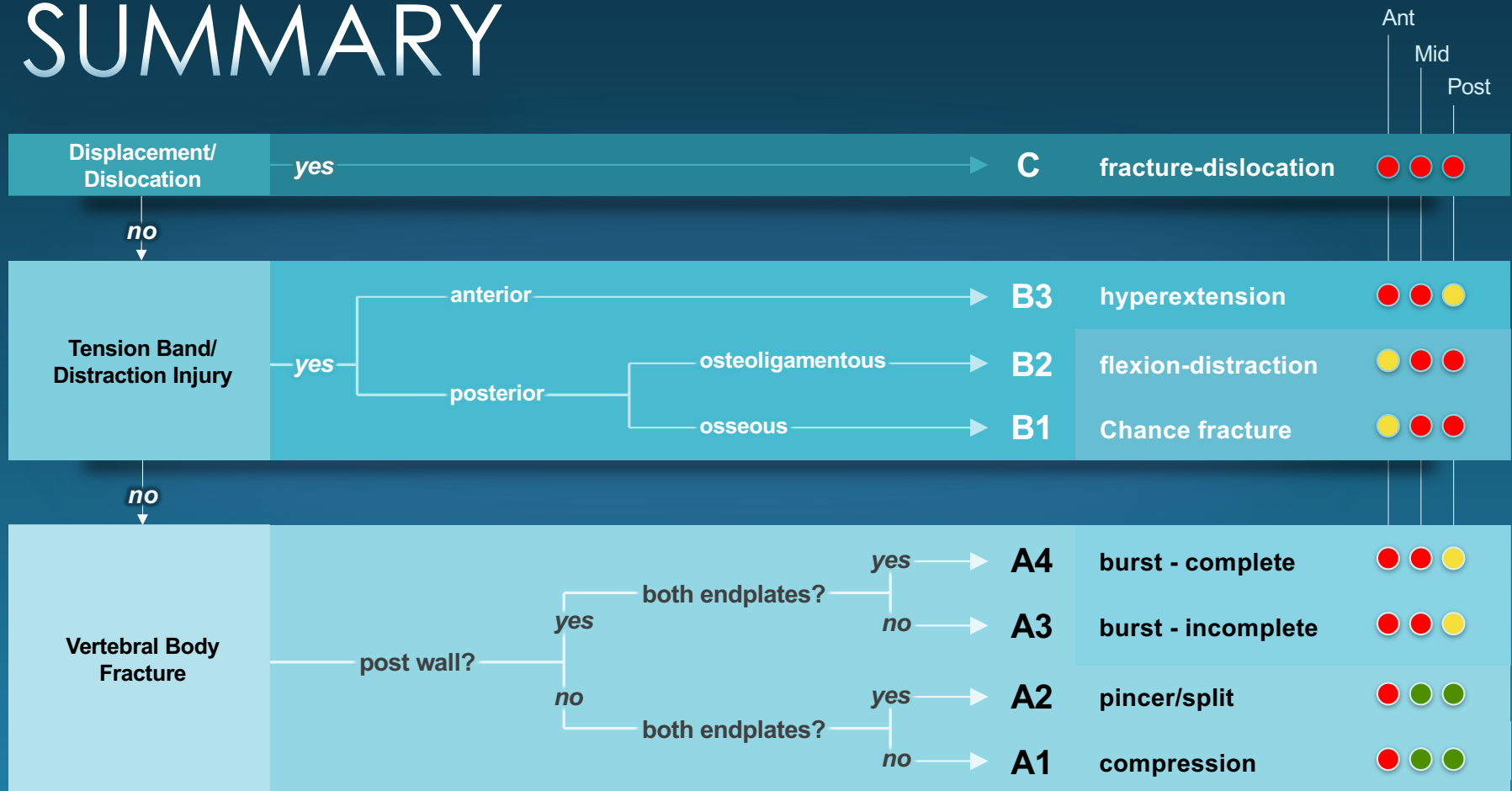
# AO SPINE TRAUMA



fracture-dislocation  
(C)



# SUMMARY





**THANK YOU!**



**BOSTON MEDICAL CENTER**