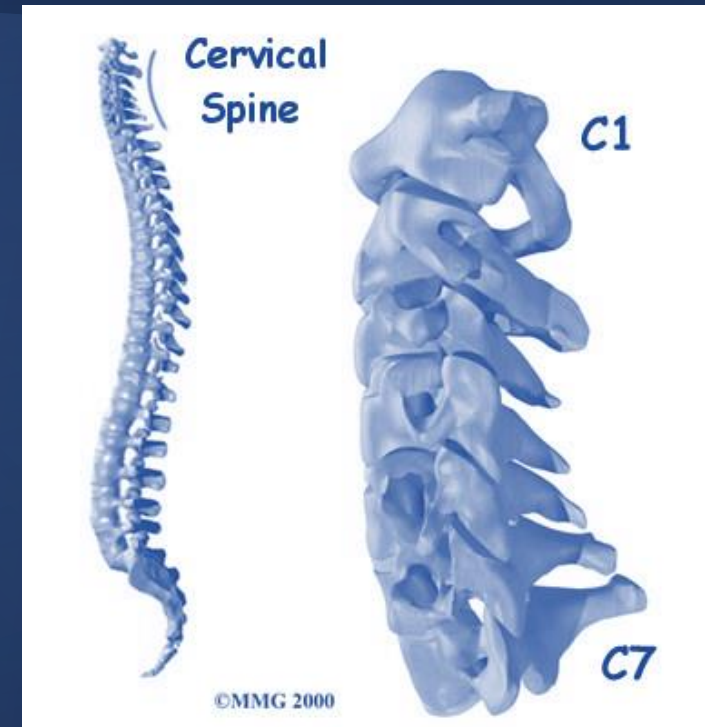


Cervical spine injuries

The neurosurgical perspective



Adrian Elmi Terander

Associate professor of Neurosurgery


Karolinska Institutet

Capio Spine Center Stockholm



Ancient History

Edwin Smith
Papyrus



1600 BC



Galen of
Pergamon

Kyphosis, Lordosis, Scoliosis

129-200 AD

460-370 BC

Hypocrates

External stabilization and immobilization

625-690 AD

Paul of Aegineta
Laminectomy

Spine surgery

Edwin Smith
Papyrus



1600 BC

Anesthesia

Antisepsis
Semmelweis

1844

1847

Laminectomy
Mac Ewen

1886

1891

X-rays
Röntgen

1895

ACDF
Smith/Robinson

1955

1958

ACDF
Cloward

1959

Fixation rods
Harrington

Pedicle
screws
Boucher

Disc
replacement
Fernström

1966

1989

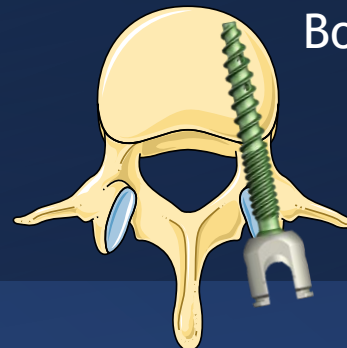
Modern
ADR

Traction &
Immobilization

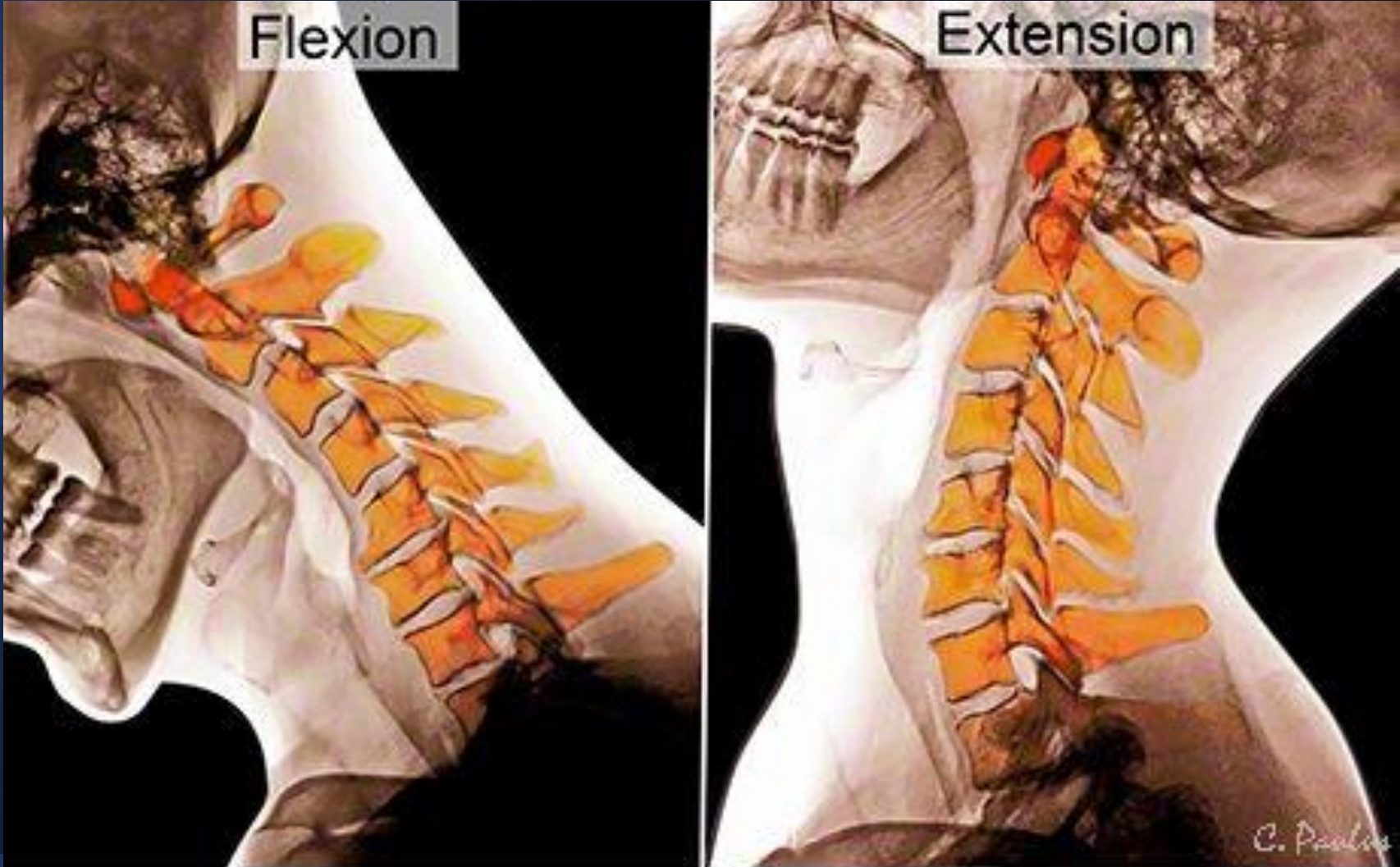
Plaster cast

Wire fusion

Fractures = paralysis



Cervical spine mobility



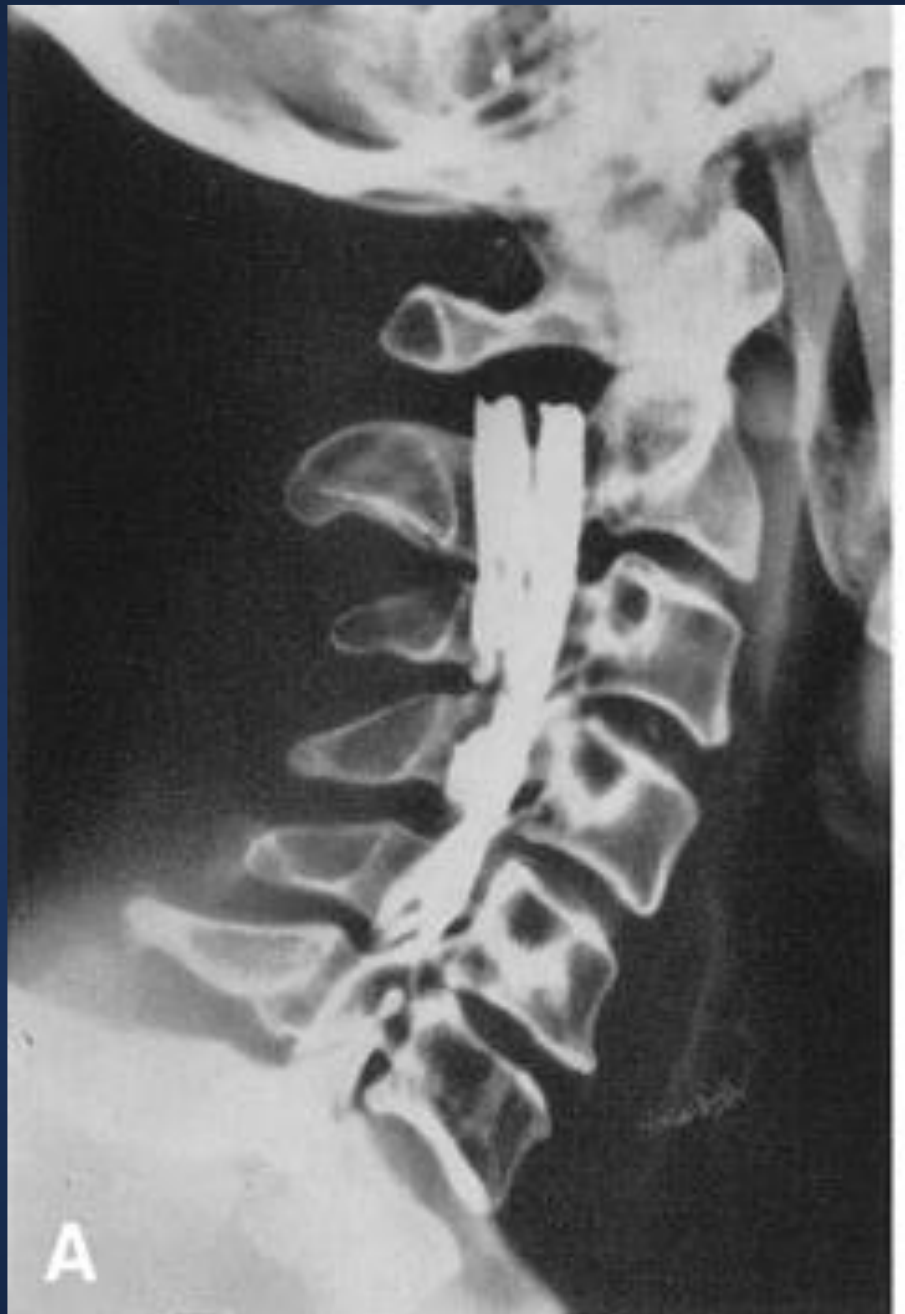

- Carl Hirsch:

Swedish orthopedic surgeon performed spinal biomechanical studies in the 1940s

- Lysell 1969:

Comprehensive in vitro study of cervical spine motion and patterns of motion



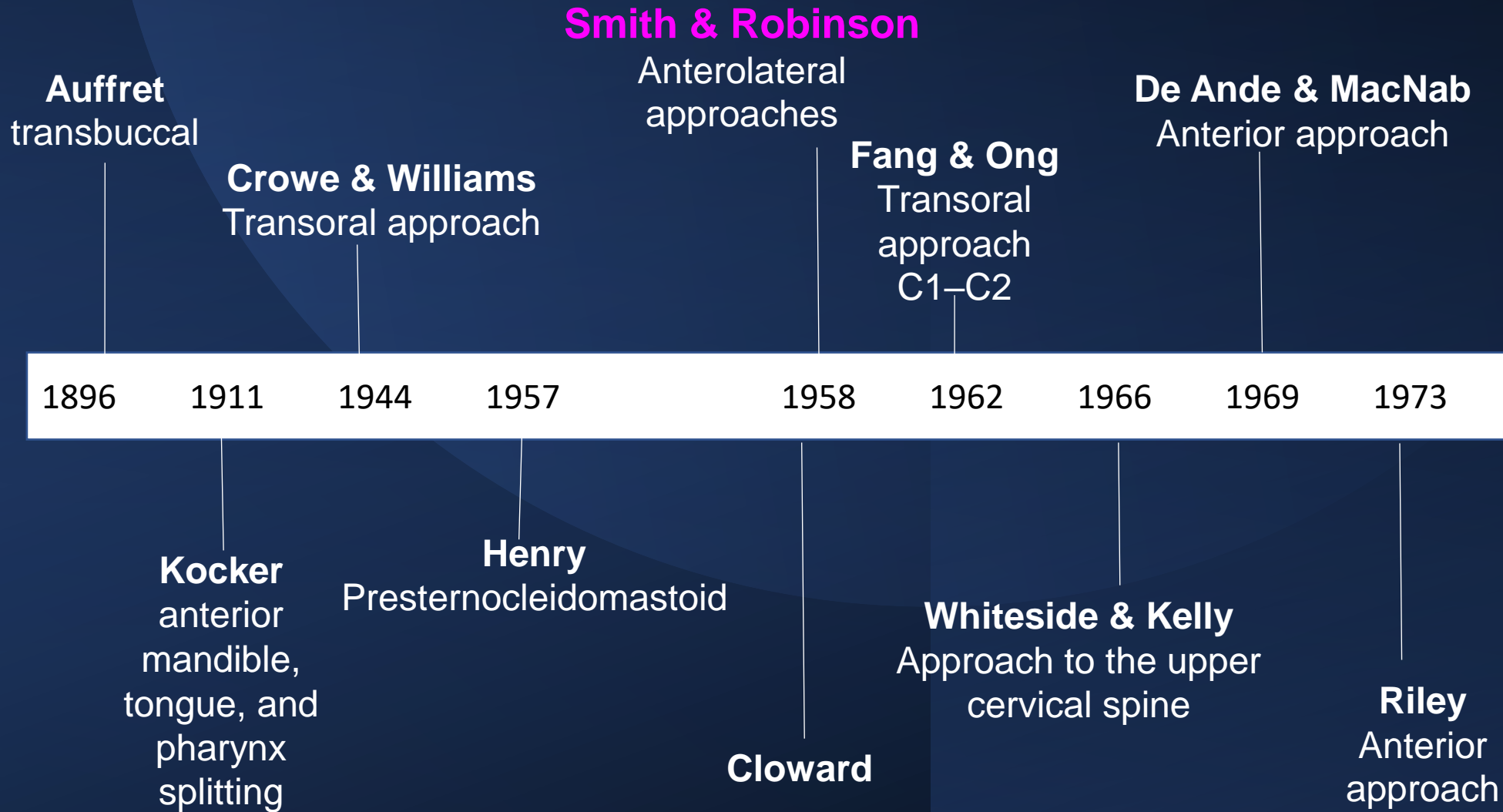


Brain and Wilkinson 1952: A series of 45 patients with compression of the spinal cord (38) or nerve roots (7).

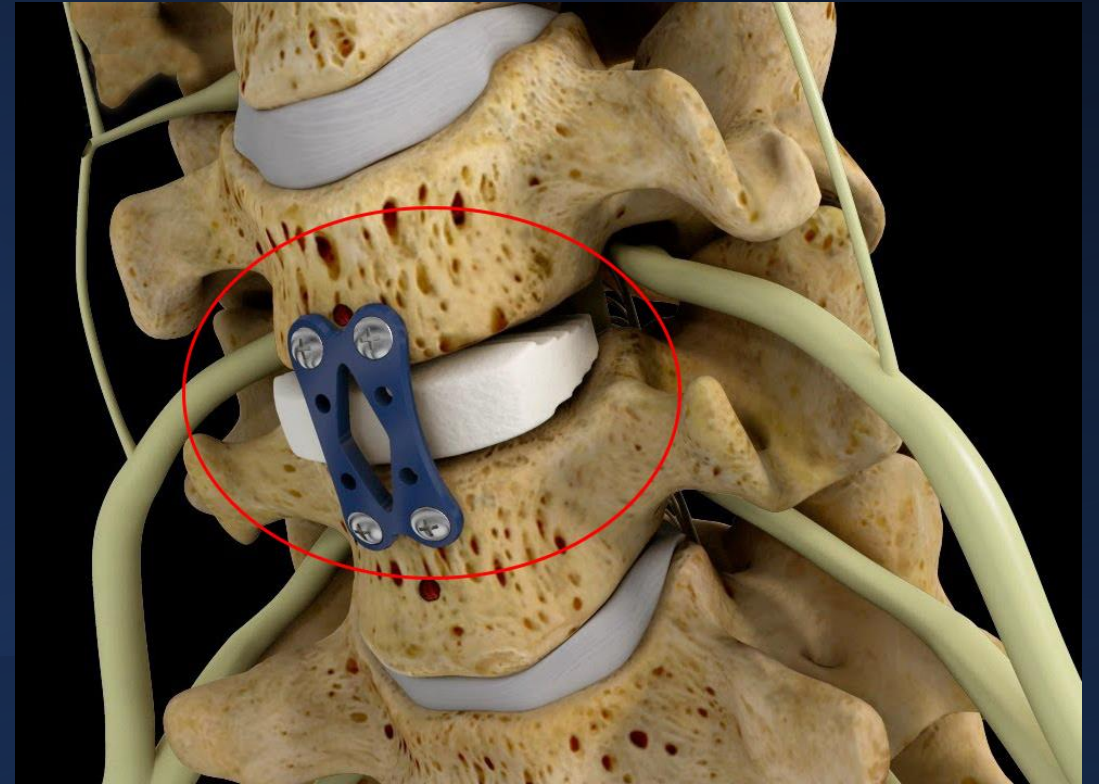
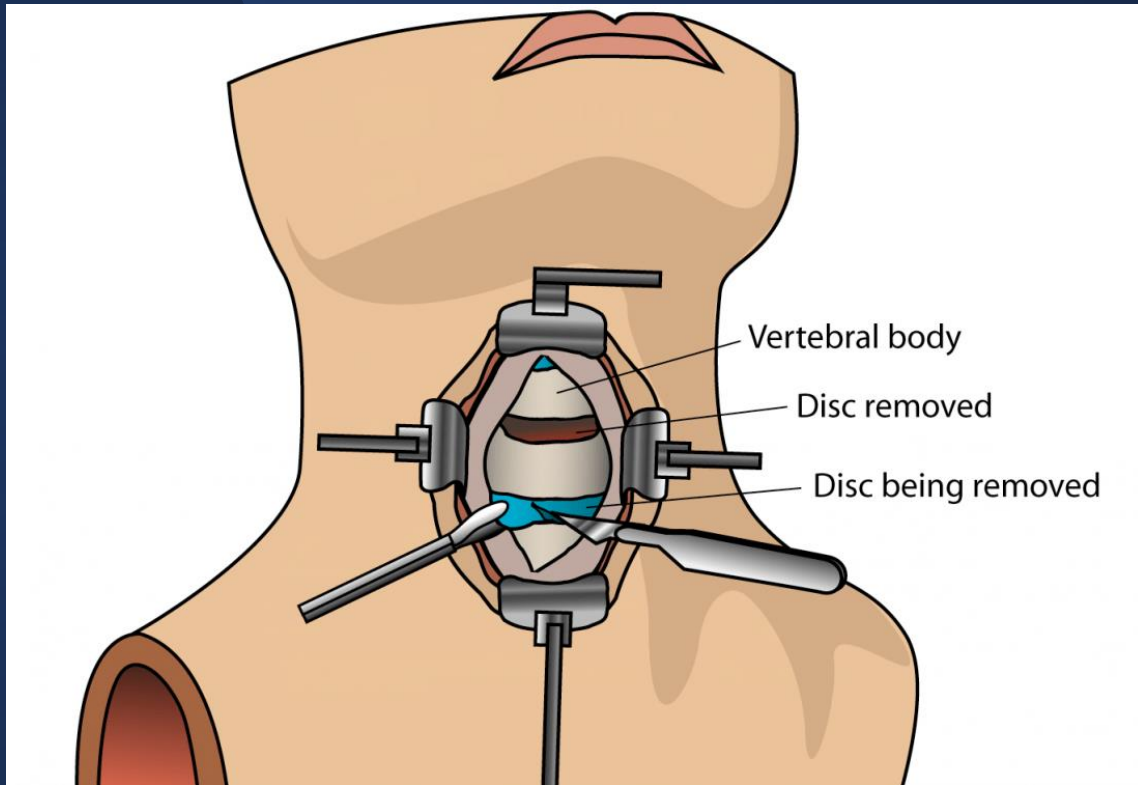
- Primary lesion: degeneration of the intervertebral disc
 - Acute lesions due to herniation of the nucleus pulposus
 - Chronic lesions arising from degenerative spondylosis

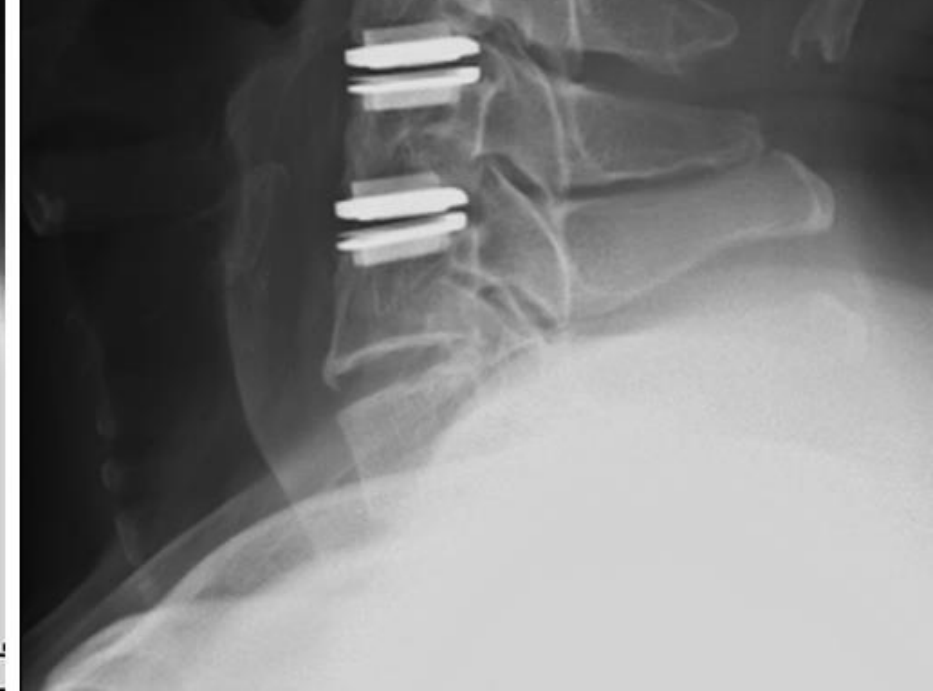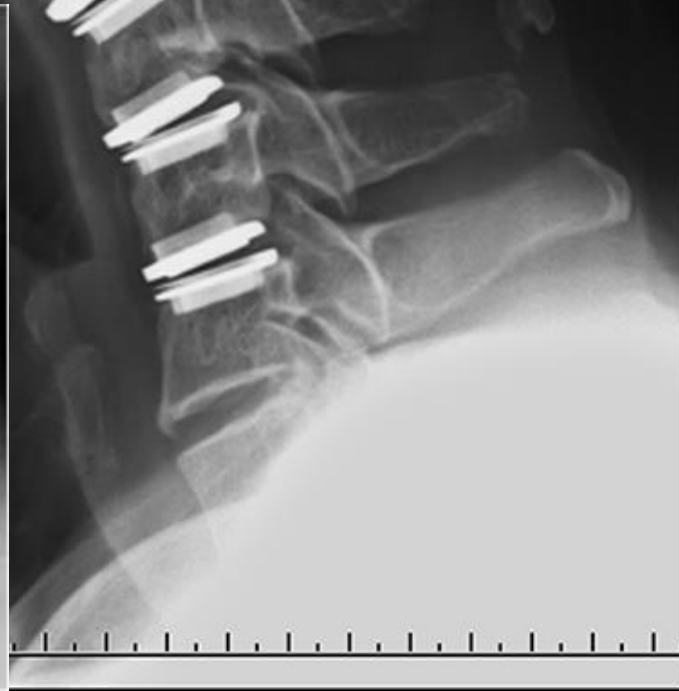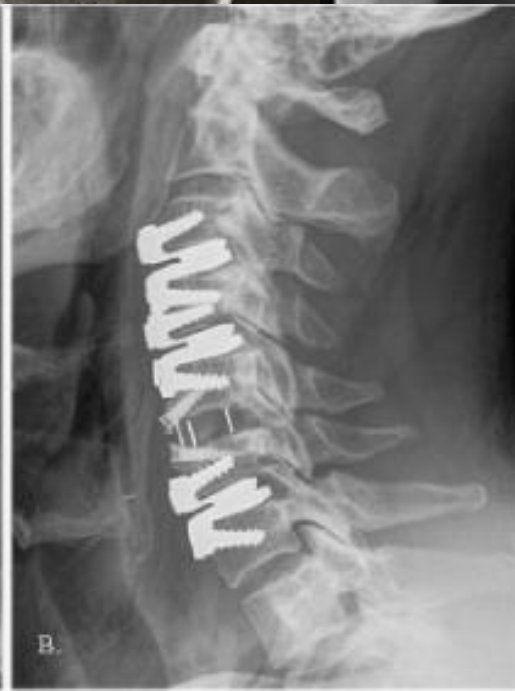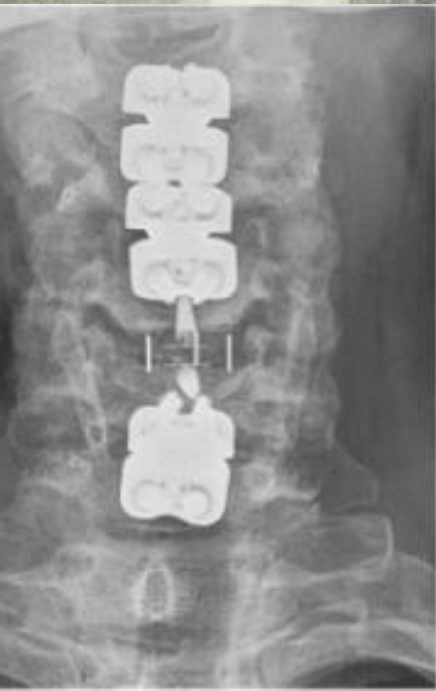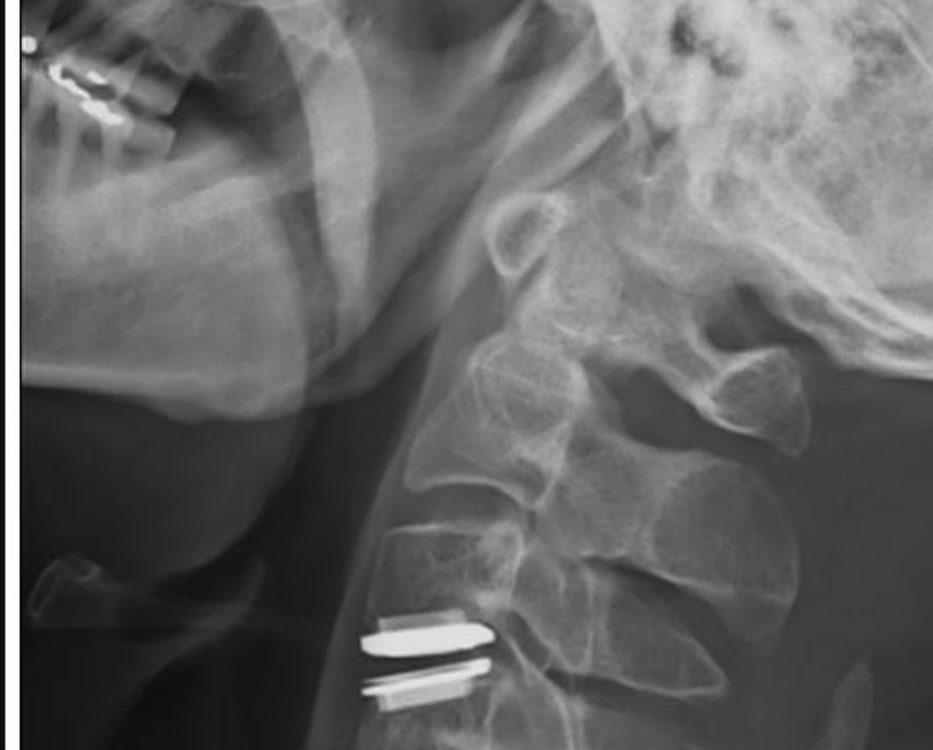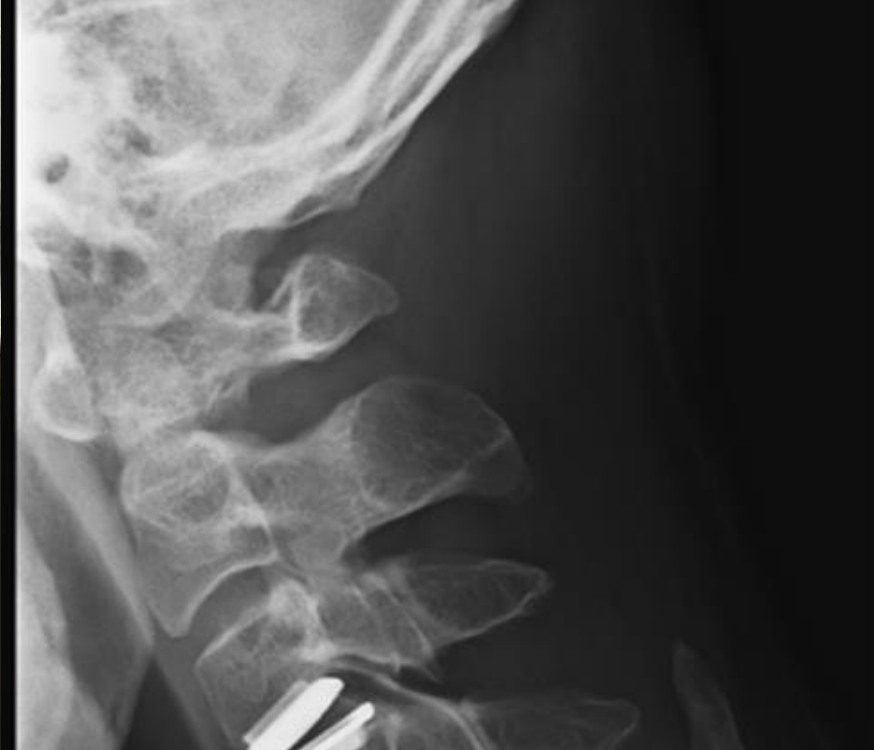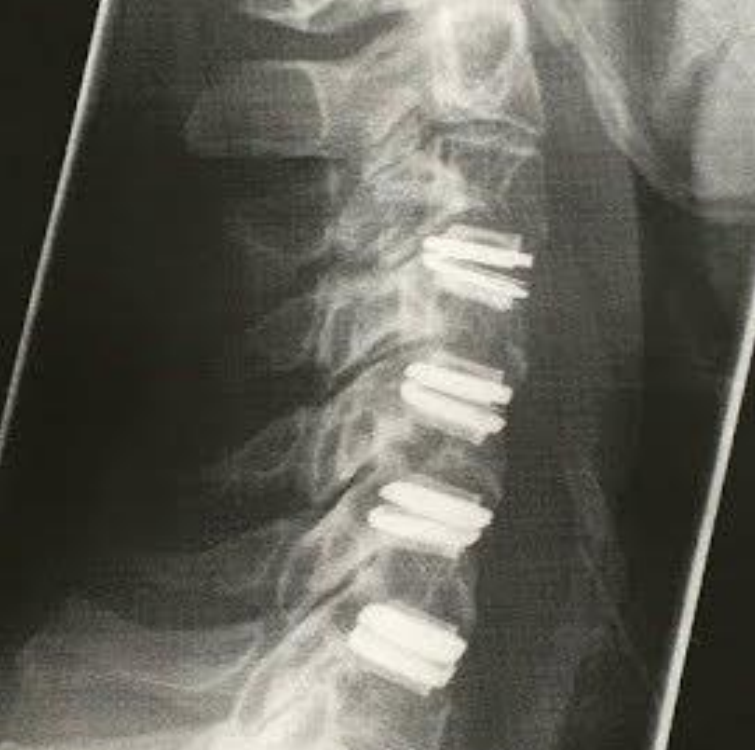A lateral radiographic myelogram shows compression from C5–C6 cervical disk herniation, 1966

Anterior cervical approaches

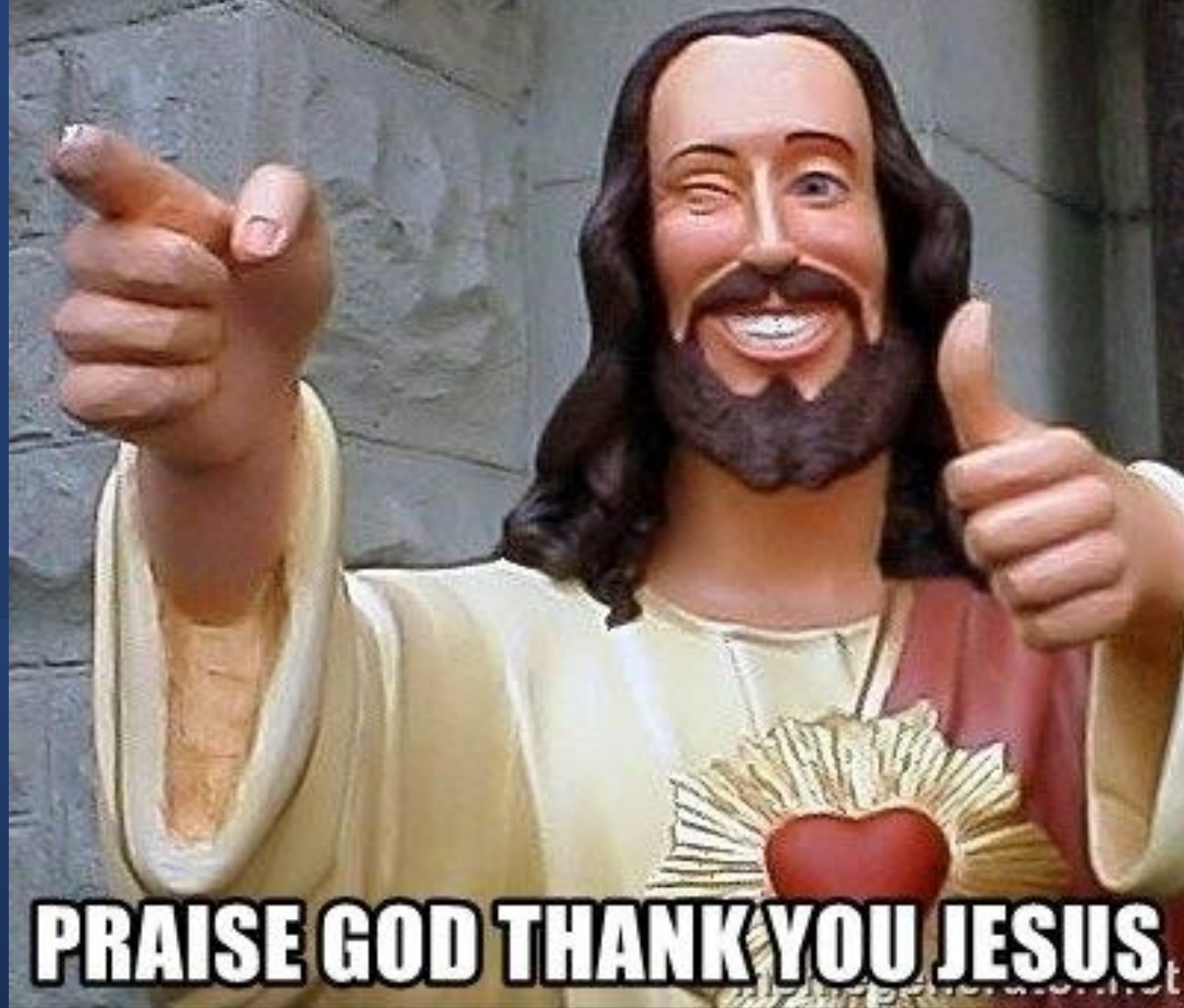

Anterior Cervical Discectomy and Fusion - ACDF





ITS A MIRACLE

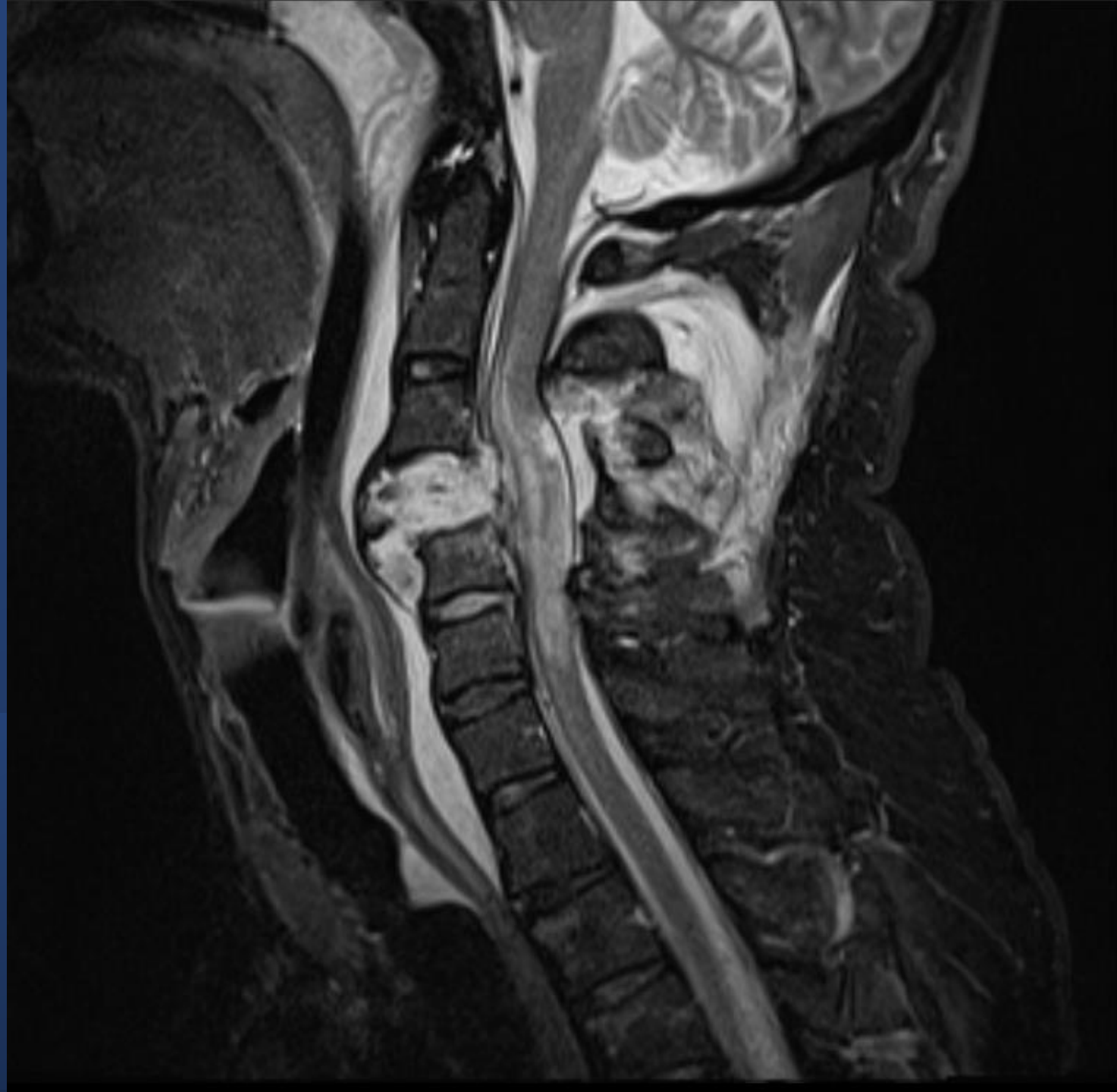

PRAISE GOD THANK YOU JESUS

Case 1

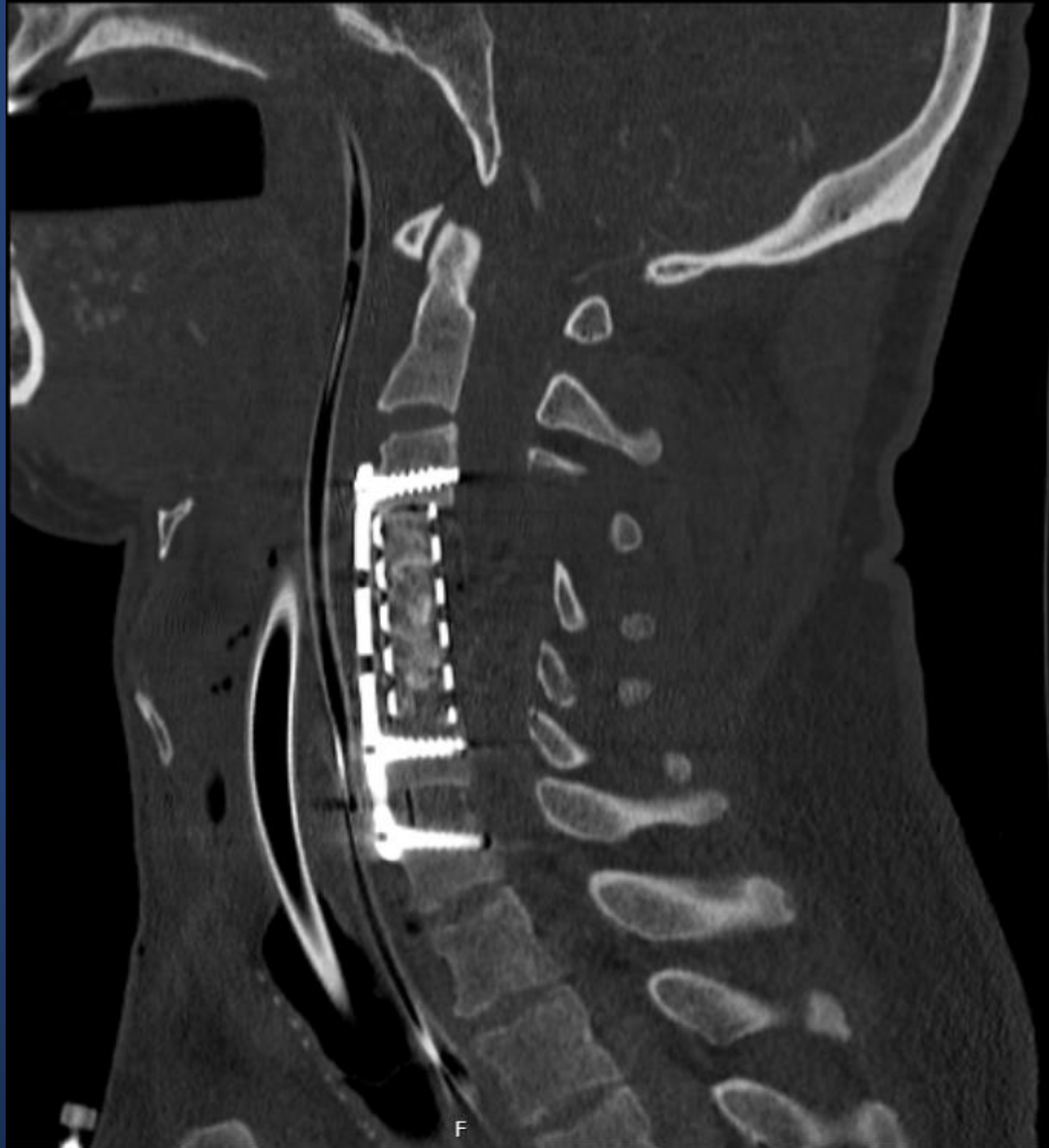
Multiple injuries

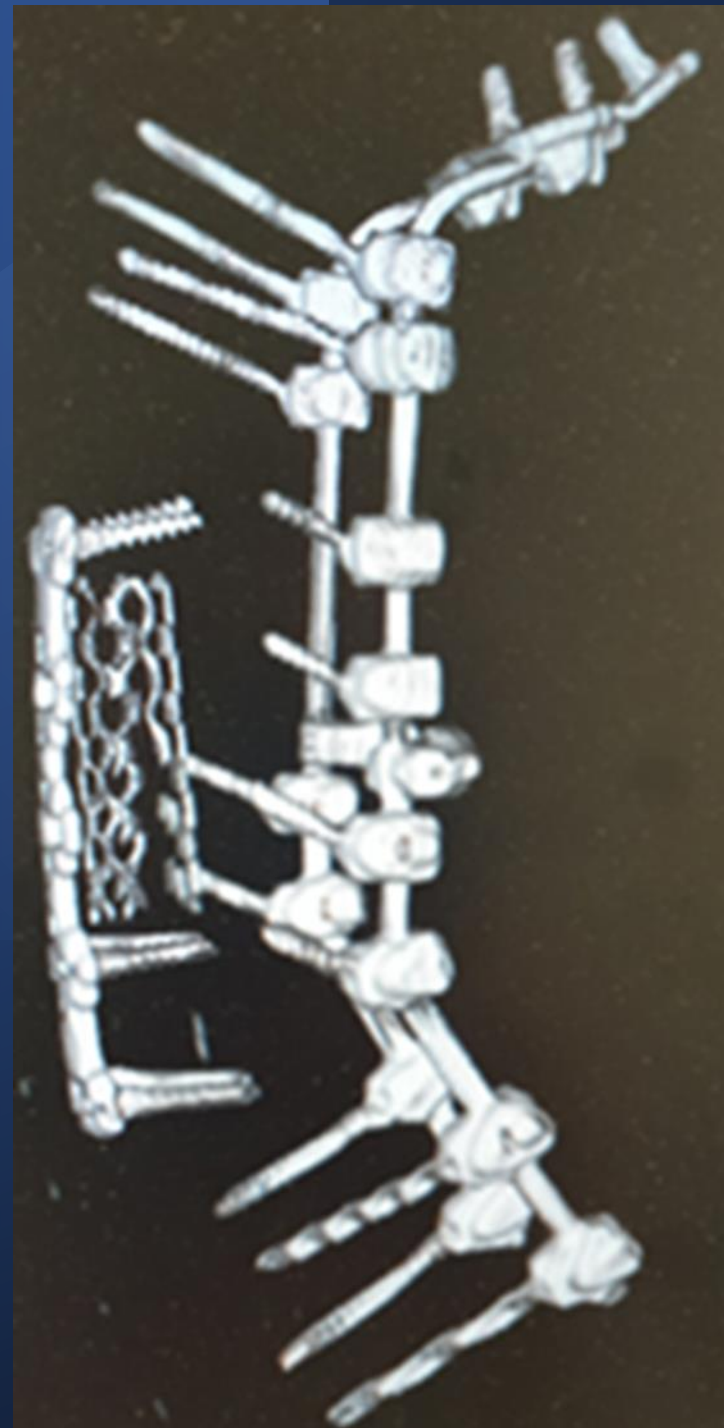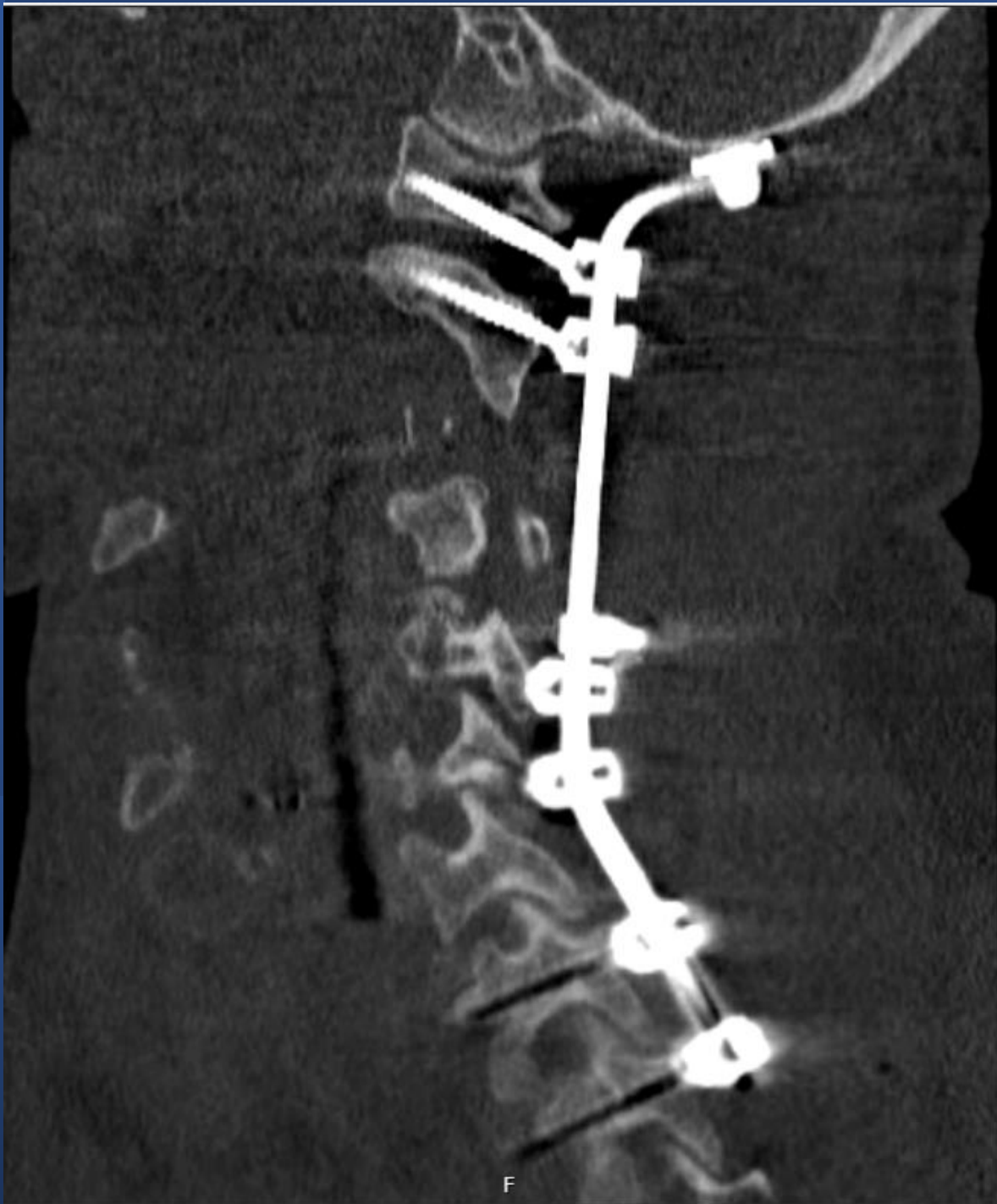- 45-year old arborist
- Heavily intoxicated
- Falling from a tree, 3-5 meters...
- Multiple fractures and SCI





"Nurse, get on the internet, go to SURGERY.COM, scroll down and click on the 'Are you totally lost?' icon."

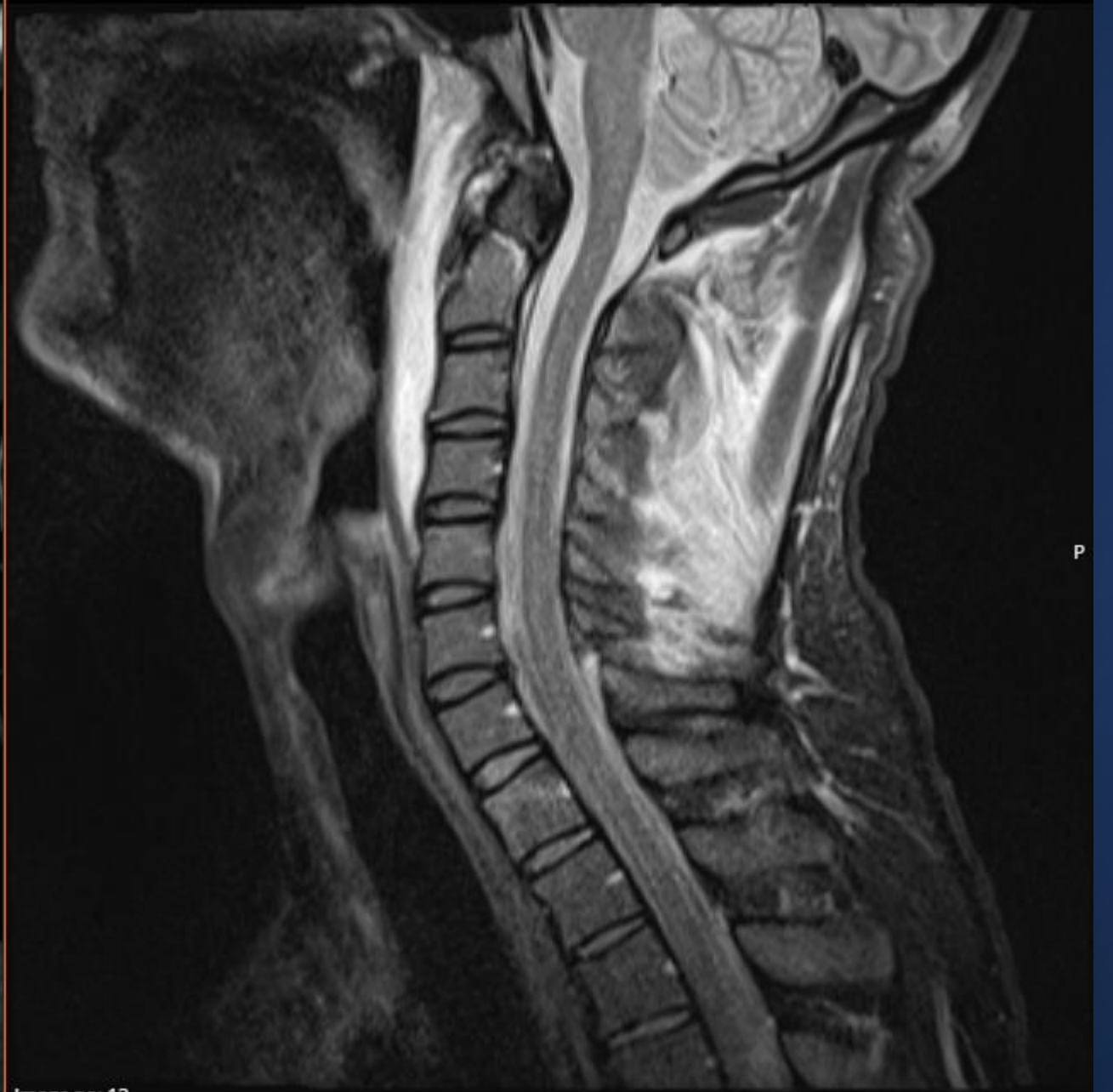
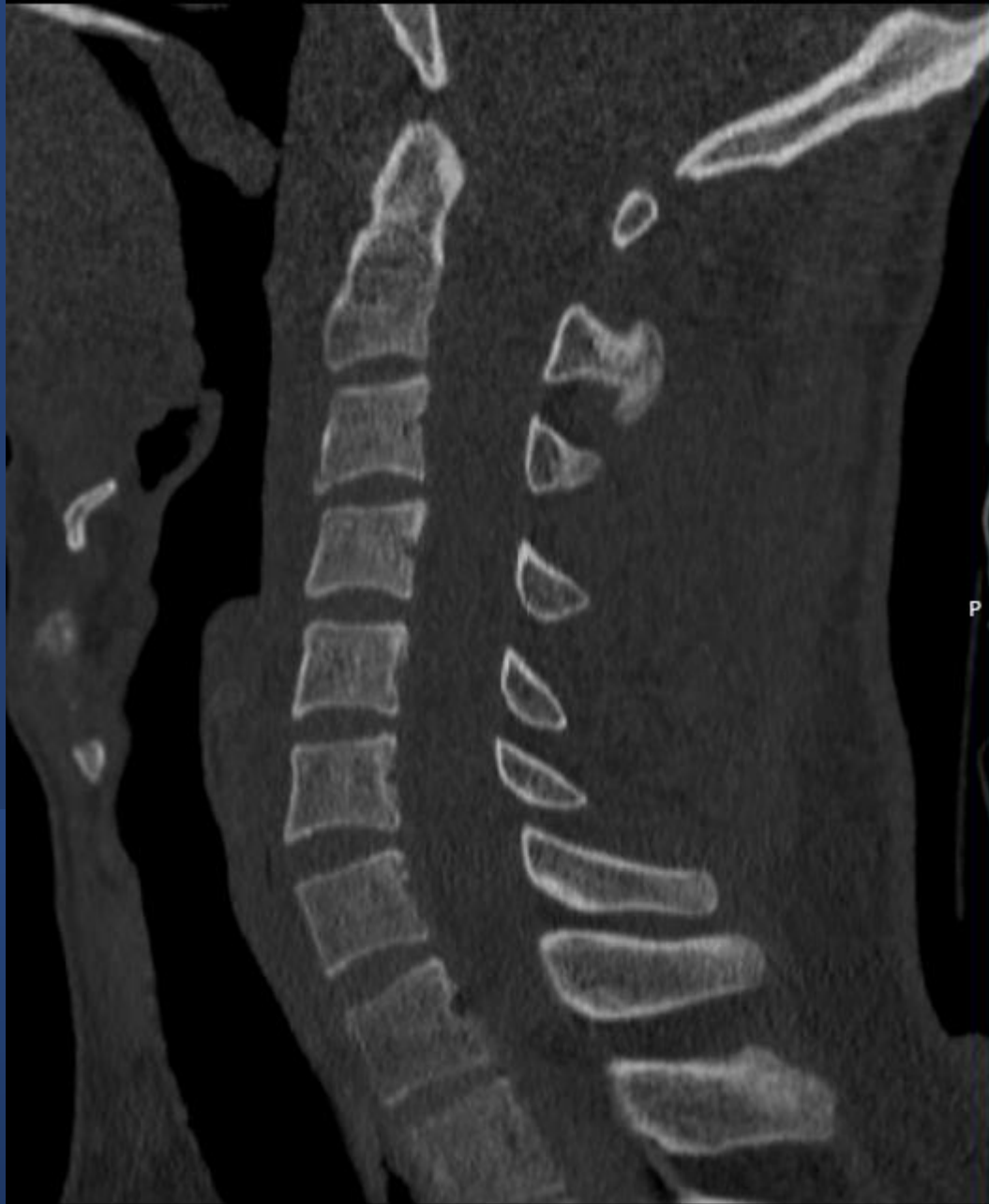


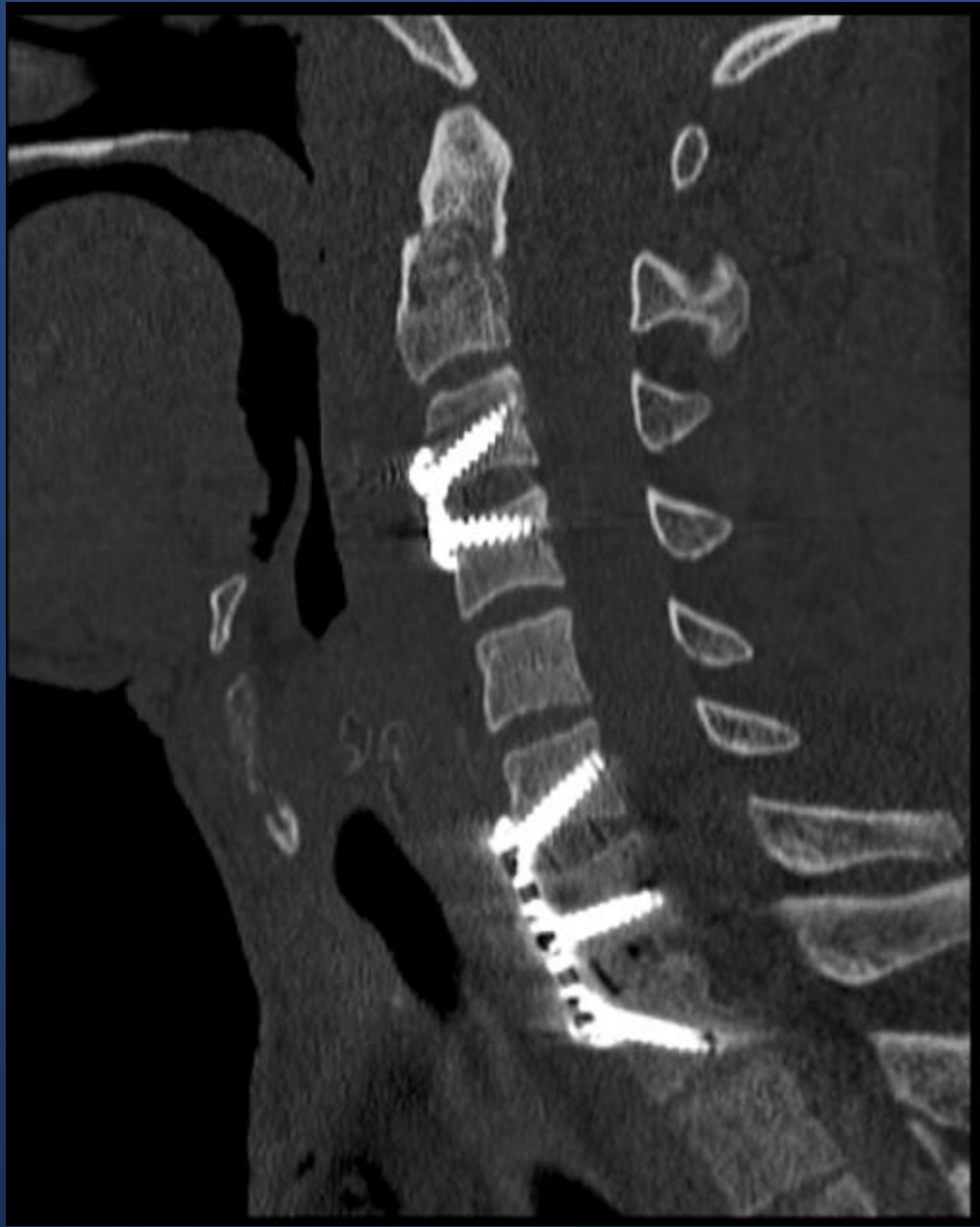Case 2

Biking is dangerous!

- 34-year old man
- Mountain bike accident
- He hit a stone with his head
- Wearing a helmet

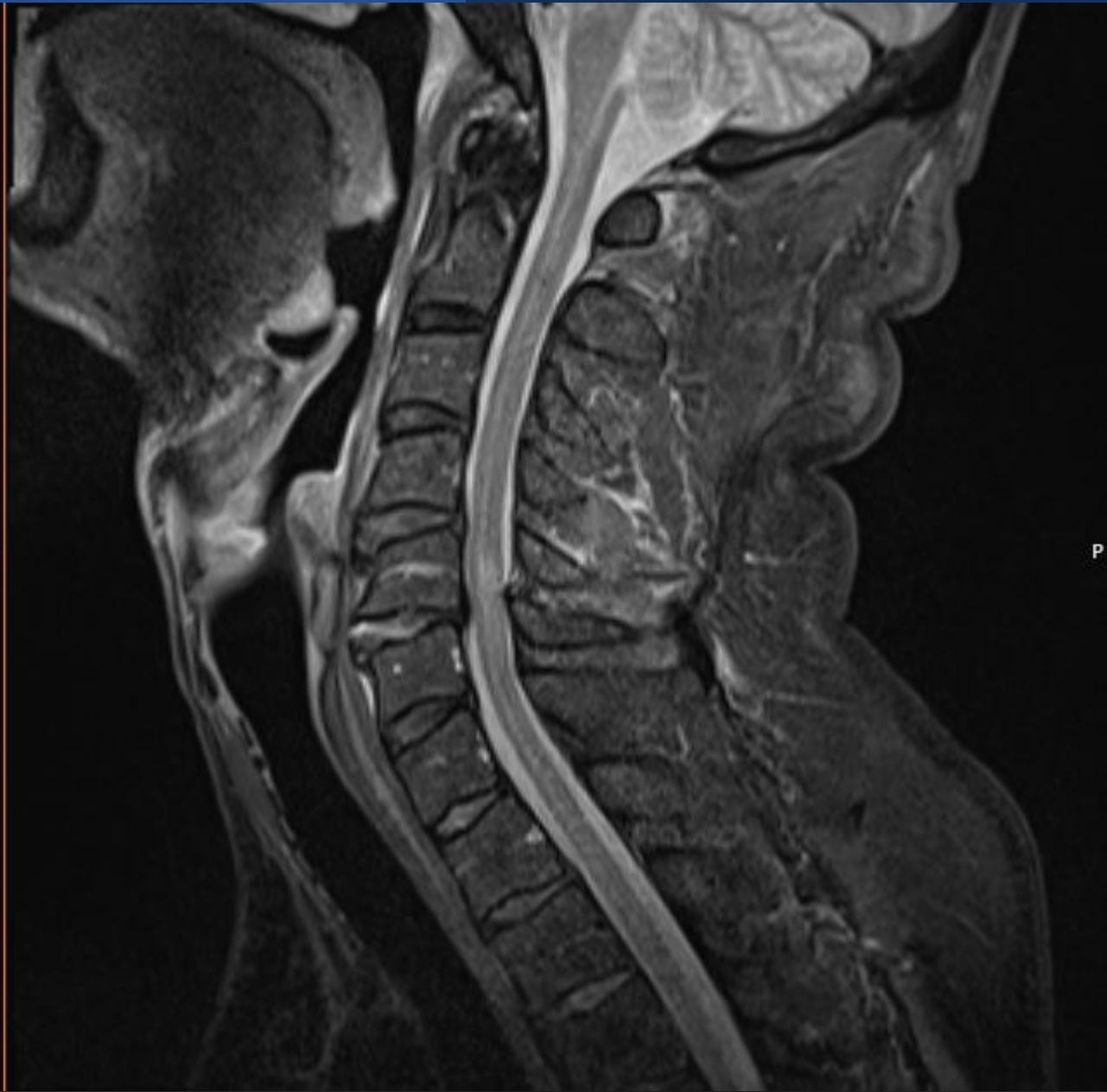
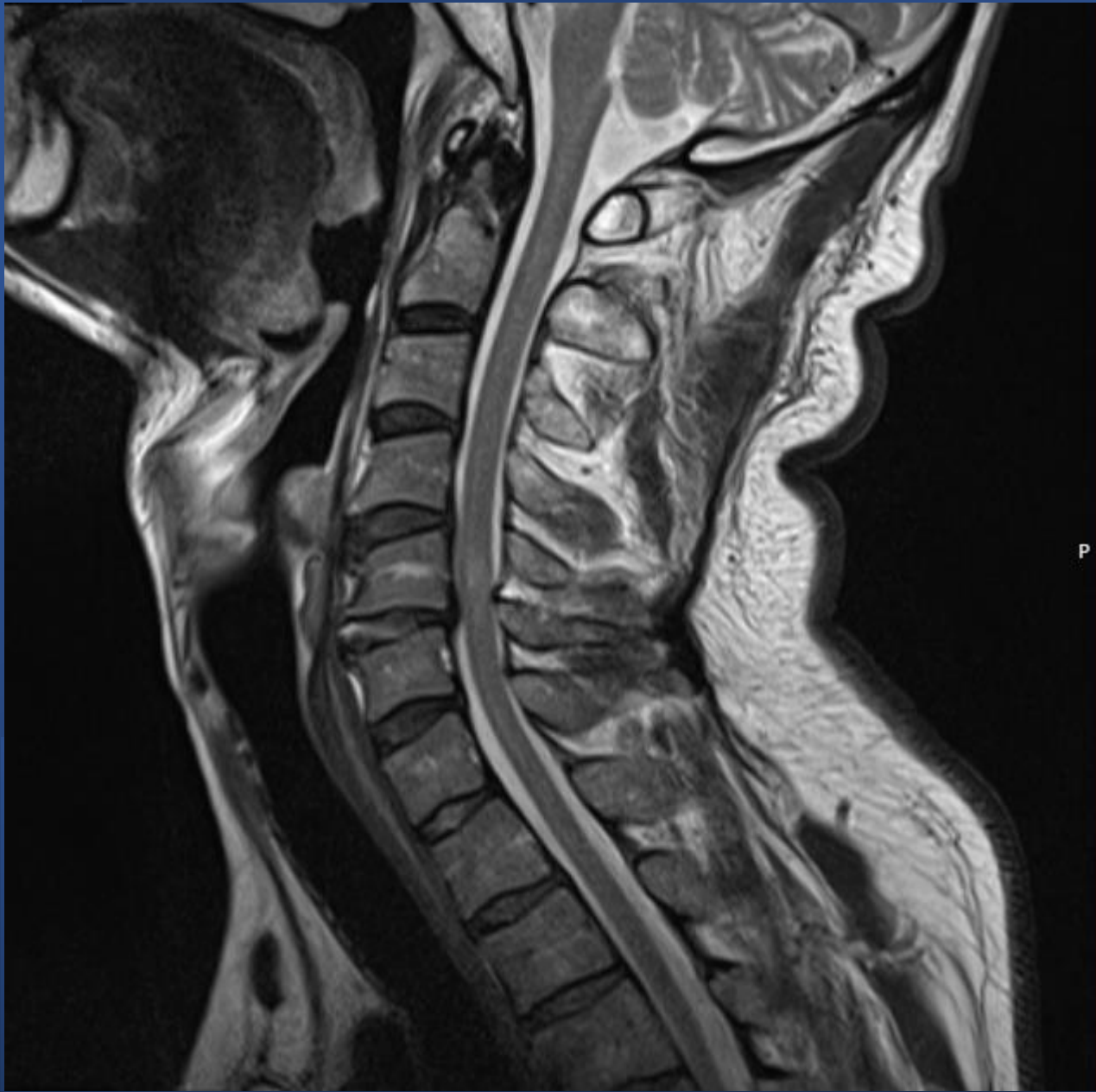


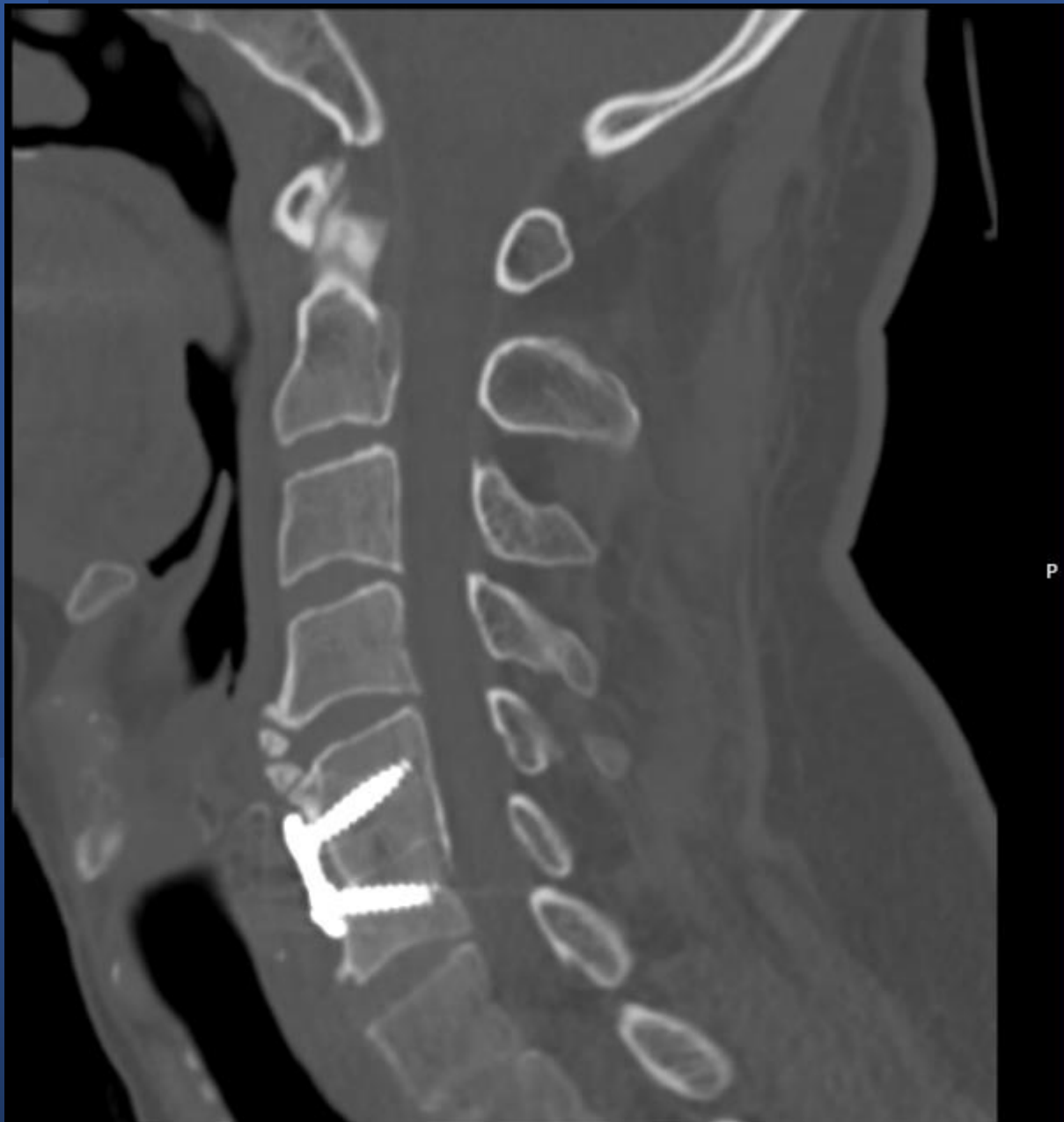
- Fractures to C1, C2, C3, C4, C6, C7, Th1
- Combination of surgery and collar-treatment
- Fully restored



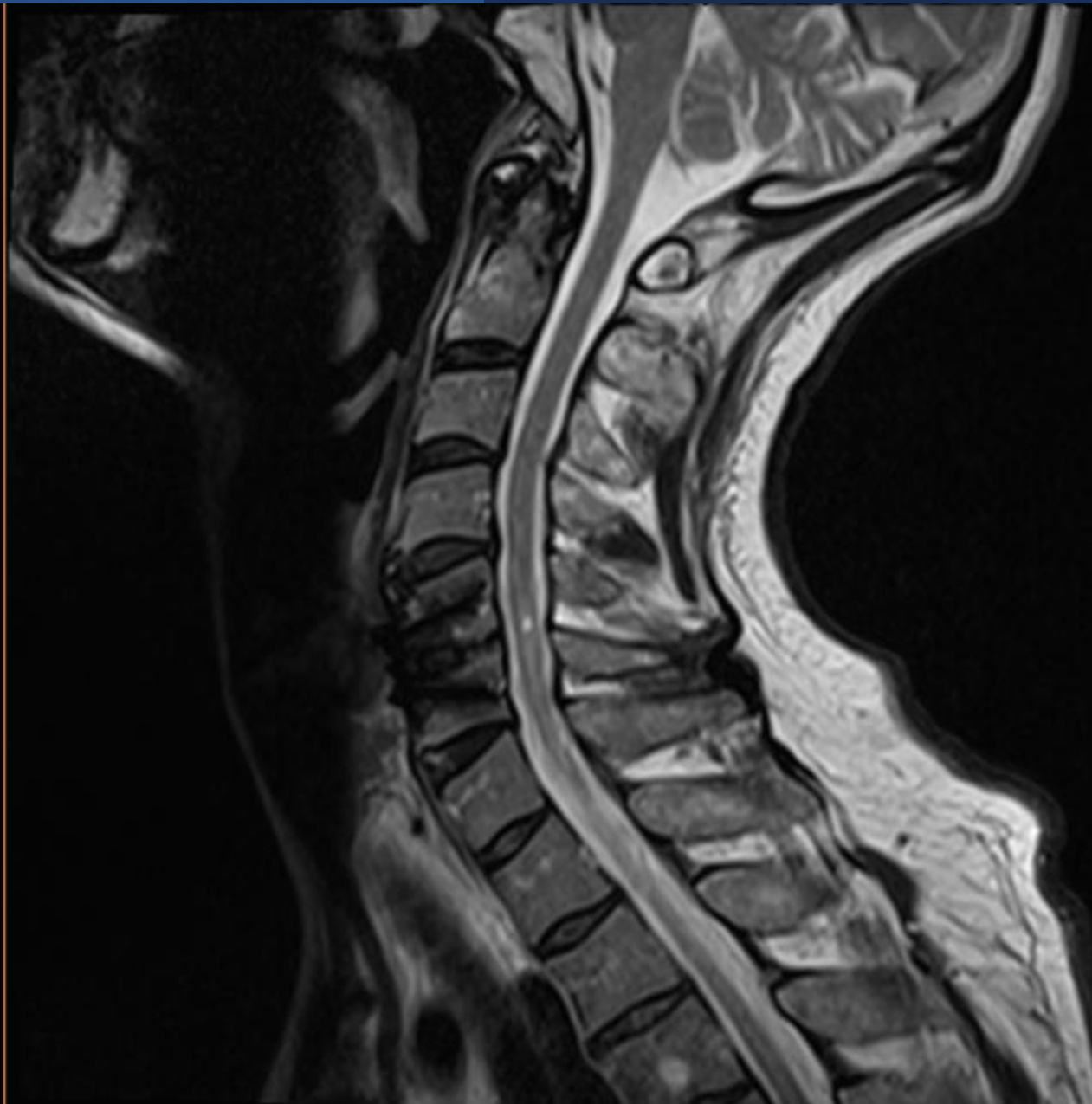
Case 3 Central Cord Syndrome!

- 52-year old man
- Biking accident
- Weakness of upper extremities
- Prior degeneration at C5-C6 level
- Traumatic injury at the same level





P

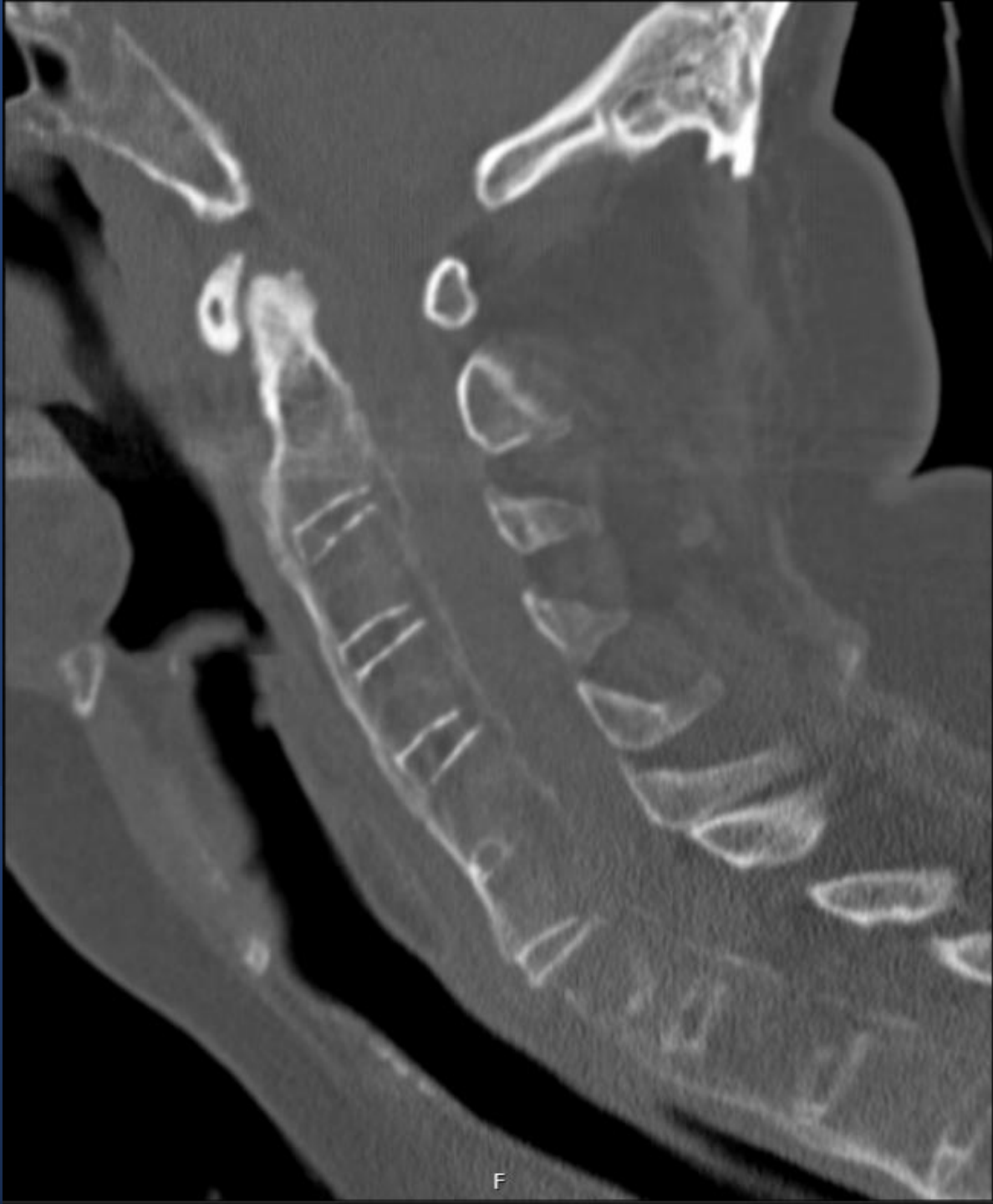

- Fully restored neurologically at discharge from rehabilitation 1 months after the surgery!

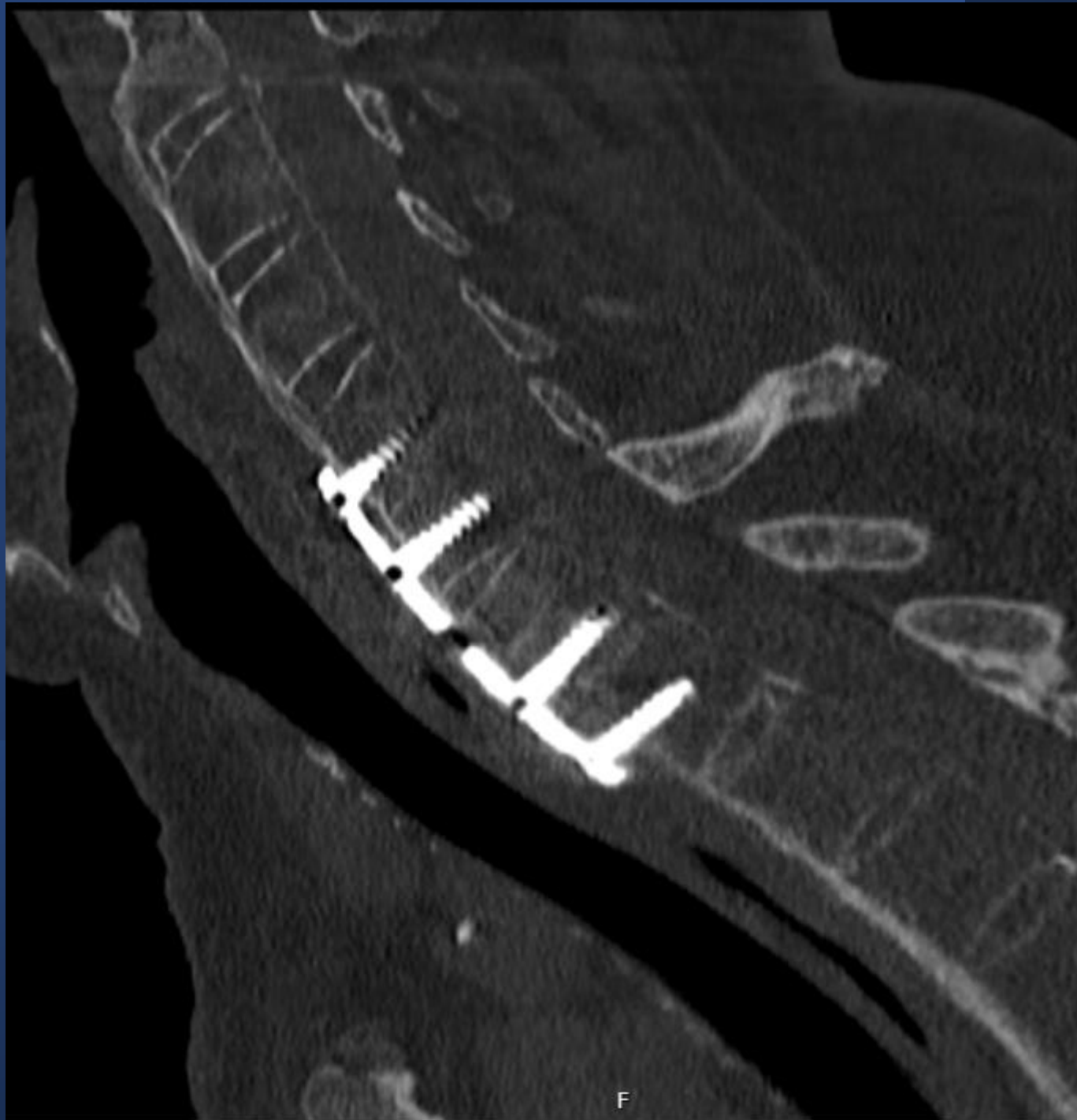Case 4

Ankylosing spondylitis

- 67-year old retired man
- Same-level fall
- Neck pain
- No neurological deficits

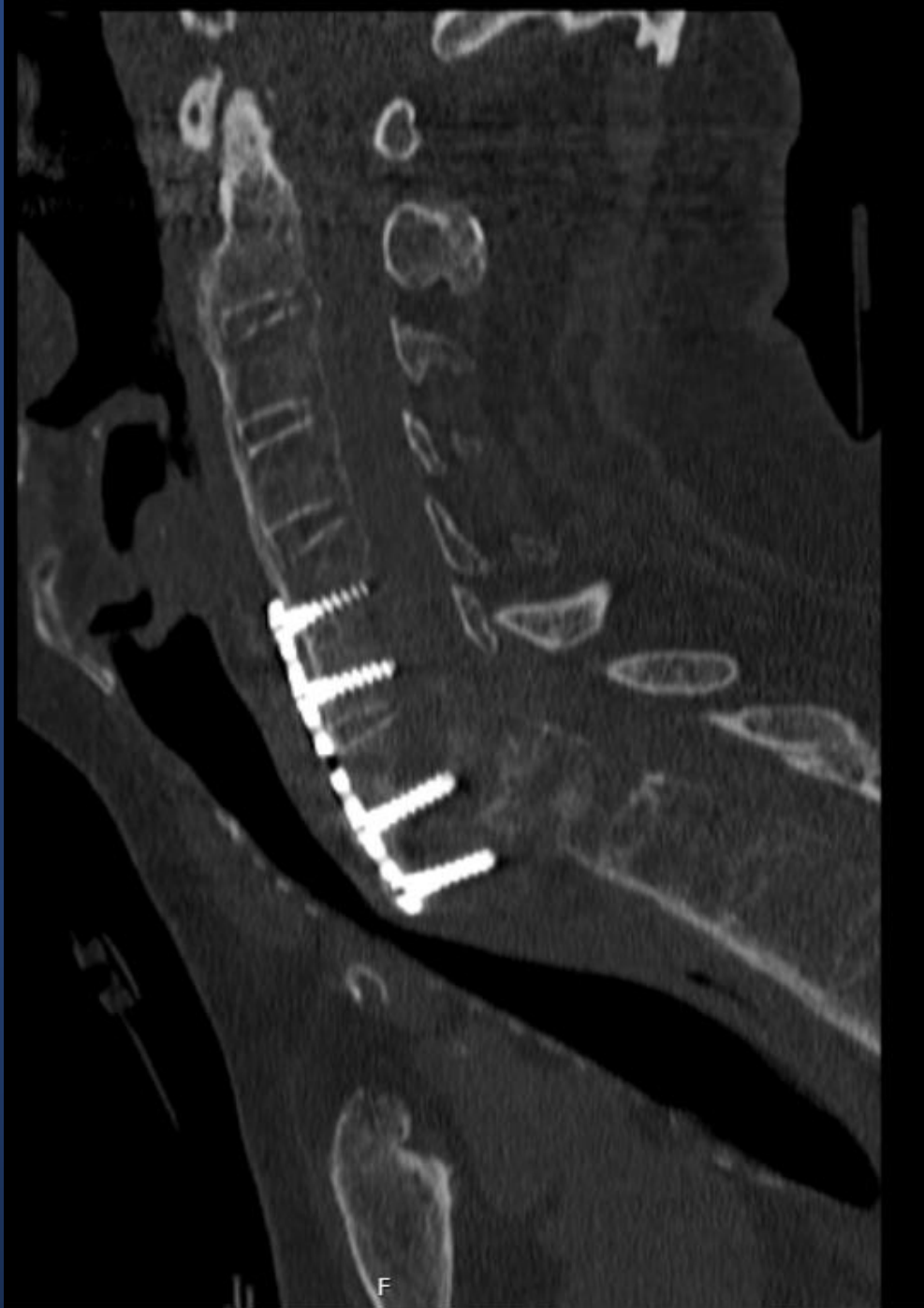

F

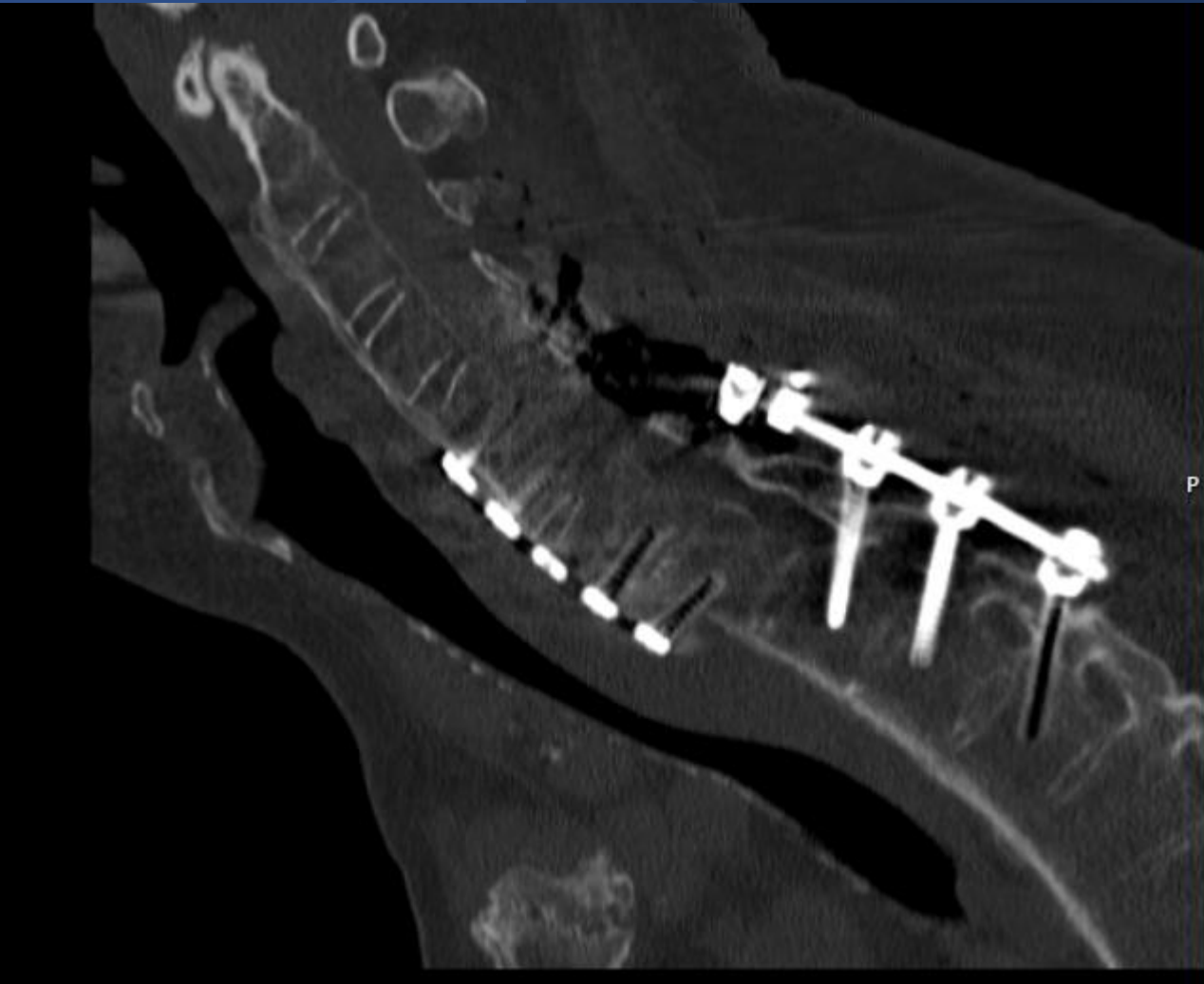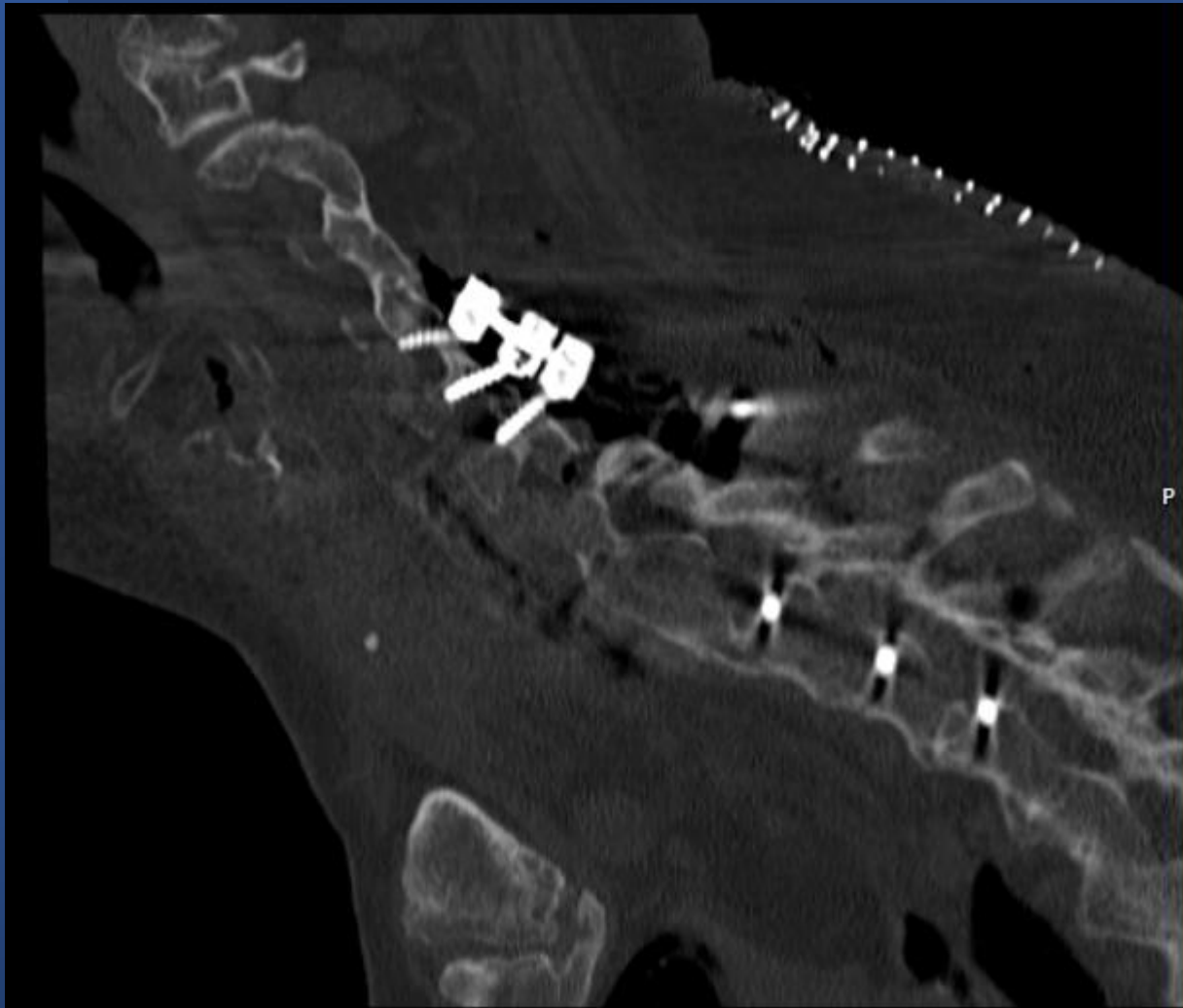


F

- Did well after surgery
- 1 week after surgery, sudden tetraplegia while lying in bed



F

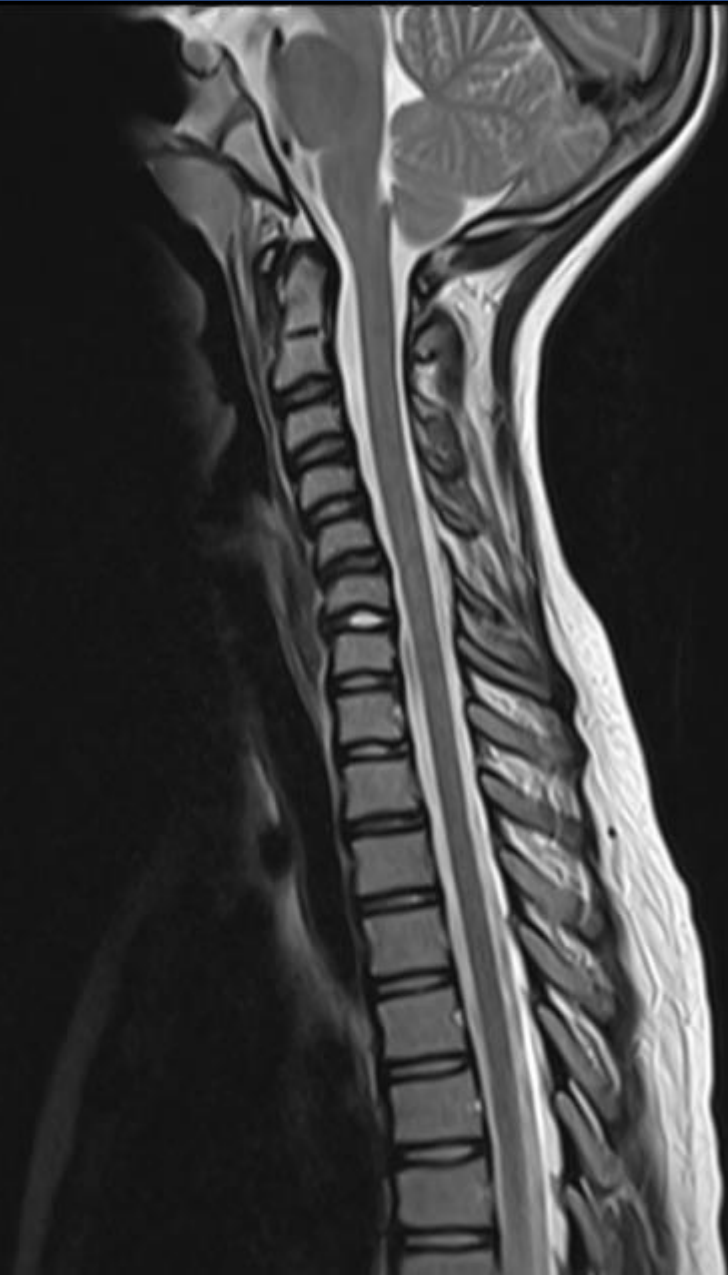

- Unfortunately, complete SCI
- Always consider anteroposterior surgery in AS

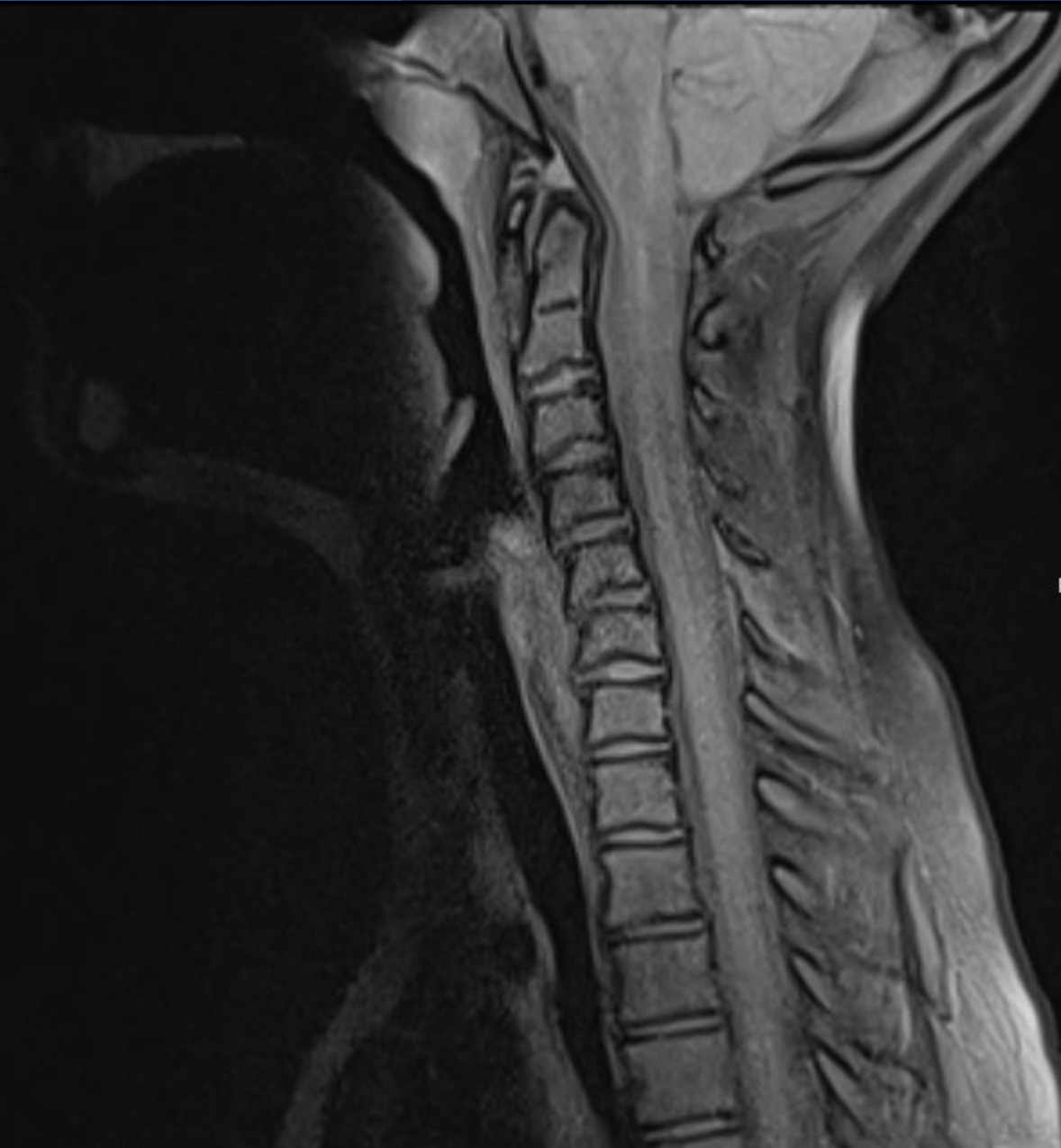
Case 5

Children and Cervical spine injury

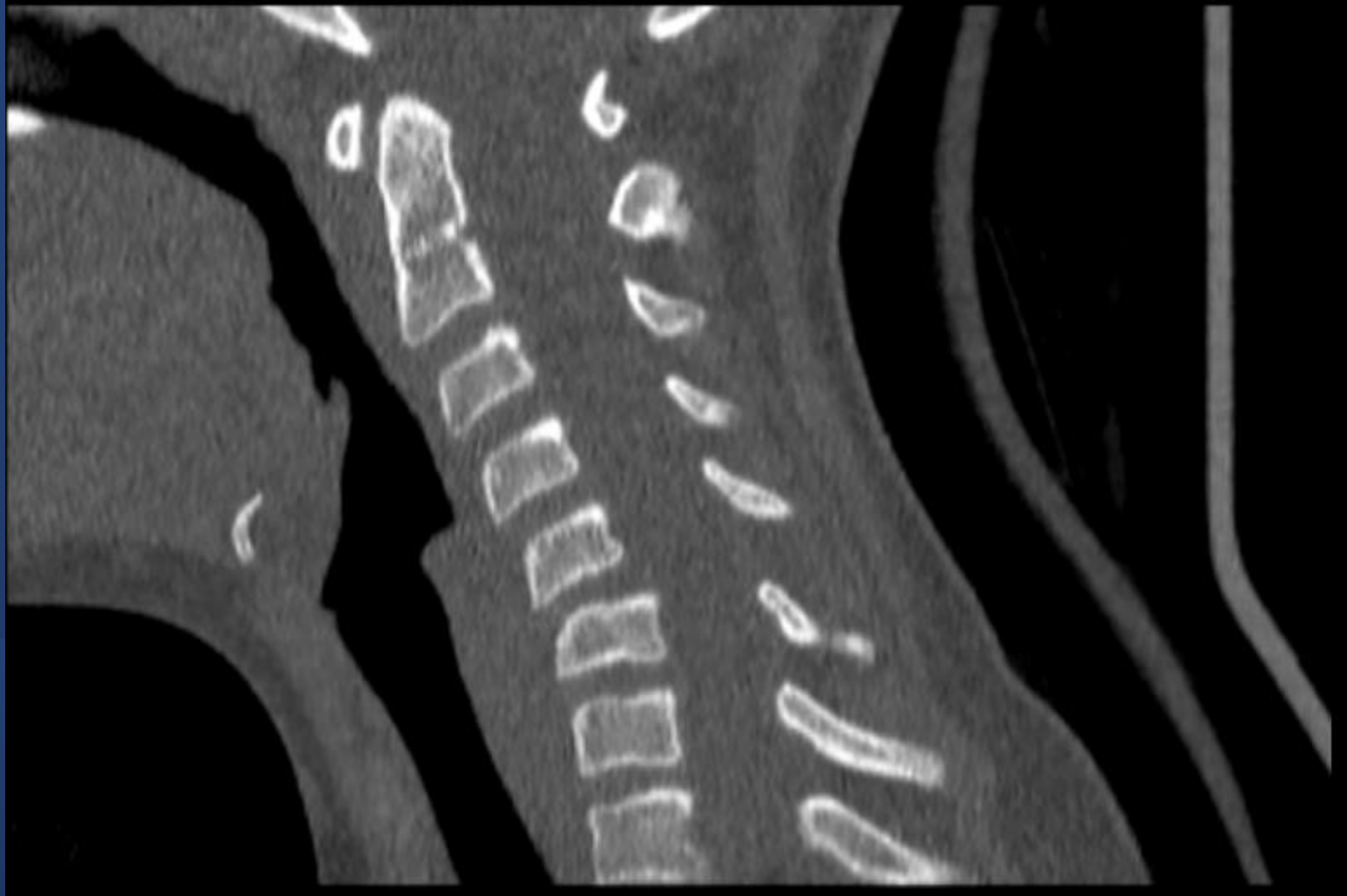- 12-year old girl
- During gymnastic over rotation and hyperflexion
- Injury to posterior elements and lig. flavum
- Initially treated with stiff collar
- Kyphosis after 1 months of treatment



P

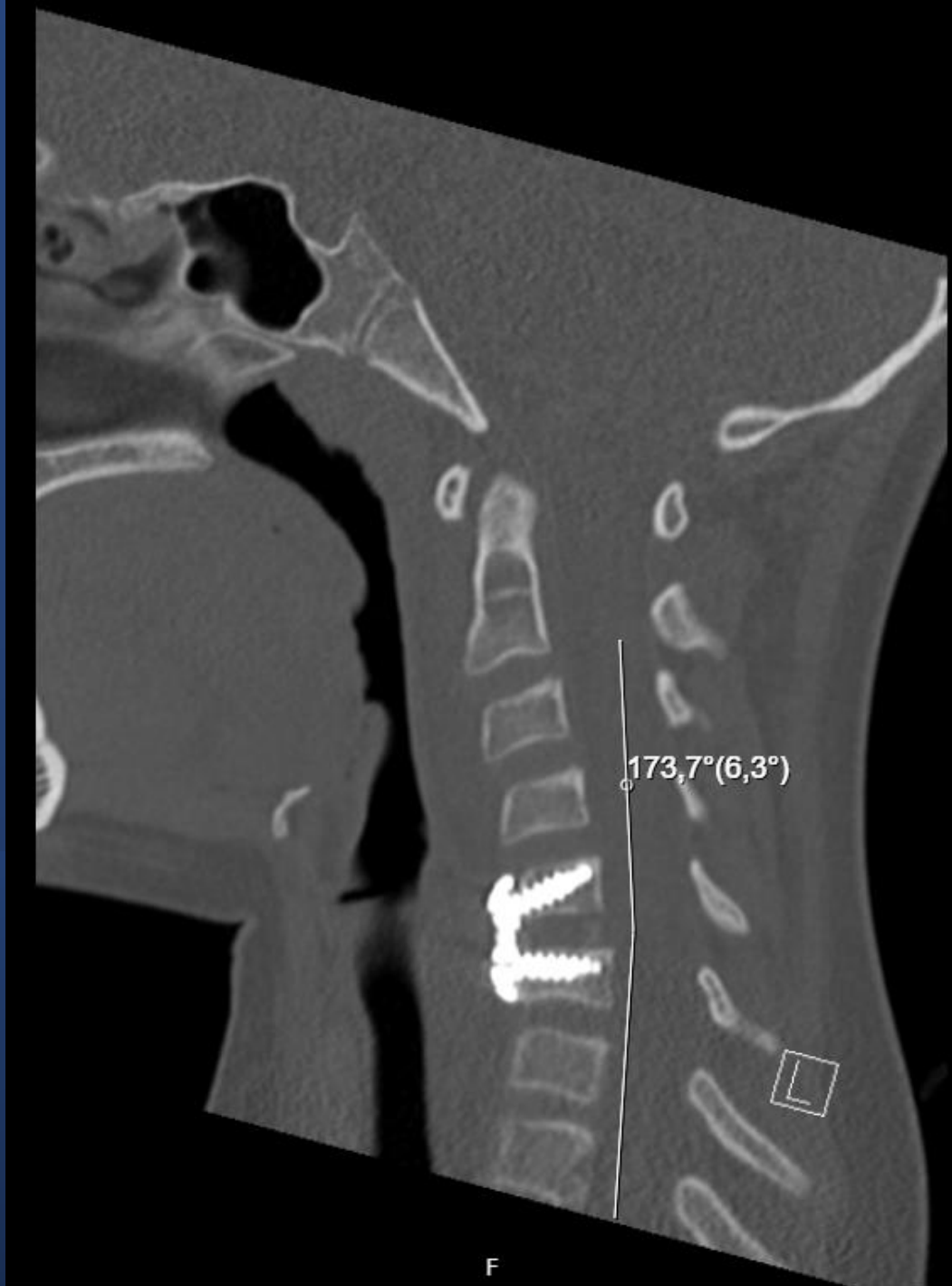

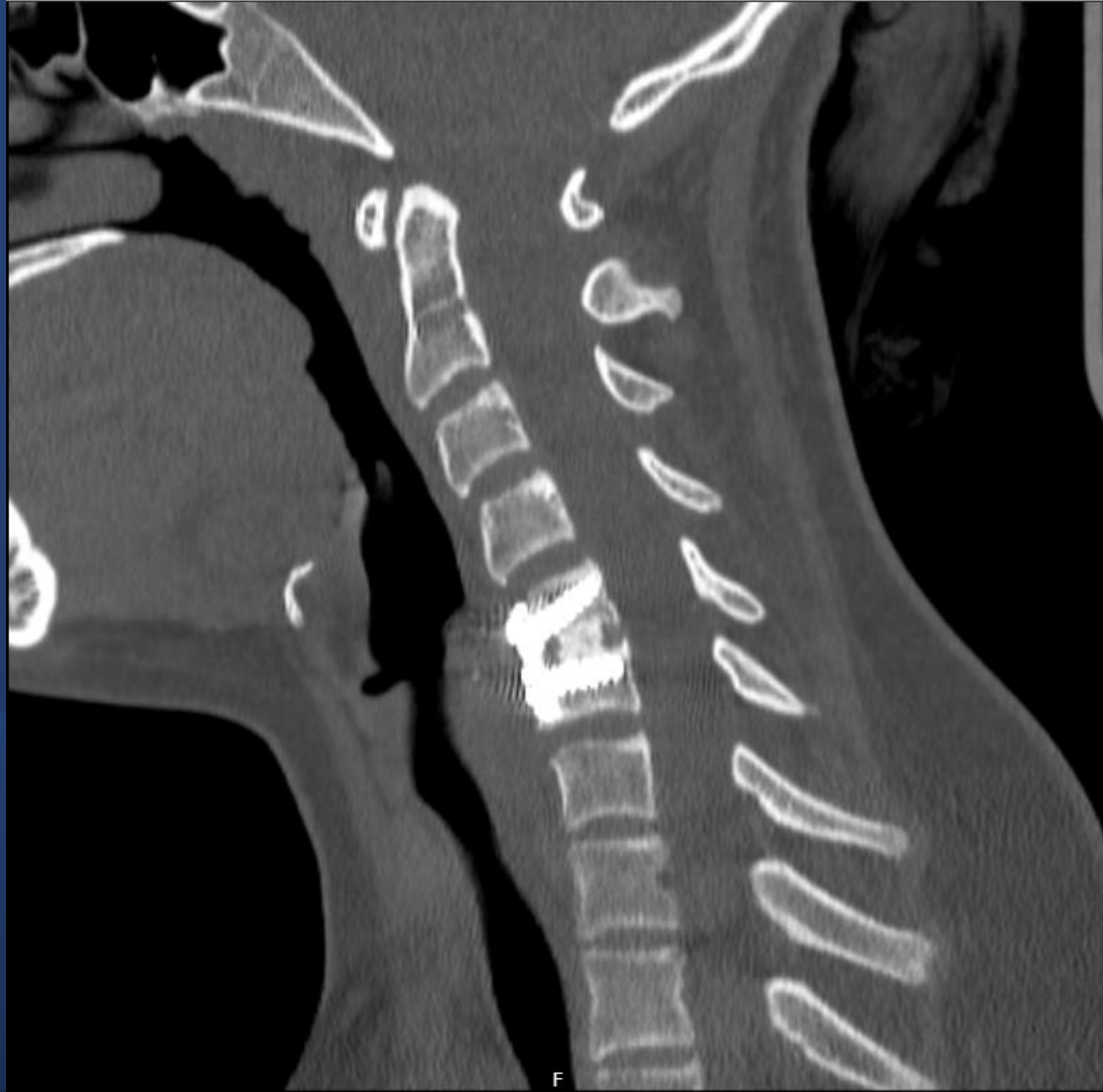P



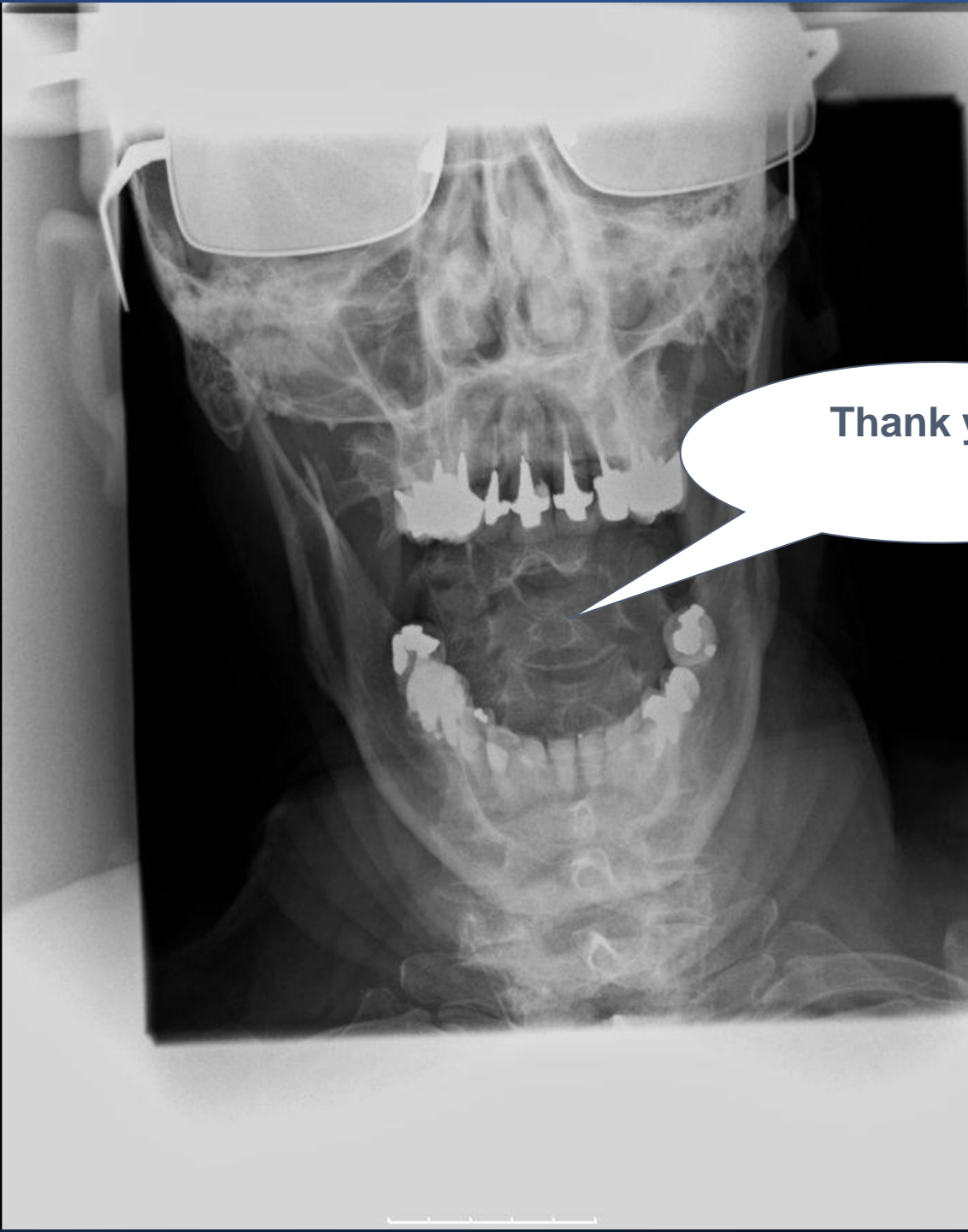


Operated 2 month
after the trauma





- At 5-year follow-up remaining kyphosis
- Neurologically no deficits



Thank you!



Thank you!

Presented by:
Adrian Elmi-Terander, MD, PhD
Associate professor of neurosurgery
Cario Spine Center Stockholm
Karolinska Institute, Stockholm, Sweden

adrian.elmi.terander@ki.se